Available online at www.sciencerepository.org

Science Repository

Case Report

Type IV hypersensitivity reaction following Cyanoacrylate Glue Embolization (VenaSeal™) of the Great Saphenous Vein incompetence: A case report

D. Chua[1], Yeo YW[2], Chong TT[1] and Tang TY[1]*

[1]*Department of Vascular Surgery, Singapore General Hospital, Singapore*

[2]*Department of Dermatology, Singapore General Hospital, Singapore*

ARTICLE INFO

Article history:

Received: 22 January, 2019

Accepted: 15 February, 2019

Published: 28 February, 2019

Keywords:

Phlebology

VenaSeal

Cyanoacrylate glue

Chronic venous insufficiency

ABSTRACT

Background: In recent years, cyanoacrylate glue embolization (CAE) (VenaSeal™, Medtronic, Santa Rosa, USA) has emerged as an effective and safe strategy in the management of chronic venous insufficiency and varicose veins. The most common complication is a self-limiting post-procedure phlebitis, which often resolves in a few days. In rare instances, the rash persists for weeks and is believed be attributed to a delayed hypersensitivity reaction to cyanoacrylate.

Method: We present a short report of a female patient who developed such a rash following CAE 3 weeks after VenaSeal™ treatment.

Result: The patient made a complete self-limiting recovery of her rash after 2 weeks following expectant management with non-steroidal anti-inflammatories (NSAID) and analgesia.

Conclusion: The VenaSeal™ red skin reaction should be suspected in patients developing a rash post-CAE. This may be related to a delayed hypersensitivity reaction to the acrylate component of the compound.

Introduction

In recent years, cyanoacrylate glue embolization (CAE) (VenaSeal™, Medtronic, Santa Rosa, USA) has emerged as an effective and safe strategy in the management of chronic venous insufficiency and varicose veins. The most common complication is a self-limiting post-procedure phlebitis, which often resolves in a few days. In rare instances, the rash persists for weeks and is believed be attributed to a delayed hypersensitivity reaction to cyanoacrylate. We present a case of a female patient who developed such a rash following CAE 3 weeks after VenaSeal™ treatment.

Case Presentation

A 53-year old Chinese female with no significant medical history of note was seen at our clinic with symptomatic varicose veins affecting her right leg. A duplex ultrasound of her venous system revealed right-sided above and below knee great saphenous vein (GSV) reflux for which she was subsequently counselled for VenaSeal™ ablation and multiple stab avulsions. She underwent an uneventful procedure and was discharged on the same day and prescribed a two-week course of Non-steroidal anti-inflammatory for pain control and to minimise the risk of phlebitis. As per surgeon's preference, she was reviewed in the specialist outpatient clinic ten days later. A check duplex scan showed that the GSV had been ablated successfully with no recurrence and the stab avulsion sites had healed without complication. There was no evidence of phlebitis. She was seen again in SOC three weeks later and was noted to have a new pronounced erythematous, non-tender, non-pruritic rash over her right medial thigh (Figure 1). A course of antibiotics and NSAIDS were again prescribed. She was subsequently referred to a dermatologist for evaluation. A patch test was subsequently performed using a remnant amount of VenaSeal™ adhesive (n-butyl-2-cyanoacrylate) on the left inner arm using a standard protocol and Chemotechnique Diagnostics (place) patch test chamber. Readings were performed after 48 and 96 hours and graded according to the International Contact Dermatitis Research Group (ICDRG) recommendations as a strong positive reaction (++), suggesting an allergic contact dermatitis to the adhesive (Figure 2). The patient was reviewed 2 weeks later, and the rash and

**Correspondence to TY Tang MD FRCS FAMS, Consultant Vascular & Endovascular Surgeon, Associate Professor Duke-NUS Medical School, Department of Vascular Surgery, Singapore General Hospital, Level 5, Academia, 20 College Road, Singapore 169856; E-mail: tang.tjun.yip@singhealth.com.sg*

http://dx.doi.org/10.31487/j.SCR.2019.01.009

symptoms had completely resolved (Figure 3). She was not commenced on steroids.

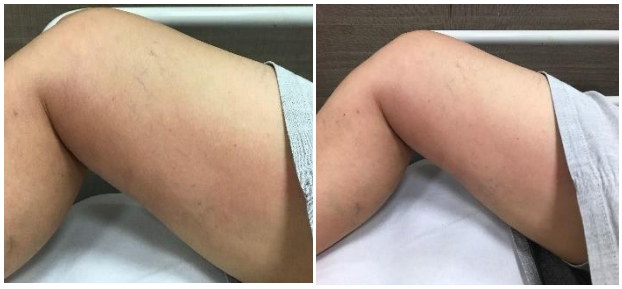

Figure 1: Erythematous rash following VenaSeal™ ablation of the right GSV over the medial thigh on post-operative day 21.

Figure 2: Patch results showing infiltrated papules and few vesicles suggesting of a strong positive reaction at 48 (A) hours and 96 hours (B) respectively.

Figure 3: Resolution of phlebitis over the right medial thigh (A) and patch test area (B) 5 weeks post-operatively

Discussion

Chronic venous insufficiency (CVI) is a progressive disorder characterized by lower limb venous hypertension, distinctive cutaneous changes, oedema and ulcers [1]. Superficial venous reflux is often present in patients with CVI and management is aimed at reducing venous hypertension via targeted ablation of the superficial venous system [2]. Over the past few decades numerous techniques have emerged in the armamentarium of managing CVI. Conventional open surgical treatment of GSV incompetence has largely been replaced by minimally invasive endovenous techniques such as thermal ablation (laser and radiofrequency (RFA). Recently, the use of non-thermal non-tumescent (NTNT) techniques have gained traction as an effective treatment modality to achieve superficial venous occlusion, which avoids the morbidity associated with open surgery and the risks of burns and nerve injury associated with a thermal-based modality [3-5]. The landmark VeClose trial was the first randomized study to demonstrate the feasibility of Cyanoacrylate embolization (CAE) (VenaSeal™, Medtronic) in the management of superficial venous reflux, with subsequent reports reporting similar efficacy and safety profiles to RFA [6-8]. The most common complication following CAE is self-limiting phlebitis, which happens in up to 20% of patients and responds well following a short course of NSAID medications [9]. In certain cases, patients may present with a rash that persist beyond the usual few days; it is believed that such a rash, also termed as a VenaSeal™ red skin reaction, may be related to a delayed hypersensitivity reaction to the acrylate component of the compound [8, 10]. This seems to have a predilection along the GSV course and in females [8]. Expectant management with NSAIDs and analgesia for such a condition is preferred and in certain refractory cases, treatment may involve a course of oral corticosteroids. A thorough history of known or suspected allergy to acrylate compounds should be obtained from the patients prior to procedure. Where necessary, a dermatologic consult is highly recommended for specialized allergic patch tests. Further clinical studies may be necessary to elucidate the exact course and progression of this cutaneous complication. This is the first case report to document any sort of patch testing in such patients but the only way to prove conclusively if those with a reaction at the glue site is truly allergic contact dermatitis (delayed hypersensitivity) is if those with the reaction are patch test positive and those without are patch test negative. The other point of interest would be to see if these patients are also sensitive to other acrylates of which patch test panels are commercially available as acrylates are in nail varnish and commercial glues. Furthermore, we are unsure whether the incidence of this complication is related to patient's body mass index or the total glue dose injected or the location of the GSV in relation to its usual enveloping fascia in the thigh although recent data that a double dosing of glue does not seem to increase the incidence of this phenomenon [11].

Conclusion

The VenaSeal™ red skin reaction should be suspected in patients developing a rash post-CAE. This may be related to a delayed hypersensitivity reaction to the acrylate component of the compound.

Competing Interests

None

Funding

None

Disclosures

The authors have no disclosures to make or conflicts of interest to declare

References

1. Nicolaides AN, Hussein MK, Szendro G, Christopoulos D, Vasdekis S, et al. (1993) The relation of venous ulceration with ambulatory venous pressure measurements. *J Vasc Surg* 17: 414-419. [Crossref]
2. O'Donnell TF Jr (2008) The present status of surgery of the superficial venous system in the management of venous ulcer and the evidence for the role of perforator interruption. *J Vasc Surg* 48: 1044-1052. [Crossref]
3. Winterborn RJ, Foy C, Earnshaw JJ (2004) Causes of varicose vein recurrence: late results of a randomized controlled trial of stripping the long saphenous vein. *J Vasc Surg* 40: 634-639. [Crossref]
4. Brittenden J, Cotton SC, Elders A, Ramsay CR, Norrie J, et al. (2014) A randomized trial comparing treatments for varicose veins. *N Engl J Med* 371: 1218-1227. [Crossref]
5. Rasmussen L, Lawaetz M, Serup J, Bjoern L, Vennits B, et al. (2013) Randomized clinical trial comparing endovenous laser ablation, radiofrequency ablation, foam sclerotherapy, and surgical stripping for great saphenous varicose veins with 3-year follow-up. *J Vasc Surg Venous Lymphat Disord* 1: 349-356. [Crossref]
6. Morrison N, Gibson K, Vasquez M, Weiss R, Cher D, et al. (2017) VeClose trial 12-month outcomes of cyanoacrylate closure versus

radiofrequency ablation for incompetent great saphenous veins. *J Vasc Surg Venous Lymphat Disord* 5: 321-330. [Crossref]

7. Morrison N, Gibson K, McEnroe S, Goldman M, King T, et al. (2015) Randomized trial comparing cyanoacrylate embolization and radiofrequency ablation for incompetent great saphenous veins (VeClose). *J Vasc Surg* 61: 985-994. [Crossref]
8. Park I (2017) Initial Outcomes of Cyanoacrylate Closure, VenaSeal System, for the Treatment of the Incompetent Great and Small Saphenous Veins. *Vasc Endovascular Surg* 51: 545-549. [Crossref]
9. Lam YL, De Maeseneer M, Lawson J, De Borst GJ, Boersma D (2017) Expert review on the VenaSeal(R) system for endovenous cyano-acrylate adhesive ablation of incompetent saphenous trunks in patients with varicose veins. *Expert Rev Med Devices* 14: 755-762. [Crossref]
10. Tang TY, Alok T (2018) The VenaSeal™ Abnormal Red Skin Reaction: Looks like but is not Phlebitis! *Eur J Endovasc Surg* 55: 841. [Crossref]
11. Tiwari A, Chong TT, Wang JCC, Choke ETC, Tang TY (2018) Regarding "Double prepuncture as a valuable adjunctive technique for complex endovenous ablation". *J Vasc Surg Venous Lymphat Disord* 6: 420. [Crossref]