Available online at www.sciencerepository.org

Science Repository

Research Article

Dobutamine stress echocardiography in the exploration of the pathophysiology of takotsubo syndrome

John E. Madias*

Icahn School of Medicine at Mount Sinai, New York, NY, and the Division of Cardiology, Elmhurst Hospital Center, Elmhurst, NY

ARTICLE INFO

Article history:
Received 10 January, 2019
Accepted 15 February, 2019
Published 5 March, 2019

Keywords*:*
Takotsubo syndrome
pathophysiology of takotsubo syndrome
DSE
DSE and takotsubo syndrome
DSE in the exploration of takotsubo syndrome.

ABSTRACT

The pathophysiology underlying takotsubo syndrome (TTS) remains elusive. TTS is triggered by emotional/physical stresses, administered catecholamines/sympathomimetics, and during dobutamine (DB) stress echocardiogram (ECHO) testing (DSE). DSE induces dynamic left ventricular outflow tract obstruction (LVOTO) and mid-cavitary obstruction (MCO), particularly in postmenopausal women with chest pain and normal coronaries. Some patients suffer TTS, or quasi/atypical TTS, with the vast majority recovering shortly after DSE, although troponins and serial ECHO with/without strain/strain rate ECHO have not been employed to evaluate whether a few of such patients have not developed a forme fruste TTS. This piece proposes that retrospective/prospective scrutiny of ECHOs may provide valuable insights about the pathophysiology of TTS. For cases of DSE-triggered TTS, the regional hyperdynamic myocardial responses (RHMR) to DB, *which preceded* the regional myocardial contraction abnormalities (RMCAs), LVOTO, MCO and mitral regurgitation (MR) of TTS, should be evaluated. The temporal relationship of RHMR to DB and LVOTO/ MCO/MR, in patients who did/did not suffer TTS should be studied. Evaluation of RHMR to DB in patients with normal DSE may also be contributory. Additionally, patients with positive DSE due to coronary artery disease with an associated TTS-like component (mixed phenotypes) should be scrutinized. ECHOs should be correlated with symptoms during DSE, dose of DB, age, gender, history of hypertension and chest pain, blood pressure and heart rate changes during testing, presence of septal hypertrophy and sigmoid septum in the baseline ECHO, response of chest pain and RHMR and other ECHO abnormalities to β-blockers, follow-up morbidity, and recurrence of TTS.

"the search of truth always must trump hubris, bias, complacency, and the fear of new knowledge."

Lee Goldman

Pathophysiology insights of enigmatic diseases [e.g., takotsubo syndrome (TTS)] should be sought in every conceivable source (i.e., symptom/sign/comorbidity/laboratory test) that appear(s) to provide even an inkling that a cause and effect association may be at work.

**Correspondence to: John E. Madias, MD, Division of Cardiology, Elmhurst Hospital Center, 79-01 Broadway, Elmhurst, NY 11373; Tel: (718) 334-5005; Fax: (718) 334-5990; E-mail: madiasj@nychhc.org*

http://dx.doi.org/10.31487/j.JICOA.2019.01.005

Dobutamine stress echocardiography and pathophysiology of TTS

The pathophysiology of TTS is still elusive, in-spite of efforts focusing on its elucidation [2]. Among many pathomechanisms proposed, stimulation of β_2-adrenoceptors, with a shift from Gs- to Gi-based signal transduction, resulting in cardiodepressant/cardioprotective effects on the myocardium, histologic evidence of transient alterations of β-adrenoceptors in the development of TTS, an inflammatory change modulated by nitrosative stress with many pathogenetic and therapeutic implications, and an enhanced β_1-adrenergic signaling and higher sensitivity to catecholamine (CATS)-induced toxicity, with genetic pathophysiological connotations for TTS, have been identified [3-7]. Considerable evidence supports the notion that autonomic sympathetic hyperstimulation and/or CATS excess is/are pivotal to the emergence of TTS [2-5, 7-10]. Indeed, not only TTS has been associated with pathological CATS excess (i.e. pheochromocytoma and paraganglioma), but TTS with various ballooning patterns can be precipitated by intravenous administration of CATS and β-adrenergic receptor agonists, as was observed in a study of 9 cases (7 women) of TTS precipitated by the intavenous administration of EPI (n = 6) or dobutamine (DB) (n = 3), a sympathomimetic drug used in the treatment of heart failure (HF) and cardiogenic shock via its positive inotropic action, whose primary mechanism is a direct stimulation of β_1 adrenergic receptors [11-13]. The 3 patients who developed TTS in the setting of a DB stress echocardiography (ECHO) testing (DSE) were a 46-year old man, a 51-year old woman, and a 41-year old woman, after receiving standard doses of DB (30 to 40 μg/kg/min), with one developing apical and the other 2 mid-ventricular ballooning [13]. More patients have been reported developing TTS in the setting of DSE, corroborating earlier reports [14-23]. Unbridled stimulation of adrenergic β-receptors by endogenous/exogenous CATS and synthetic β-adrenergic receptor agonists must be instrumental in the emergence of the regional myocardial contraction abnormalities (RMCAs) observed in TTS, and in this respect the topographic density of such adrenoceptors and their sensitivity to CATS must be important. The apical myocardium has a greater density of β-adrenergic receptors and thus an increased response to sympathetic stimulation compared to the base, as shown in canine experiments, and this has been employed to explain the frequent apical ballooning in human TTS, although such a β-adrenergic receptor base/apex gradient has not been demonstrated in humans [13, 24]. Greater sympathetic nerve density of the human cardiac base than the apex has been shown, compensated by larger β-adrenergic receptor density in the apex than the base [24, 25]. Thus, although the autonomic neural input to the human heart has been "incompletely characterized, it is likely that the different ballooning patterns seen with TTS must result from a complex interplay between sympathetic innervation, β-receptor density and function, and CATS sensitivity" [13]. The sympathetic innervation is more abundant in the anterior than in the inferior left ventricle (LV) in humans, leading to a higher predilection of the anterior wall to develop RMCAs during TTS [25]. Also, transient weakening of autonomic input to the heart via the vagal nerves, competing with the juxtapositioned adrenergic nerves, may predispose to TTS [25]. Although this may be the case at the onset of TTS, parasympathetic contribution may change later on; parasympathetic predominance is felt to be occasionally present in the subacute phase of TTS [8]. There is no difference in the distribution of adrenergic nerves between the right ventricle (RV) and LV in the human heart, and this may explain the frequent involvement of the RV in TTS, which probably is underappreciated, due to less scrutiny directed to the RV in routine ECHO [2, 25]. The influence of age in altering the central and regional balance of adrenergic and vagal function, the density of the adrenergic and vagal receptors, and the sensitivity of the former to CATS, must influence the higher predisposition of the elderly to TTS. Although high CATS have been found early in the clinical course of TTS, "extremely high CATS levels have not been reproduced in other studies [10, 26]. However even low doses of CATS, e.g., clinically recommended EPI, and DB administered for testing, have led to TTS, prompting some to propose that it is not the CATS primarily causing TTS, but that they rather act as a trigger factor for the sympathetic system to cause TTS [9, 26]. Since only a minority of patients receiving clinically indicated epinephrine or DB for DSE suffer TTS, there must be a genetic predisposition (variability in myocardial adrenergic signaling or other signal transduction processes) influencing susceptibility to TTS" [2, 9, 13]. The different RMCAs encountered in TTS probably result from the varying autonomic neural input to the heart and β-receptor density and function, and CATS sensitivity, to even routinely used in clinical practice, drug doses [13]. Perhaps a way to distinguish the role of circulating CATS (*which need to be routinely measured*) and the autonomic sympathetic input to the heart in patients with TTS, is to start monitoring the latter; available technology of recording via the electrocardiogram (ECG) electrodes can be used, to monitor the thoracic skin nerve activity, a surrogate of the sympathetic stellate ganglia nerve activity, for patients with TTS, or subjects potentially predisposed to it, based on acquisition/analysis of electrical 500 -1000 Hz signals [27]. The strong female preponderance (~90%) of TTS suggests a probable modifying role of sex hormones on the cardiac response to the adrenergic stimulation from emotional and physical stressors [28].

DSE-triggered TTS and the pathophysiology of TTS

Animal experimentation focusing on the pathophysiology of TTS is based on the administration of CATS and synthetic β-adrenergic receptor agonists, although other "upstream" methods have been employed [3, 29-32]. The intriguing finding that different CATS induce different TTS RMCAs, and their apparent afterload-dependent manner, begs for further exploration of this "angle" in the pathophysiology of TTS. CATS or synthetic β-adrenergic receptor agonists are administered to humans for the management of HF and anaphylactic emergencies, during anesthesia, perioperatively, or periprocedurally [33, 34]. In all these situations, evaluating the infrequent emerging TTS with ECHO in close temporal proximity to the drug administration is impractical, since the emphasis in these emergencies is on the management of the often-life-threatening clinical problem. In contrast, administration of DB for DSE, with its obligate frequent ECHO, ECG, heart rate (HR), and blood pressure (BP) monitoring, provide the appropriate platform to evaluate the effect of DB on the heart function, in patients with normal and abnormal DSE, and rare TTS [13-23]. DB is a direct-acting synthetic CATS and is the drug of choice for the noninvasive assessment of coronary artery disease (CAD). Standards of performing the DSE, and quantitative evaluation of the heart's function employing conventional ECHO, and strain ECHO, have been published [35, 36]. Also, insights on the LV twist mechanics in normal physiology and cardiovascular disease in studies using strain ECHO have emerged [37]. 2D and 3D strain ECHO has been employed in normal volunteers, various clinical

conditions, including patients with old and acute myocardial infarction (AMI), patients undergoing DSE, and patients with TTS [38-40]. Also strain ECHO has been used in the quantification of DSE [41]. Importantly, there has been a dissociation reported in the recovery of LV as assessed by conventional ECHO and strain ECHO, with the former showing normalization of the LV ejection fraction (LVEF), while the latter reveals abnormal deformation, suggesting hypocontractility, in HF, and TTS [42, 43].

There are some parallels between TTS and manifestations emerging during DSE performance. LV outflow tract obstruction (LVOTO) occurs in ~20% of patients with TTS, who tend to be older and have history of hypertension, small LV, sigmoid bulging septum or midventricular septal thickening, show systolic anterior motion (SAM) of the anterior mitral valve leaflet, associated with a higher grade of mitral regurgitation (MR), and require fluid resuscitation, cessation of inotropic therapy, and intravenous β-blocker in their management [44, 45]. Nevertheless, it is still unclear whether the LVOTO is a consequence or a cause of TTS, since the LVOTO does not occur in all patients with TTS [45]. Similarly, LVOTO occurs in up to 20% of patients undergoing DSE, with LV mid-cavitary obstruction (MCO) occurring less commonly [20, 46-48]. Also, LV RMCAs during DSE may occur in-spite of normal coronaries due to hypertension response or TTS, and it is conceivable that these dynamic LVOTO and LV MCO represent a potential mechanism of an induced apical ballooning of TTS by DSE [17]. Patients with TTS due to DSE had history of hypertension, LV hypertrophy (LVH) by ECG, apical ballooning without MCO, LV MCO, LVOTO, SAM and MR [13-20]. It has been postulated that TTS can arise due to the hyperdynamic basal segments creating an intra-cavity gradient caused by excessive release of CATS, occasionally in the setting of dehydration, particularly in elderly women, resulting in an isolated apical chamber that produces myocardial stunning without infarction, although even herein it is not clear whether the LVOTO or MCO is the cause or consequence of TTS [14-16, 49, 50].

ECHO manifestations in patients undergoing DSE

Compelling findings from previously vast published information provide the impetus to explore the triangle of TTS in general/DB-triggered TTS/ECHO dynamic transient manifestations in patients undergoing DSE, in an effort to elucidate the pathophysiology of TTS. In consecutive 4 women aged 74-,72-, 71-, and 75-year old, who had previously suffered TTS associated with dynamic MCO and with underlying localized mid-ventricular septal thickening, low dose DB (20mcg/kg/min) after recovery from TTS, on days 20, 20, 20, and 14, respectively, induced LV mid-cavity gradient and regional deformation changes suggestive of regional stunning, as assessed by strain ECHO. Indeed, here we see reproduction of the a TTS-like state in predisposed patients who had previously suffered TTS, and have recovered. The authors emphasized the functional septal thickening superimposed on mid-basal anatomic thickening, dehydration, and elevated CATS, from exertion or anxiety, as factors conspiring to trigger TTS, via high pressure and wall stress in the apical chamber, leading to myocardial stunning due to subendocardial ischemia, with recovery after rehydration and fall of CATS levels [49]. Elderly women are more predisposed to develop such MCO due to their frequent abnormal basal/mid-septal thickening (sigmoid septum) of unknown etiology, during DSE, with dehydration, and during weaning from cardiopulmonary bypass [44, 49, 51, 52]. Not all patients with DBE-induced MCO develop TTS; this perhaps is related to a milder degree of such obstruction, or to the absence of a significant rise of CATS [49]. This suggests that CATS should be measured in patients with DBS-induced TTS, or in patients who come close to develop TTS [49]. Also, others have described LVOTO and MCO with DSE [53, 54]. Development of such MCO with DSE did not predict development of TTS at follow-up, but it is conceivable that longer follow-up (> mean 31 months of this study), and presence of the other inducing concurrent factors, could have led to TTS [49, 53, 53]. However, it should not be overlooked that patients with a negative assessment for CAD, or patients without such DSE-induced changes as the above, had future chest pain, syncope, and near-syncope [54]. Also, of interest is that although it has been discussed that MCO is less frequent than LVOTO in the setting of DSE, the opposite was seen in this study, where 22.8% had MCO, and 12.2% had LVOTO [54, 55].

What has been described in this study, and exemplifies what has been shown by others, is that LVOTO, and MCO is frequent in patients undergoing DSE, and that such patients are prone to chronic chest pain and syncope [54-57]. Both development of MCO and chest pain have been prevented by β-blockers [55, 56]. In some patients the MCO is due or associated with SAM [57]. Indeed, RMCAs in association with a hypertensive response to exercise have been precipitated by exercise ECHO in some patients without CAD, with some developing transient apical and mid-ventricular or mid-ventricular and basal RMCAs, reminiscent of the ones of TTS [58, 59]. Of interest, the RMCAs were not reproduced at subsequent DSE, perhaps suggesting different effects of innate CATS and DB, or the effect of hypertension present only during exercise ECHO [58]. This hypersympathetic state, has been attributed to CATS excess, inherent to exercise stress testing, and has been associated with chest pain during exercise. Of note is that cardiac biomarkers and CATS were not measured in these patients, but the authors hinted that changes noted in their patients could have amounted to a TTS-like phenotype [58]. A larger study found new or worsening RMCAs with exercise ECHO and excessive rise in BP during exercise, in patients without significant CAD [59]. The authors also alluded to previous work revealing that healthy young adults can develop abnormal ventricular contractility by performing sudden vigorous exercise [60]. Also dynamic LVOTO has been observed in middle-aged hypertensive women with history of chest pain, who presented with hypotension and mild troponin release in a critical care setting, for which they received inotropic agents, including digoxin, dopamine, and DB; these patients were shown to have SAM, and an ejection systolic murmur with late peaking was noted most often in the left third intercostal space, and responded to fluid infusion and β-blockers [61]. The authors underscored the inducing influence of hypovolemia, small ventricular volumes, and many factors leading to them, increased contractility, promotion of the Venturi effect, and prevention and management of this rather underappreciated condition [61]. The association of both hypertension and hypotension in states with manifest myocardial hypercontractility, LVOTO, MCO, SAM, MR, and RMCAs in patients, parallels the hemodynamic changes noted in TTS animal models [33, 34]. While hypotension in patients undergoing DSE is attributed by some to the associated LVOTO, others feel that hypotension is due to the vasodilating effect of DB [46, 48]. Indeed, some advocate administering a bolus of 250-500 ml of normal saline in selected patients who manifest intracavitary obstruction during DSE to counteract the associated, with the hyperdynamic function, hypotenion [46]. The boundary between all

the above dynamic changes, induced by hypercontractility and definite human TTS, is often very fuzzy, and has prompted some to wonder whether some similar to the above cases of patients with a strongly *false positive* exercise ECHO or DSE, mainly in the absence of a hypertensive response to stress, 84% of whom were postmenopausal women, probably represent a forme fruste variety of TTS [62]. These 31 patients showed apical and mid-ventricular RMCAs,[62] similar to ECHO changes seen in elderly patients with TTS, in contrast to younger patients with TTS who usually have a predilection for reverse TTS [63]. However even in this study, there was no information about troponin release data, so that the diagnosis of TTS could be confirmed, except in one of the 31 patients who was admitted to the hospital following a DSE, and revealed persistent RMWAs 2 hours after the DSE, since the study was based on a retrospective analysis [62]. Also, this study did not include information based on detailed regional ECHO assessment, employing conventional and strain ECHO analyses of hyperdynamic changes possibly preceding the emergence of RMWAs [62]. This author favors this speculation; one wonders whether animal models of TTS could explore the role of LVOTO or MCO in the elicitation of the TTS phenotype [62]. Indeed, such models could additionally explore whether LVOTO or MCO precede or follow the emergence of TTS, since ~20% of patients with DSE show such changes, something still remaining unresolved heretofore [50]. The majority of patients with transient ECHO changes do not developed TTS in the setting of stress ECHO or DSE, and do not have history of prior TTS; however, DSE-triggered LVOTO has led to AMI in a 70-year-old woman [64]. The chronicity of chest pain in patients with pseudopositive DSE reminds one the alleged persisting chest pain in patients who have previously suffered TTS.

One wonders about qualitative or quantitative similarities or differences between the ECHO findings of patients with dynamic LVOTO, MCO, and RMCAs undergoing exercise ECHO or DSE, and the ones who have suffered a DSE-triggered TTS [13-22, 46-49, 54-59]. In the case of exercise ECHO the rise of endogenous CATS or the intense stimulation of the autonomic sympathetic nervous system may be at play. In the case of DSE leading to transient ECHO changes or TTS, a direct effect of the infused DB must be the culprit. Such a notion is supported by limited experience with DSE-triggered TTS in a patient with an orthotopic transplanted heart, 1-year post-transplantation, who had initially at peak DSE stress hypercontractility and a rise of her LVEF from 60% to 70%, with subsequent drop to 30%, and associated RMCAs, at 7 minutes into the recovery phase [23]. A transplanted denervated heart with absent inhibitory parasympathetic innervations, is presumably expected to manifest an exaggerated response to CATS, and thus be more susceptible to a large non-physiologic dose of exogenous DB administered in a short period of time during DSE [23]. Another interesting finding is that from a group of 69 patients with LVOTO in the setting of DSE,[48] 15 patients underwent stress ECHO, and none developed significant LV outflow gradient, probably suggesting that norepinephrine (associated with exercise ECHO) and DB (associated with DSE) preferentially stimulate β_1-adrenergic receptors in different cardiac regions. This experience parallels previous animal work on TTS in which 5 different CATS and sympathomimetic drugs led to TTS with different RMCAs, with the TTS-like cardiac dysfunction also revealing an apparently afterload-dependent manner (both low and high BP) [33]. This also brings to mind the association of LVOTO and MCO in patients undergoing DSE and revealing either low BP or hypertension [48]. This suggests that other factors than mere stimulation of a particular adrenoreceptor subtype, in different myocardial territories, with an interplay of changing preload and afterload, and resulting ventriculo-arterial coupling, conspire to produce the ECHO phenotypes seen in DSE-triggered TTS and ECHO changes (without TTS) during DSE. One should envision that such "alterations in systemic hemodynamics may cause redistribution of regional LV wall stress, which in turn may mechanically overload certain regions within the LV" [33, 34].

Accordingly, an important attempt to explain the pathophysiology of TTS, the occasional case of DSE-triggered TTS, and the dynamic RMCAs seen in the course of DSE, has emanated from the work of some investigators,[49,65-68] who have proposed, based on strain ECHO data (Figure 1), that there is no evidence of segmental variation in contractility in the above conditions, and that the differentiation of RWMAs in the cardiac base, midventricular wall, and apex (as assessed by conventional ECHO and contrast ventriculography) is due to regional wall stress response, as determined by the increased midventricular/basal and apical/basal diameter ratio, and the decreased corresponding thickness ratio, as per Laplace's stress equation [69]. Thus, the above have highlighted the importance of strain ECHO and its advantages in differentiating between active and passive movement of ventricular wall segments and detecting deformation (i.e. contraction) in a visually akinetic wall segment, plus to evaluate components of myocardial contractile function, such as global longitudinal myocardial shortening, that cannot be visually assessed by conventional ECHO. This implies that the hypokinesis/akinesis in TTS may be different from the one encountered in myocardial ischemia/AMI. Also, others have stated that the RWMAs in TTS may be due to a "cramp-like state, emphasizing the "passive" response of the midventricular and apical myocardium to the CATS-induced augmented myocardial stress [70]. Indeed, this conceptualization may underlie the response of midventricular/apical myocardium in patients with history of hypertension undergoing DSE, during a pheochromocytoma crisis, or stress ECHO [71-73].

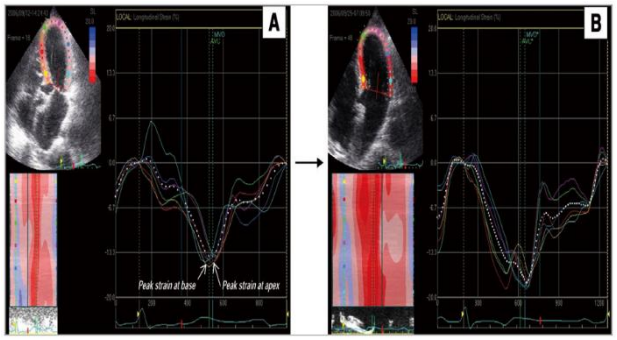

75-year-old woman with 2 episodes of syncope, which were preceded by chest pain, and triggered by emotional stress; she received epinephrine, DB, and noepinephrine for circulatory support, and after resuscitation the IABP was inserted for cardiogenic shock; coronary angiography excluded ACS; she was eventually diagnosed as a case of TTS, and while conventional ECHO revealed RWMAs, classic apical ballooning. SAM, and LVOTO, the 2D strain ECHO revealed uniformly normal contractility of all myocardial segments

Figure 1: Longitudinal regional wall deformation analysis in 6 LV wall segments (apical 4-chamber views). For each segment the time course of longitudinal strain is represented by a distinctively colored curve. The dotted white curve depicts the longitudinal global strain. Systolic longitudinal strain values (%) were lower during severe LV dysfunction

(A) than after recovery (B) but there were no regional differences in peak strain values. Reproduced with permission from Fig. 2 of Ref. #65.

DSE data scrutiny for exploring the pathophysiology of TTS

The pathophysiology of TTS is probably multifactorial, and thus different mechanisms are at play, leading to a limited number of phenotypes ; enlightenment in one/few of such mechanism(s) may serve as the springboard to unravel the pathophysiology of TTS [50]. Thus, it behooves important to ascertain whether in patients undergoing DSE there are any underlying such suggestive hints about the pathophysiology of TTS, regarding DSE-induced TTS, or TTS in general. Accordingly, the massive body of ECHO data (normal DSEs, and published cases of patients with DSE-triggered TTS) can be scrutinized, retrospectively/prospectively [13-23, 46-48, 52, 54-59]. Observing the "natural course" of TTS by scrutinizing the ECHO changes in response to various doses of DB prior to the emergence of DSE-triggered TTS, may prove enlightening [13, 23].

Evaluation of DSE data from patients with DSE-triggered TTS

One could focus on the documentation of the topography of RHMR preceding the emergence of RMCAs (Figure 2), diagnosed as TTS, their evolution and precipitation by given doses of DB, and the associated BP and HR changes. The published cases of DSE-triggered TTS do not provide any insights about such RHMR, but they only report ECHO data from baseline, and subsequent ECHOs, after the diagnosis of TTS had been made[13-23]. Important information may be forthcoming by a systematic analysis of the RHMR preceding the emergence of the TTS phenotype, with or without LVOTO, or MCO (Figure 3). Important may be cases of patients who developed a "near miss" atypical TTS in the context of DSE, their ECHO findings, and their clinical course following DSE [62]. Both conventional and strain ECHO, depicting each stage (baseline, low-dose, increasing doses, peak, and recovery) at end-systolic, end-diastolic, and in between, frames, should be analyzed. Evaluation should include segmental ECHO assessment prior to the development of LVOTO, MCO, SAM, MR, and RMCAs and subsequent temporal course of all the above, in connection with BP, HR, gender, age, menopausal status, symptoms, signs, complications, measurements of troponins, brain natriuretic peptide (BNP) or NT pro-protein BNP (NP-proBNP, angiographic, and cardiac magnetic resonance imaging (cMRI) and findings [35, 36, 40, 41]. Of particular attention should be the occurrence of RHMR, in relationship to age, gender, menopausal state, as a basis for inference about regional autonomic sympathetic innervations, and density, and sensitivity, of β-adrenergic receptors [13, 24, 25, 63]. It will be important to scrutinize in cases of DSE-triggered TTS: 1) whether there were RHMR noted in territories with subsequent LVOTO, or MCO; 2) whether such areas shifted around, as has been shown in animal experiments, and what was their association with BP and HR changes; 3) whether there were areas of RHMR followed by RMCAs, and what was their course until the stabilization of the ECHO DSE-triggered TTS; and 4) whether LVOTO, MCO, SAM, and MR preceded or followed the emergence of hypocontractile / akinetic / dyskinetic RMCAs [33, 34]. The later will provide answers to the "chicken and the egg" dilemma of TTS in general, and DSE-triggered TTS in particular [50]. Differences of all the above should be evaluated in young/elderly patients/subjects, considering alleged topographic differences in ventricular autonomic sympathetic innervations and β-adrenergic density and sensitivity as a function of age [13, 24, 25, 63].

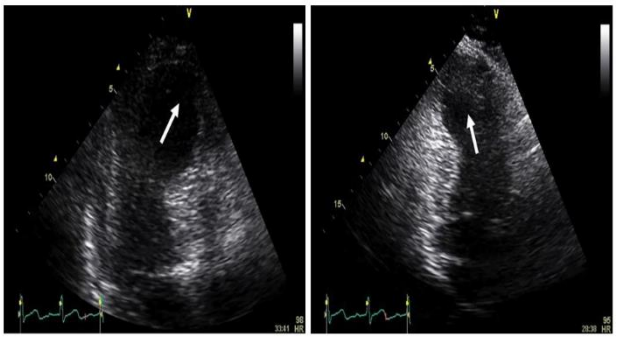

61-year-old woman with history of hypertension and 40-pack-year smoking habit underwent DSE for assessment of exertional shortness of breath**.**

Figure 2: Apical 4-chamber view (left panel) and apical 2-chamber view (right panel) at peak DB infusion at end-systole (the arrows point to the large apical ballooning); coronary angiography was normal and a mid-left anterior descending coronary artery segment of bridging was noted; repeat ECHO at 72 h showed near-normal LV function with mild residual apical and anteroseptal hypokinesis; reproduced with permission from Figs. 5 and 6 of Ref. #14.

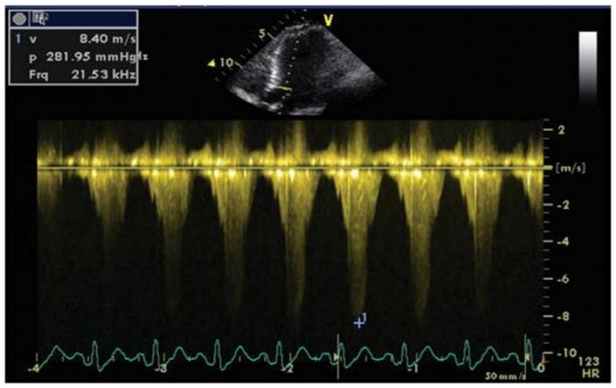

51-year-old woman with history of hypertension, hypercholesterolemia, and ~120 pack-year cigarette smoking, underwent DSE to evaluate intermittent chest pain of several months' duration

Figure 3: Continuous wave Doppler from a modified apical 5-chamber view at peak DB stress demonstrating late peaking dynamic LVOTO and MR contamination, with maximum velocity of 8.4 m/s and peak gradient of 282 mmHg; At cardiac catheterization all the above had resolved, and coronary angiography showed a 55% stenosis of the mid-left anterior descending coronary artery with a fractional flow reserve of 0.80; reproduced with permission from Fig. 1 of Ref. #20.

Performance evaluation of low dose DSE in patients with prior TTS

In accordance with previous experience, assessment of response of patients with previous DSE-triggered TTS could be implemented, using low dose of DB, 3 weeks after the index TTS [49]. A comparison of ECHOs from the DSE-triggered TTS, and the changes noted during low dose DSE, should be scrutinized. Important would be to evaluate whether the RHMR preceding the DSE-triggered TTS were similar to

the ones, noted during the low dose DSE, their temporal course, and their association with BP and HR changes, in patients with a negative low dose DSE, and in the few with a "near miss" TTS [49, 62]. These apply to previously published data, prospectively implemented low dose DSE, and even in patients with negative such tests, where one could also consider, measuring CATS, troponins, BNP or NT-pro-BNP, and repeat an ECHO during the week following the low dose DSE, to ascertain whether there are late consequences of the low dose DSE (i.e., recurrent TTS), or evidence of myocardial injury in these vulnerable patients. Monitoring of the autonomic sympathetic input to the heart may be informative, to explore whether DSE-triggered TTS is mediated partially by the autonomic nervous system, solely precipitated by the DB, or CATS, in young/elderly patients [9, 13, 24-27, 63].

Evaluation of DSE data from patients with normal DSE

A similar analysis of the massive data from normal DSE tests can be carried out, particularly from elderly/post-menopausal women, focusing on the ECHO RHMR in the 2 ventricles, their intensity and evolution, and the relationship with history of hypertension, ECG and/or ECHO LVH, sigmoid septum, smaller LV outflow tract, reduced left ventricular volumes, or excessively mobile mitral valve apparatus, various degrees of SAM, and their dissipation after the DSE [2, 9, 27]. Exploration regarding enhanced responsiveness to DB with possible apical or basal RHMR, and the effect of age (vide supra) should be carried out [13, 24, 25, 35, 36, 40, 41, 63].

Evaluation of DSE data from patients with positive DSE for CAD

Since patients with combined TTS and CAD leading to AMI have been described, examination of data from patients with positive DSE for CAD, may be of value to explore the pathophysiology of TTS [70, 74]. In such a scenario one would expect to find RWMAs related to the myocardial territories impacted by the underlying CAD, in association with an occasional remote (usually contralateral) RWMAs due to a rare case of a DSE-triggered TTS, or more commonly a phase of transient RWMAs due to DB-induced mild or atypical TTS. According to what has been described above, scrutiny should be directed at both the RWMAs, due to the underlying CAD, and the rare remote RWMAs resulting from DB, and whether the latter were preceded by RHMR, their natural course, and whether there was evidence of their eventual complete reversibility. One could speculate herein that the "ischemic" RMCAs would recover earlier than the rare "TTS" RWMAs, in the DSE recovery ECHO.

Funding

No funding was received for this work.

Disclosures

None.

References

1. Goldman L (2018) Autopsy 2018: Still necessary, even if occasionally not sufficient. *Circulation* 137: 286-2688. [Crossref]
2. Ghadri JR, Wittstein IS, Prasad A, Sharkey S, Dote K, et al. (2018) International Expert Consensus Document on Takotsubo Syndrome (Part I): Clinical Characteristics, Diagnostic Criteria, and Pathophysiology. *Eur Heart J* 39: 2032-2046. [Crossref]
3. Paur H, Wright PT, Sikkel MB, Tranter MH, Mansfield C, et al. (2012) High levels of circulating epinephrine trigger apical cardiodepression in a β2-adrenergic receptor/Gi-dependent manner: a new model of Takotsubo cardiomyopathy. *Circulation* 126: 697-706. [Crossref]
4. Shao Y, Redfors B, Scharin Tang M, Möllmann H, Troidl C, et al. (2013) Novel rat model reveals important roles of beta- adrenoreceptors in stress-induced cardiomyopathy. *Int J Cardiol* 168: 1943-1950. [Crossref]
5. Nakano T, Onoue K, Nakada Y, Hitoshi Nakagawa, Takuya Kumazawa, et al. (2018) Alteration of β-adrenoceptor signaling in left ventricle of acute phase takotsubo syndrome: a human study. *Sci Rep* 8: 12731. [Crossref]
6. Surikow SY, Nguyen TH, Stafford I, Matthew Chapman, Sujith Chacko, et al. (2018) Nitrosative stress as a modulator of inflammatory change in a model of takotsubo syndrome. *JACC Basic Transl Sci* 3: 213-226. [Crossref]
7. Borchert T, Hübscher D, Guessoum CI, Lam TD, Ghadri JR, et al. Catecholamine-dependent β-adrenergic signaling in a pluripotent stem cell model of takotsubo cardiomyopathy. *J Am Coll Cardiol* 70: 975-991. [Crossref]
8. Samuels MA (2007) The brain-heart connection. *Circulation* 116: 77-84. [Crossref]
9. Y-Hassan S, Tornvall P (2018) Epidemiology, pathogenesis, and management of takotsubo syndrome. *Clin Auton Res* 28: 53-65. [Crossref]
10. Wittstein IS, Thiemann DR, Lima JA, Baughman KL, Schulman SP, et al. (2005) Neurohumoral features of myocardial stunning due to sudden emotional stress. *N Engl J Med* 352: 539-548. [Crossref]
11. Golbasi Z, Sakalli M, Cicek D, Aydogdu S (1999) Dynamic left ventricular outflow tract obstruction in a patient with pheochromocytoma. *Jpn Heart J* 40: 831-835. [Crossref]
12. Takizawa M, Kobayakawa N, Uozumi H, Yonemura S, Kodama T, et al. (2007) A case of transient left ventricular ballooning with pheochromocytoma, supporting pathogenetic role of catecholamines in stress-induced cardiomyopathy or takotsubo cardiomyopathy. *Int J Cardiol* 114: 15-17. [Crossref]
13. Abraham J, Mudd JO, Kapur NK, Klein K, Champion HC, et al. (2009) Stress cardiomyopathy after intravenous administration of catecholamines and beta-receptor agonists. *J Am Coll Cardiol* 53: 1320-1325. [Crossref]
14. Margey R, Diamond P, McCann H, Sugrue D (2009) Dobutamine stress echo-induced apical ballooning (Takotsubo) syndrome. *Eur J Echocardiogr* 10: 395-399. [Crossref]
15. Silberbauer J, Hong P, Lloyd GW (2008) Takotsubo cardiomyopathy (left ventricular ballooning syndrome) induced during dobutamine stress echocardiography. *Eur J Echocardiogr* 9: 136-138. [Crossref]
16. Cherian J, Kothari S, Angelis D, Downey B, Kirkpatrick J Jr, et al. (2008) Atypical Takotsubo cardiomyopathy: dobutamine-precipitated apical ballooning with left ventricular outflow tract obstruction. *Tex Heart Inst J* 35: 73-75. [Crossref]
17. Arias AM, Oberti PF, Pizarro R, Falconi ML, de Arenaza DP, et al. (2011) Dobutamine-precipitated Takotsubo cardiomyopathy mimicking acute myocardial infarction: a multimodality image approach. *Circulation* 124: 312-315. [Crossref]
18. Fineschi M, D'Ascenzi F, Sirbu V, Mondillo S, Pierli C (2013) The role of optical coherence tomography in clarifying the mechanisms for dobutamine stress echocardiography-induced takotsubo cardiomyopathy. *Echocardiography* 30: 121-124. [Crossref]
19. Hajsadeghi S, Rahbar MH, Iranpour A1, Salehi A, Asadi O, et al. (2018) Dobutamine-induced takotsubo cardiomyopathy: A systematic review of the literature and case report. *Anatol J Cardiol* 19: 412-416. [Crossref]

20. Jhawar MB, Balla S, Alpert MA, Chockalingam A (2011) Left ventricular outflow tract and mid-cavity obstruction may cause false-positive dobutamine stress echocardiograms. *Eur J Echocardiogr* 12: E14. [Crossref]

21. Skolnick AH, Michelin K, Nayar A, Fisher D, Kronzon I (2009) Transient apical ballooning syndrome precipitated by dobutamine stress testing. *Ann Intern Med* 150: 501-502. [Crossref]

22. Vasconcelos Filho FJ, Gomes CA, Queiroz OA, Barreto JE (2009) Dobutamine stress echocardiography-induced broken heart syndrome (Takotsubo Syndrome). *Arq Bras Cardiol* 93: 5-7. [Crossref]

23. Gastwirth VG, Yang HS, Steidley DE, Scott RL, Chandrasekaran K (2009) Dobutamine stress-induced cardiomyopathy in an orthotopic heart transplant patient. *J Heart Lung Transplant* 28: 968-970. [Crossref]

24. Mori H, Ishikawa S, Kojima S, Hayashi J, Watanabe Y, et al. (1993) Increased responsiveness of left ventricular apical myocardium to adrenergic stimuli. *Cardiovasc Res* 27: 192-198. [Crossref]

25. Kawano H, Okada R, Yano K (2003) Histological study on the distribution of autonomic nerves in the human heart. *Heart Vessels* 18: 32-39. [Crossref]

26. 26.Y-Hassan S, Henareh L (2015) Plasma catecholamine levels in patients with takotsubo syndrome: Implications for the pathogenesis of the disease. *Int J Cardiol* 181: 35-38. [Crossref]

27. Madias JE (2017) A proposal for a noninvasive monitoring of sympathetic nerve activity in patients with takotsubo syndrome. *Med Hypotheses* 109: 97-101. [Crossref]

28. Ueyama T, Kasamatsu K, Hano T, Tsuruo Y, Ishikura F (2008) Catecholamines and estrogen are involved in the pathogenesis of emotional stress-induced acute heart attack. *Ann N Y Acad Sci* 1148: 479-485. [Crossref]

29. Shao Y, Redfors B, Ståhlman M, Täng MS, Miljanovic A, et al. (2013) A mouse model reveals an important role for catecholamine-induced lipotoxicity in the pathogenesis of stress-induced cardiomyopathy. *Eur J Heart Fail* 15: 9-22. [Crossref]

30. Shao Y, Redfors B, Scharin Täng M, Möllmann H, Troidl C, et al. Novel rat model reveals important roles of β-adrenoreceptors in stress-induced cardiomyopathy. *Int J Cardiol* 168: 1943-1950. [Crossref]

31. Redfors B, Shao Y, Wikström J, Lyon AR, Oldfors A, et al. (2014) Contrast echocardiography reveals apparently normal coronary perfusion in a rat model of stress-induced (Takotsubo) cardiomyopathy. *Eur Heart J Cardiovasc Imaging* 15: 152-157. [Crossref]

32. Ueyama T, Tanioku T, Nuta J, Kujira K, Ito T, et al. (2006) Estrogen alters c-Fos response to immobilization stress in the brain of ovariectomized rats. *Brain Res* 1084: 67-79. [Crossref]

33. Redfors B, Ali A, Shao Y, Lundgren J, Gan LM, et al. (2014) Different catecholamines induce different patterns of takotsubo-like cardiac dysfunction in an apparently afterload dependent manner. *Int J Cardiol* 174: 330-336. [Crossref]

34. Redfors B, Shao Y, Ali A, Omerovic E (2013) Are the different patterns of stress-induced (Takotsubo) cardiomyopathy explained by regional mechanical overload and demand:supply mismatch in selected ventricular regions? *Med Hypotheses* 81: 954-960. [Crossref]

35. Pellikka PA, Nagueh SF, Elhendy AA, Kuehl CA, Sawada SG; American Society of Echocardiography (2007) American Society of Echocardiography recommendations for performance, interpretation, and application of stress echocardiography. *J Am Soc Echocardiogr* 20: 1021-1041. [Crossref]

36. Lang RM, Bierig M, Devereux RB, Flachskampf FA, Foster E, et al. (2005) Recommendations for chamber quantification: a report from the American Society of Echocardiography's Guidelines and Standards Committee and the Chamber Quantification Writing Group, developed in conjunction with the European Association of Echocardiography, a branch of the European Society of Cardiology. *J Am Soc Echocardiogr* 18: 1440-1463. [Crossref]

37. Stöhr EJ, Shave RE, Baggish AL, Weiner RB (2016) Left ventricular twist mechanics in the context of normal physiology and cardiovascular disease: a review of studies using speckle tracking echocardiography. *Am J Physiol Heart Circ Physiol* 311: 633-644. [Crossref]

38. Leitman M, Lysyansky P, Sidenko S, Shir V, Peleg E, et al. (2004) Two-dimensional strain-a novel software for real-time quantitative echocardiographic assessment of myocardial function. *J Am Soc Echocardiogr* 17: 1021-1029. [Crossref]

39. Edvardsen T, Gerber BL, Garot J, Bluemke DA, Lima JA, et al. (2002) Quantitative assessment of intrinsic regional myocardial deformation by Doppler strain rate echocardiography in humans: validation against three-dimensional tagged magnetic resonance imaging. *Circulation* 106: 50-56. [Crossref]

40. Dias A, Franco E, Rubio M, Bhalla V, Pressman GS, et al. (2018) Usefulness of left ventricular strain analysis in patients with takotsubo syndrome during acute phase. *Echocardiography* 35: 179-183. [Crossref]

41. Kowalski M, Herregods MC, Herbots L, Weidemann F, Simmons L, et al. (2003) The feasibility of ultrasonic regional strain and strain rate imaging in quantifying dobutamine stress echocardiography. *Eur J Echocardiogr* 4: 81-91. [Crossref]

42. Merken J, Brunner-La Rocca HP, Weerts J, Verdonschot J, Hazebroek M, et al. Heart failure with recovered ejection fraction. *J Am Coll Cardiol* 72: 1557-1558. [Crossref]

43. Ghadri JR, Wittstein IS, Prasad A, Sharkey S, Dote K, et al. (2018) International Expert Consensus Document on Takotsubo Syndrome (Part II): Diagnostic Workup, Outcome, and Management. *Eur Heart J* 39: 2047-2062. [Crossref]

44. Sakaguchi Y, Ozaki K, Takano T, Namba H, Tanaka K, et al. (2018) Dynamic left ventricular outflow tract obstruction complicated with takotsubo cardiomyopathy: The acute phase of takotsubo cardiomyopathy manifests latent left ventricular outflow tract obstruction. *J Cardiol Cases* 18: 60-64. [Crossref]

45. De Backer O, Debonnaire P, Gevaert S, Missault L, Gheeraert P, et al. (2014) Prevalence, associated factors and management implications of left ventricular outflow tract obstruction in Takotsubo cardiomyopathy: a two-year, two-center experience. *BMC Cardiovasc Disord* 14: 147. [Crossref]

46. Pellikka PA, Oh JK, Bailey KR, Nichols BA, Monahan KH, et al. (1992) Dynamic intraventricular obstruction during dobutamine stress echocardiography. A new observation. *Circulation* 86: 1429-1432. [Crossref]

47. Henein MY, O'Sullican C, Sulton GC, Gibson DG, Coats AJ (1997) Stress-induced left ventricular outflow tract obstruction: A potential cause of dyspnea in the elderly. *J Am Coll Cardiol* 30: 1303-1307. [Crossref]

48. Luria D, Klutstein MW, Rosenmann D, Shaheen J, Sergey S, et al. (1999) Prevalence and significance of left ventricular outflow gradient during dobutamine echocardiography. *Eur Heart J* 20: 386-392. [Crossref]

49. Merli E, Sutcliffe S, Gori M, Sutherland G (2006) Takotsubo cardiomyopathy: new insights into the possible underlying pathophysiology. *Eur J Echocardiogr* 7: 53-61. [Crossref]

50. Desmet W (2006) Dynamic LV obstruction in apical ballooning syndrome: the chicken or the egg. *Eur J Echocardiogr* 7: 1-4. [Crossref]

51. Azechi N, Morita Y, Inoue M, Kuzuyama R, Imataka K (1993) Age associated morphological change in interventricular septum. *Rinsho Byori* 41: 285-288. [Crossref]

52. Iida K, Sugishita Y, Ajiasaka R, Matsumoto R, Higuchi Y, et al. (1986) Sigmoid septum causing left ventricular outflow tract obstruction: a case report. *J Cardiogr* 16: 237-247. [Crossref]

53. Scuteri L, Baldini E, Repetto A, Brambilla N, Lanzarini L, et al. (2004) Left ventricular apical ballooning syndrome in a Caucasian population: echocardiographic presentation and evolution and response to stress echocardiography. *Eur J Echocardiogr* 5: 19: 193.

54. 54 Dawn B, Paliwal VS, Raza ST, Mastali K, Longaker RA, et al. (2005) Left ventricular outflow tract obstruction provoked during

dobutamine stress echocardiography predicts future chest pain, syncope, and near syncope. *Am Heart J* 149: 908-916. [Crossref]

55. Murakami H, Nishimura M, Urabe K (1996) Relation between dynamic midventricular obstruction and unexplained chest pain in patients with normal echocardiograms at rest. *Am J Cardiol* 78: 1063-1065. [Crossref]
56. Barletta G, Del Bene MR, Gallini C, Salvi S, Costanzo E, et al. (1999) The clinical impact of dynamic intraventricular obstruction during dobutamine stress echocardiography. *Int J Cardiol* 70: 179-189. [Crossref]
57. Lau TK, Navarijo J, Stainback R (2001) Pseudo-false-positive exercise treadmill testing caused by systolic anterior motion of the anterior mitral valve leaflet. *Tex Heart Inst J* 28: 308-311. [Crossref]
58. Dhoble A, Abdelmoneim SS, Bernier M, Oh JK, Mulvagh SL (2008) Transient left ventricular apical ballooning and exercise induced hypertension during treadmill exercise testing: is there a common hypersympathetic mechanism? *Cardiovasc Ultrasound* 6: 37. [Crossref]
59. Ha JW, Juracan EM, Mahoney DW, Oh JK, Shub C, et al. (2002) Hypertensive response to exercise: a potential cause for new wall motion abnormality in the absence of coronary artery disease. *J Am Coll Cardiol* 39: 323-327. [Crossref]
60. Barnard RJ, MacAlpin R, Kattus AA, Buckberg GD (1973) Ischemic response to sudden strenuous exercise in healthy men. *Circulation* 48: 936-942. [Crossref]
61. Chockalingam A, Dorairajan S, Bhalla M, Dellsperger KC (2009) Unexplained hypotension: the spectrum of dynamic left ventricular outflow tract obstruction in critical care settings. *Crit Care Med* 37: 729-734. [Crossref]
62. From AM, Prasad A, Pellikka PA, McCully RB (2009) Are some false-positive stress echocardiograms a forme fruste variety of apical ballooning syndrome? *Am J Cardiol* 103: 1434-1438. [Crossref]
63. Ramaraj R, Movahed MR (2010) Reverse or inverted takotsubo cardiomyopathy (reverse left ventricular apical ballooning syndrome) presents at a younger age compared with the mid or apical variant and is always associated with triggering stress. *Congest Heart Fail* 16: 284-286. [Crossref]
64. Makaryus AN, Meraj P, Rosman D (2006) Dynamic left ventricular outflow tract obstruction induced by dobutamine stress echocardiography leading to myocardial ischemia and infarction. *Int J Cardiovasc Imaging* 22: 763-769. [Crossref]
65. Dandel M, Lehmkuhl HB, Schmidt G, Knosalla C, Hetzer R (2009) Striking observations during emergency catecholamine treatment of cardiac syncope in a patient with initially unrecognized Takotsubo cardiomyopathy. *Circ J* 73: 1543-1546. [Crossref]
66. Dandel M, Lehmkuhl H, Knosalla C, Hetzer R (2009) Left ventricular wall motion abnormality and myocardial dysfunction in stress cardiomyopathy: new pathophysiological aspects suggested by echocardiography. *Int J Cardiol* 135: 40-43. [Crossref]
67. Yalçin F, Yalçin H, Abraham T (2010) Stress-induced regional features of left ventricle is related to pathogenesis of clinical conditions with both acute and chronic stress. *Int J Cardiol* 145: 367-368. [Crossref]
68. Yalçin F, Muderrisoğlu H Takotsubo cardiomyopathy may be associated with cardiac geometric features as observed in hypertensive heart disease. *Int J Cardiol* 135: 251-252. [Crossref]
69. Aurigemma PS, Douglas H.W. Gaasch (2002) Quantitative evaluation of left ventricular structure, wall stress and systolic function C.M. Otto (Ed.), The Practice of Clinical Echocardiography, WB Saunders Company, Philadelphia 65-87.
70. Y-Hassan S (2018) Tight coronary artery stenosis and takotsubo syndrome triggered each other: well-illustrated in a case. *Cardiovasc Revasc Med* 19: 2-4. [Crossref]
71. 71.Yalçin F, F Yigit F, Erol T, Baltali M, Korkmaz ME, et al. (2006) Effect of dobutamine stress on basal septal tissue dynamics in hypertensive patients with basal septal hypertrophy. *J Hum Hypertens* 20: 628-630. [Crossref]
72. Yalçin F, Muderrisoglu H, Korkmaz ME, Ozin B, Baltali M, et al. (2004) The effect of dobutamine stress on left ventricular outflow tract gradients in hypertensive patients with basal septal hypertrophy. *Angiology* 55: 295-301. [Crossref]
73. Dhoble A, Abdelmoneim SS, Bernier M, Oh JK, Mulvagh SL (2008) Transient left ventricular apical ballooning and exercise induced hypertension during treadmill exercise testing: is there a common hypersympathetic mechanism? *Cardiovasc Ultrasound* 6: 37. [Crossref]
74. Hurtado Rendon IS, Alcivar D, Rodriguez-Escudero JP, Silver K (2018) Acute Myocardial Infarction and Stress Cardiomyopathy Are Not Mutually Exclusive. *Am J Med* 131: 202-205. [Crossref]