

Available online at www.scienceopen.com

Science Repository



Case Report

Application of Tenodesis for an Extremely Rare Hand Extensor Injury in an Athlete: A Case Report

João Pereira*, André Moreira, Joana Azevedo, David Ferreira, Elisabete Ribeiro, Pedro Varanda and Luís Rodrigues

Serviço de Ortopedia E Traumatologia; Hospital de Braga, Braga, Portugal

ARTICLE INFO

Article history:

Received: 22 February, 2024

Accepted: 12 April, 2024

Published: 26 April, 2024

Keywords:

Sports medicine

hand extensor injuries

tenodesis

ABSTRACT

Spontaneous tendon ruptures of the wrist are a rare pathology, usually secondary to rheumatoid arthritis or distal radius fractures and most commonly involving the extensor pollicis longus. Sport-related etiology is a growing tendency of this pathology. As far as the authors know, this is one of the first sport-related extensor carpi radialis brevis (ECRB) isolated spontaneous rupture described in the literature. We describe a case of a 41 year-old female amateur kickboxer who developed acute dorsal radial pain in the right wrist during practice. After attempting conservative treatment for 4 months with rest and NSAIDs she recurred at our clinic. Local pain at dorsal wrist extension was observed. MRI demonstrated an isolated ECRB rupture with associated fibrous tissue proximal to the extensor retinaculum. Surgical management was proposed and consisted of fibrous tissue debridement and ECRB-ECRL tenodesis. At 3 months of follow-up the patient reported return-to-play with impaired wrist motion and mild pain at maximum wrist extension. At 12 months of follow-up the patient was completely recovered and asymptomatic. Isolated tendon ruptures are a rare pathology, causing extreme pain and disability in the sport setting. Surgical management of this ECRB tendon rupture by tenodesis allowed for appropriate pain control and functional results and early return-to-play.

© 2024 João Pereira. Hosting by Science Repository.

Introduction

Hand extensor tendon traumatic injuries are common lesions specially among young athletes [1]. Several risk factors may lead to this type of injuries such as professional exposure to repetitive hand movements, medications such as fluoroquinolones, corticosteroid use and also pathologies such as rheumatoid arthritis. Furthermore, anatomical variations such as a carpal boss may be the cause of these injuries [2-5]. When in the context of sport injuries, these are frequently associated with striking sports such as boxing or kickboxing. In these sports, due to the emphasis on punching movements against hard targets with a closed fist, the hand is subject to extremely high levels of axial force, which, especially when associated with poor technique/amateur practice, may lead to extensor tendon injuries [6].

Insertional injuries of ECRB/ECRL tendons are usually due to forced hyperflexion in an actively extended wrist [7]. Avulsion injuries of these

tendons, in the base of the metacarpals are rare, due to strong capsule/ligament attachments [8]. The few cases described in the literature mostly involve young adults practicing high energy sport activities or falls [9]. Clinical diagnosis is not always simple, as ecchymosis may not be present in the acute setting and the patient may present only with non-specific dorsal wrist pain and difficulty in dorsiflexion [8, 10]. X rays and CT- scans often do not diagnose this type of pathology even when a bony avulsion is present [7].

When midsubstance tears are present, diagnosis can best be performed using MRI studies. As such, these lesions can be easily missed. Midsubstance extensor tendon tears are extremely rare and usually secondary to tendon atrophy and subsequent tear often due to attritional damage as is the case in rheumatoid or post-traumatic deformities [2, 3, 11]. Treatment usually comprises conservative measures with surgical treatment being recommended for the treatment of the insulting factor, as for the treatment of attritional rupture do to dorsal carpal boss [12,

*Correspondence to: João Pereira, Serviço de Ortopedia E Traumatologia; Hospital de Braga, Braga, Portugal; Tel: 00351961032671; E-mail: Joao.carvalho.pereira@hb.min-saude.pt

13]. In this case report we describe the successful application of a tenodesis technique in the treatment of a sports related ECRB midsubstance rupture.

Case Description

A 41-year-old female, with no relevant past medical history came to our clinic due to sudden radial sided pain in the dorsal wrist. She described the onset of pain after a kickboxing training session, which she practiced twice a week in an amateur regime. The pain was located in the base of

the dorsal aspect of the 2nd /3rd metacarpals and was associated with impaired wrist motion, mainly extension, which compromised her daily routine activities. At first, she tried to manage the case with rest and NSAID medication, with non-satisfactory results. Upon physical examination, there was noted radial dorsal side pain associated with wrist extension strength deficit when comparing with the contralateral side. MRI exam demonstrated an isolated distal ECRB rupture with associated fibrous tissue being present proximal to the extensor retinaculum (Figure 1). Surgical management of this lesion was decided.

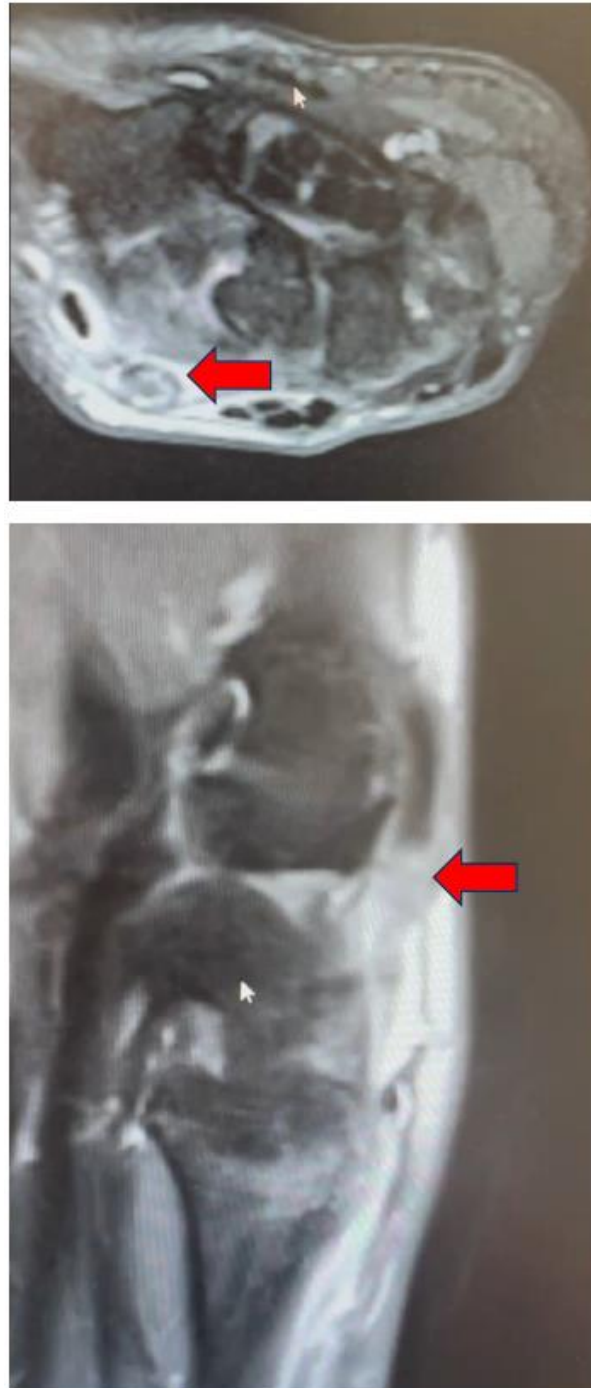

Figure 1: MRI studies showing lesion of the ECRB tendon (arrow).

Surgical Technique

Under a brachial plexus block, a straight skin incision was made over the dorsum of his left wrist, lining with the Lister's tubercle (Figure 2). Careful dissection was performed, incising and opening the extensor retinaculum. ECRB distal midsubstance rupture was then evident with the distal limb of the tendon being attached to the proximal limb by a slim fibrous tissue connection (Figure 3). Degenerative fibrous tissue was carefully debrided of the ECRB. The remaining healthy proximal and distal limbs of ECRB were subjected to tenodesis with ECRL, by a side-by-side technique, using P.D.S. suture (Figure 4). Judicious closure and dressing were applied, and a wrist extension cast was used.

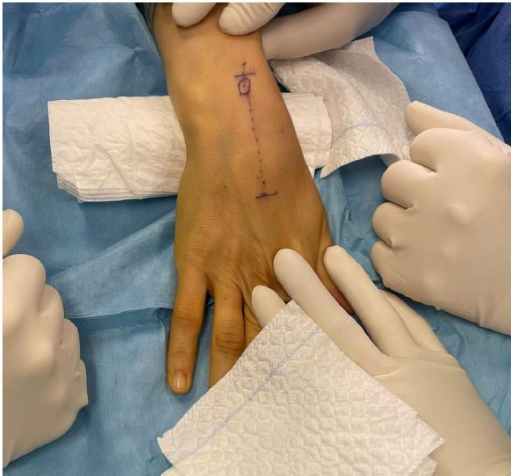

Figure 2: Surgical approach.

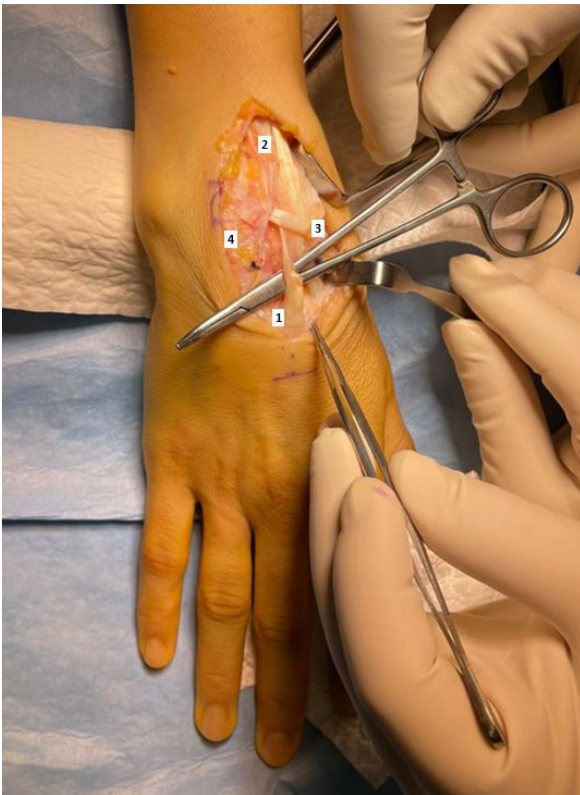


Figure 3: ECRB Rupture. 1) ECRB; 2) ECRL; 3) EPL; 4) Extensor retinaculum.

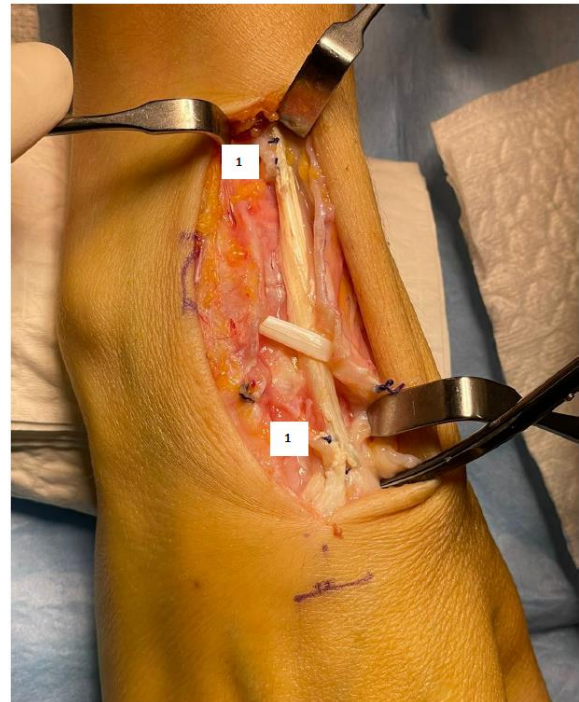


Figure 4: ECRB-ECRL tenodesis. 1) Side-to-side suture.

Results

Arm suspension and wrist cast immobilization were used for a month after surgery. After removing the cast, light ROM exercises were permitted, and physical therapy was commenced. At 3 months of follow-up, the patient reported decreased pain and gradual return to normal daily activities. At 12 months of follow-up, the patient reported only residual pain (maximum with daily activities of VAS 2), no activity restrains and identical ROM when comparing to the contralateral side.

Discussion

To our knowledge this case report represents the first published case of a sports trauma ECRB midsubstance tear. Accounts of isolated ECRB tears are rare, and mostly associated with bony avulsion, most of them treated with osteosynthesis of the avulsion fractures of the base of the 3rd metacarpal bone [8, 9, 14]. ECRB lesions may be important to overall wrist function due to the importance of this muscle in wrist dorsiflexion, and conservative and surgical treatment are both valid options [15]. Huffaker *et al.*, described an isolated ECRB midsubstance tear secondary to a dorsal scaphoid osteophyte, which was treated conservatively [2]. Gurich *et al.* reported good clinical results using ECRB-ECRL tenodesis in a late- presentation bony avulsion injury of both tendons [10].

As in this case, clinical signs were non-specific and MRI study was instrumental to the diagnosis of this pathology. There are several techniques described for the treatment of acute setting ECRB avulsion injury [9]. These all depend on a bony fragment to allow for osteosynthesis. When a midsubstance tear is present, treatment can either be conservative or surgical using side-to-side tenodesis with ECRL [2, 10]. In our case, surgical treatment was chosen as conservative treatment

did not prove to resolve the patients functional and pain symptoms. ECRB-ECRL tenodesis and inflammatory tissue debridement allowed for local pain resolution as well as patient functional improvement.

This is, as far as the authors are aware, the first report of isolated insertional midsubstance tear of ECRB in the sport setting. Treatment with side-to-side ECRB-ECRL tenodesis allowed for a quick return-to-work and good patient satisfaction.

Abbreviations

ECRB: Extensor Carpi Radialis Brevis

NSAIDs: Non-Steroid Anti-Inflammatory Drugs

MRI: Magnetic Resonance Imaging

ECRL: Extensor Carpi Radialis Longus

REFERENCES

- Dy CJ, Rosenblatt L, Lee SK (2013) Current methods and biomechanics of extensor tendon repairs. *Hand Clin* 29: 261-268. [[Crossref](#)]
- Huffaker SJ, Christoforou DC, Jupiter JB (2012) Spontaneous rupture of the extensor carpi radialis brevis in a 51-year-old man: case report. *J Hand Surg Am* 37: 1221-1224. [[Crossref](#)]
- Williamson SC, Feldon P (1995) Extensor tendon ruptures in rheumatoid arthritis. *Hand Clin*. Aug 11: 449-459. [[Crossref](#)]
- Hussen NHA, Qadir SH, Rahman HS, Hamalaw YY, Kareem PSS, et al. Long-term toxicity of fluoroquinolones: a comprehensive review. *Drug Chem Toxicol* 28: 1-12. [[Crossref](#)]
- Szarfman A, Chen M, Blum MD (1995) More on fluoroquinolone antibiotics and tendon rupture. *N Engl J Med* 332: 193. [[Crossref](#)]
- Loosemore M, Lightfoot J, Gatt I, Hayton M, Beardsley C (2017) Hand and Wrist Injuries in Elite Boxing: A Longitudinal Prospective Study (2005-2012) of the Great Britain Olympic Boxing Squad. *Hand (N Y)* 12: 181-187. [[Crossref](#)]
- Robert N, Zbili D, Bellity J, Doursounian L, Mauprivez R (2014) Avulsion fracture of the extensor carpi radialis longus carpal insertion due to a basketball injury: case report and literature review. *Chir Main* 33: 410-412. [[Crossref](#)]
- Johnson AE, Puttler EG (2006) Avulsion of the extensor carpi radialis brevis insertion: a case report and review of the literature. *Mil Med* 171: 136-138. [[Crossref](#)]
- Turker T, Capdarest Arest N (2013) Open isolated extensor carpi radialis brevis avulsion injury: a case report. *Hand (N Y)* 8: 354-357. [[Crossref](#)]
- Gurich Jr. RW, Tanksley Jr. JA, Pappas ND (2013) Late repair of combined extensor carpi radialis longus and brevis avulsion fractures. *Orthopedics* 36: 766-769. [[Crossref](#)]
- Vaughan Jackson OJ. Rupture of extensor tendons by attrition at the inferior radio- ulnar joint; report of two cases. *J Bone Joint Surg Br* 30B: 528-530. [[Crossref](#)]
- Park MJ, Namdari S, Weiss AP (2008) The carpal boss: review of diagnosis and treatment. *J Hand Surg Am* 33: 446-449. [[Crossref](#)]
- Clarke AM, Wheen DJ, Visvanathan S, Herbert TJ, Conolly WB (1999) The symptomatic carpal boss. Is simple excision enough? *J Hand Surg Br* 24: 591-595. [[Crossref](#)]
- Breeze SW, Ouellette T, Mays MM (2009) Isolated avulsion fracture of the extensor carpi radialis brevis insertion due to a boxer's injury. *Orthopedics* 32: 210. [[Crossref](#)]
- Brand PW, Beach RB, Thompson DE (1981) Relative tension and potential excursion of muscles in the forearm and hand. *J Hand Surg Am* 6: 209-219. [[Crossref](#)]