

Available online at www.sciencerepository.org

Science Repository



Review Article

Fixation Technique with Pedicle Screws Assisted with Intraoperative TC and Neuronavigation: A Systematic Review

Alejandra Arévalo-Sáenz^{1*}, Fernando J. Rascón-Ramírez¹ and Manuel Pedrosa Sánchez²

¹Department of Neurosurgery, Hospital Clinic San Carlos, Madrid, Spain

²Department of Neurosurgery, University Hospital of the Princess, Madrid, Spain

ARTICLE INFO

Article history:

Received: 25 October, 2023

Accepted: 17 November, 2023

Published: 6 December, 2023

Keywords:

Spinal instrumentation
transpedicular approach
accuracy
intraoperative tomography
neuronavigation

ABSTRACT

Background: The invasion of the spinal canal or vertebral foramina by implants can cause lesions in neurovascular structures, which is why various methods have been tried to improve the accuracy of their placement during surgery.

Objective: The objective of this review is to demonstrate, in our experience, the benefits of neuronavigation with intraoperative CT in spine surgery.

Methods and Materials: We present a retrospective review of 307 posterior transpedicular fixations (1524 screws) made from January 2009 to December 2015. The following variables are collected: patient demographics, instrumented levels, type of operation, time of surgery as well as postoperative image control.

Results: The average age has been 64.8 years; with discreet feminine predominance (57.3%). The predominant indication has been segmental instability, lumbar canal stenosis and spondylolisthesis. Levels L4-L5 and L5-S1 have been the most frequent. The predominant number of levels set by surgery has been 1 space (65%) and 2 spaces (22.7%). The study includes 11 different neurosurgeons. The rate of repositioning prior to hospital discharge was 0.2% (3/1524), a year of 0.32% (5/1524), and postoperative images were obtained by CT or MRI, which confirmed the correct placement of the implants, 1% of patients.

Conclusion: Nowadays, the techniques of navigation and intraoperative images provide us with technical precision, reduction of surgical times and reduction of the radiation dose, among other advantages. In our experience, although anatomical knowledge is irreplaceable, these systems confer quality on spine surgery.

© 2023 Alejandra Arévalo-Sáenz. Hosting by Science Repository.

Introduction

Image-guided surgery is one of the most important technological advances within the spinal surgery since it allows the surgeon to perform a three-dimensional multiplanar navigation in real time inside a vertebrae. Introduced in 1995, it was designed to increase accuracy during spinal instrumentation. Posterior vertebral instrumentation is a technique with high efficacy or endorsed in the literature for the treatment of degenerative, traumatic and tumor pathologies. It is a technique supported by a high level of scientific evidence, but not without complications, these being minimal in expert hands but that can lead to serious gravity depending on the level of the intervention. The deviation of a screw is the most reported complication with percentages

of 12 to 40%, of which only between 4 and 12% give clinical symptomatology [1-3]. In order to improve the accuracy of the implant, different methods have been provided such as guided frameless surgery, guided surgery with fluoroscopy and CT (Figure 1), neurophysiological monitoring, assisted endoscopy and ultrasound detection of the pedicle screw path. All of them allow improving the precision in the placement of the implant, but none of them offers a real-virtual direct image of the path of the screws until the introduction of the navigation. The objective of this paper is to present the series of cases of our service from 2009 to 2015, making a descriptive study of them, as well as showing the utility of neuronavigation and 3D fluoroscopy iso-C to avoid associated morbidity and increase accuracy in the placement of transpedicular screws.

*Correspondence to: Alejandra Arévalo-Sáenz, M.D., Department of Neurosurgery, Hospital Clinic San Carlos, Calle del Profesor Martín Lagos, s/n 28040 Madrid, Spain; Tel: 913303000; E-mail: praimale@hotmail.com

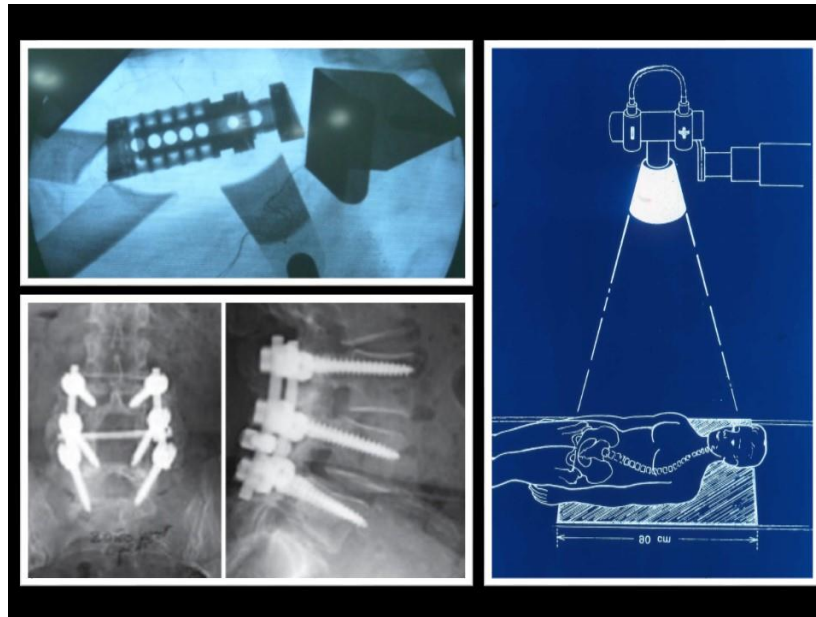


Figure 1: Images obtained by radioscopy.

In these images we observe images taken by radioscopy as well as the field of action of it.

Materials and Methods

We retrospectively reviewed the patients who underwent posterior transpedicular lumbosacral instrumentation between 2009-2015, considering their demographic characteristics, symptomatology, diagnosis, level of fixation, number of spaces intervened, number of screws placed, attachment performing the operation, used fixation system, and postsurgical control tests. As an independent variable, the relocation of the screws was used. The technique used by 3D fluorescence iso-C is described below. The patients were placed in the prone position at the Jackson-type surgical table. In all the interventions, the navigation system is inserted in the operating room and placed at the patient's feet (Figure 2). Two images of fluoroscopy in 2D mode are obtained in antero-posterior and lateral projection, subsequently collimated, which are used to delimit the surgical area to be treated. The

approach taken in the patients included in this series was a standard midline lumbar approach, with minimally invasive procedures being excluded in this study. Once the approach is made, the reference system for navigation is used, which is fixed by means of a clamp to one of the most caudal spinous processes of the approach, as long as it has adequate ossification. In case of absence of adequate posterior elements (bad ossification or previous surgery) we use the bolt-on reference to the iliac crest. In cases in which the arthrodesis was performed at more than three lumbar levels, the frame of reference was repositioned to a spinous process more superior and close to the target vertebrae (this repositioning implies the need to repeat the imaging study). Once the reference is placed on the patient, the equipment is placed centered in the surgical field and images are obtained in multiplanar 3D mode by means of a 180-degree turn (Figure 2).

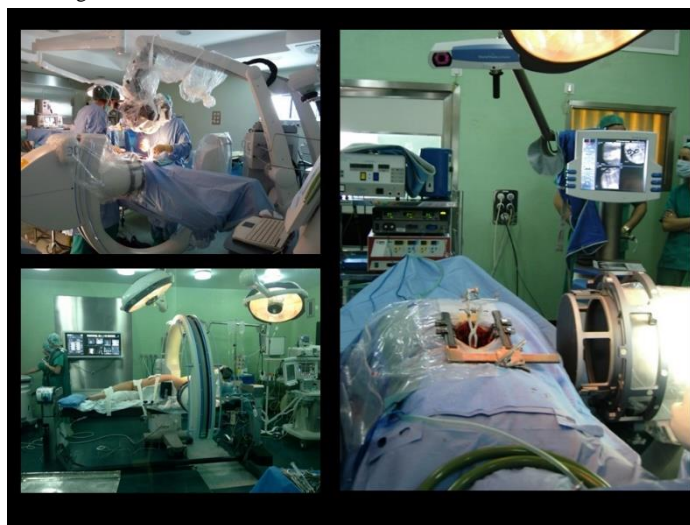


Figure 2: Organization of the operating room.

The configuration for spinal surgery is shown by intraoperative tac-assisted navigation. The patient is placed face down on a radiotransparent operating table. The frame of reference is attached to one of the spinous processes. The surgeon is located in front of the monitor.

The images are transferred automatically to the brain LAB vector vision team, which performs multiplanar reconstructions. In the work station, the trajectories to be used are decided, as well as the thickness and length

of the pedicle screws, entry point, insertion angle and depth of the same (Figure 3).

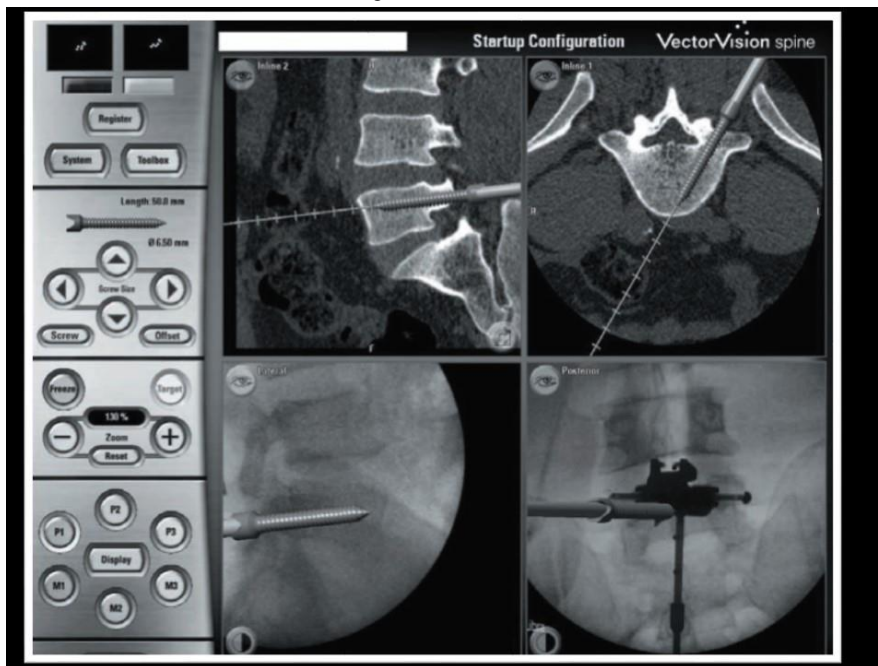

Figure 3: Control by neuronavigation.

Screen of the computer that is shown in the surgery. The punch of the pedicle is shown in different views: cross section (top left), axial section through pedicles (top right) and coronal section through pedicles (bottom right).

The cuts are also selected (anteroposterior or lateral scopy type, axial or sagittal reconstructions, etc.) that the surgeon wishes to use as a guide to introduce the screws. The device is placed at the patient's feet to allow surgical intervention, without contamination, in case its use is required. In all the patients we proceeded to check the placement of the transpedicular screws at the end of the procedure, by intraoperative CT the equipment is obtained. To assess the results of implant precision, the results of the postoperative CT were used and the rate of reposition was collected, as well as the average time to said event, the level and the affected side and the resolution or not of the clinic. The placement of each pedicle screw was evaluated according to the heary scale at 5

degrees (Table 1) and with the classification proposed by Wiesner and Schizas with modification (Table 2) [4, 5]. Screw position was classified as “cortical encroachment” (or questionable perforation) if the pedicle cortex could not be visualized or as “frank penetration” when the screw was outside the pedicular boundaries. Frank penetration was further subdivided- based on measurement of the distance that the edge of the screw thread extended outside the pedicle cortex- into minor (≤ 2.0 mm), moderate (2.1-4 mm or < 1 screw thread diameter), and severe (> 4 mm or > 1 screw diameter). Depending on the direction of the pedicle violation, the screw misplacement was noted as lateral, medial, inferior, or superior.

Table 1: Implant evaluation according to the heary tomographic scale.

Grade	Description
I	Screw completely contained in the pedicle.
II	Screw perforates the lateral wall of the pedicle but the tip is completely contained in the vertebral body.
III	Screw pierces the lateral wall of the pedicle.
IV	Perforation of the medial or inferior wall of the pedicle.
V	Perforation the vertebral body and endangers the spinal cord, root or vessel, requires intervention.

Table 2: Implant evaluation according to the classification proposed by Wiesner and Schizas.

Grade	Description
Cortical encroachment	Questionable perforation.
Frank penetration:	Distance that the edge of the screw thread extended outside the pedicle cortex.
Minor	≤ 2.0 mm.
Moderate:	2.1-4 mm or < 1 screw thread diameter.
Severe:	> 4 mm or > 1 screw diameter.

Results

301 patients were intervened, of whom 58% were women and 42% men with an average age of 64.8 years, being the most frequent ages 78 and 80 years. The most frequent diagnosis was degenerative pathology in 54%; spondylolisthesis in 21% and vertebral fracture in 7%. All patients underwent a browser-guided pedicle fixation as an auxiliary procedure for a spinal fusion. 1435 lumbosacral screws were placed. The most used system was TT-LIN of prim. The operations were carried out by 11 different attachments. The average number of screws per most frequent operation was 4 screws by 63% and 6 screws by 23%. The most frequently intervened level was L4-L5 in 44%, L3-L5 in 15% and L5-S1 in 10%. Postoperative control images were obtained in 73% of the

patients by CT or MRI and if we added the RX by 87%. The malposition of the screw was targeted by the CT controls and was evaluated by the heary tomographic scale. 142 patients underwent this test. 669 screws were evaluated. The total malposition rate per patient was 7.7% (11/142), the total malposition rate per screw was 1.6% (11/669).

699 screws evaluated postoperatively were classified as follows according to the scale heary's tomography: 98, 28% (687 screws) had a grade I with completely intraosseous screw placement. 0.28% (2 screws) were maintained in a grade II and 0.57 (4 screws) in a grade IV, being relevant the frequency with which L5 left tends to have a grade other than I (Figure 4). No complications related to the implants were observed. 5 screws in a grade V that required reoperation.

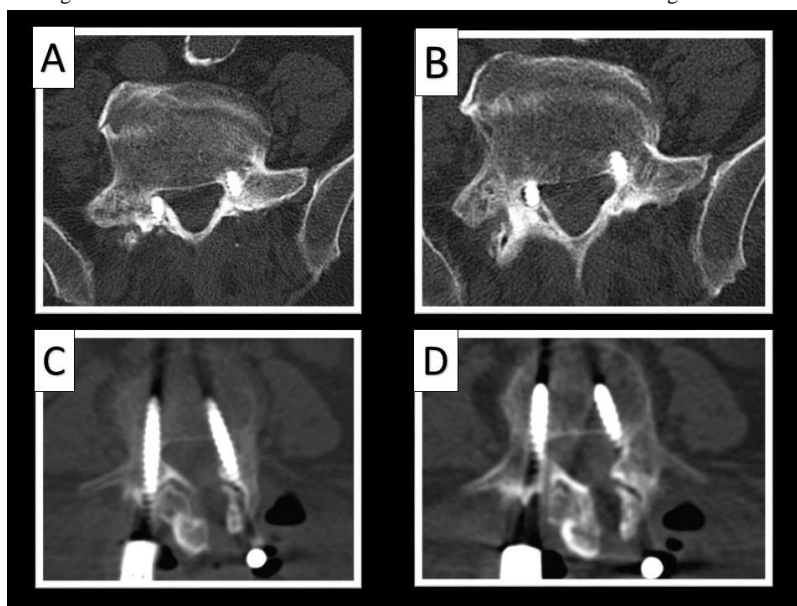


Figure 4: Postoperative CT in patients with medialized screws and invasion of the canal.

A & B) Postoperative CT scan demonstrating a medialization of the right L5 screw invading the upper region of the junction hole, in the same way in images C and D we observe how the left L5 screw is partially lodged in the foramen.

According to the classification of Wiesner and Schizas: Frank screw misplacement was observed in 9 screws (1.28%) and minimal or questionable pedicle wall violation in 2 screws (0.28%) [4, 5]. The remaining 688 screws (98.4%) were judged as correctly inserted. Of the

9 misplaced screws, 4 misplacements were classified as minor (cortical perforation less than 2 mm), and 5 as severe penetration (> 4 mm) (Table 3).

Table 3: Computes tomography evaluation of screw placement according to Wiesner and Schizas scale.

Screw Placement	No of screws(%)
Correct	688 (98.4%)
Encroachment (or questionable)	2 (0.28%)
Frank penetration	9 (1.28%)
Minor	4 (0.57%)
Moderate	0 (0%)
Severe	5 (0.29%)

In relation to the rate of relocation of the screws, 5 patients were subsidiary of said procedure for clinical reasons derived from neural irritation, mainly pain, without neurological symptoms manifested as loss of strength or alterations in sensitivity. All the patients had good surgical response without complications or sequelae.

The relocation rate of the total bolts prior to discharge was 0.2% (3 screws), 0.32% (5 screws) per year. The affected levels were L5 three times and L4 in two, being the most frequent left L5 (Table 4).

Table 4: Distribution of misplaced screws with surgical requirement.

Patient	Edad	Date	Intervened segment	Level	Side	Time after
1	50	April 2009	L4-S1	L5	Left	2 m.
2	83	November 2013	L3-L5	L5	Right	7 m.
3	85	December 2013	L2-L5	L4	Left	Entry
4	49	November 2014	L4-L5	L5	Left	Entry
6	51	October 2015	L4-L5	L4	Right	Entry

Discussion

The navigation was applied in the column from the year 2000, but due to a limitation of the software and hardware, the slowness of the procedure, a difficult learning curve and the benefit-cost ratio, it was not integrated into the technological arsenal for spine surgery. Since 2007 and after improving these aspects, navigation has experienced an expansion of its use. Different navigation systems have been described for the fixation of the column according to the method and obtaining radiological images as we will describe later. The use of transpedicular fixation for the stabilization of the spine is one of the techniques currently used in the pathology of the spine indicated in infections, tumors, trauma and deformities (Figure 1) [6].

The traditional method for placing pedicle screws uses anatomical surface references combined with the guidance provided by intraoperative fluoroscopy. Although this technique has proven useful, it has limitations, since it only provides a two-dimensional image of a complex three-dimensional structure. With the use of this technique, different authors report errors due to malposition of the screws in

percentages ranging from 10 to 20% and that involve neurological damage in 4.5% of patients [7].

On occasion, as reported by Gómez de la Riva *et al.* On a series of 74 patients with lumbar canal stenosis operated by decompression and pedicle fixation, the malposition of the pedicle screws accompanied by neurological symptoms requires surgical reoperation in 2.7% of the patients [8]. It has been documented that the bad position of a pedicle screw in a monosegmentary fixation (4 screws) compromises the stability of the vertebral fixation because it reduces the grip strength by up to 11%. The percentage increases depending on the number of badly placed screws [9]. Numerous techniques have been described to try to improve the precision in the placement of pedicle screws: direct vision by laminectomy, neurophysiological monitoring during the introduction of the screw in the pedicle and intrapedicular or epidural endoscopy [10]. Different studies conducted both *in vivo* and *in vitro* indicate that image-guided surgery significantly improves the correct placement of the screws within the pedicle when compared with the traditional method [11, 12]. There are different navigation options; among them the navigation with fluoro 2D-TC, fluoro iso-C 3D and navigation by TC (Table 5).

Table 5: Comparative scheme between the different spinal navigation systems.

Method	Navigation by TC	Fluoro iso-C 3D	Fluoro 2D-TC
Image	3D high quality bone anatomy.	3D, limited to a volume of 120 mm ³ , limited to obese.	2D, limited to obese.
Preoperative	Required CT High-resolution reconstruction.	Does not require preoperative images.	Does not require preoperative images.
Intraoperative	Manual registration. It does not correct errors.	Automatic registration, correct errors.	Multiple images, automatic registration, long surgical time.
Postoperative	CT may be necessary.	Not necessary CT.	CT may be necessary.

In this scheme we observe the different navigation systems for the fixation of the column according to the method and obtaining radiological images with fluoro 2D-CT, fluoro iso C-3D, and navigation by, being the differences in accuracy between them insignificant.

All of them have in common the need to associate with a navigator and that they reduce the deviation of the implant below 10% as well as the number of reinterventions [13]. Lumbar level is where there is more experience of the use of the navigator because the frequency of pathology is mainly of degenerative origin. The deviation of a screw at the lumbar level is variable and in relation to the experience of the surgeon being the deviation of the most referred to with figures from 6.5% or from 11.4% to 42.3 % without navigation compared to 4.3% to 6.8% with fluoro-CT or from 0.0 to 3.6% with fluoro ISO-C 3D [14-16]. 3D neuronavigation techniques are clearly superior to 2D, in our experience although reports in the literature sometimes do not reach significance. In a large cohort study, 1084 screws were placed with assistance based on the TAC (perforation rate of 9.2%) or 3D navigation based on fluoroscopy (drilling rate of 6.6%) and the difference in the rates between these two groups was statistically insignificant (P = 0.0936) [17].

A retrospective study comparing the 2D and 3D fluoronav systems indicated, found that both systems were comparatively safe and the choice of modality can be determined by the level of comfort and / or availability of the system [16]. In another view Gruetzner *et al.* if they reported the remarkably improved precision in inserting the screw transpedicularly with the help of 3D fluoronav compared to conventional, CTNav and 2Dfluoronavmethods [18, 19]. We will highlight the differences between iso centric 3D and the O-arm [16-18]. 3D fluoroscopy (iso-C3D): It is the imaging method used in our study. It was developed in 2003 and is the third generation of browsers. The patient is placed in the surgical position and intraoperative images are obtained from an isocentric fluoroscopy with a C-arm, this system makes a 180° turn on the patient and performs a sequence of 100 images at 1° of angulation in each section during 9'0s. In this way, the three space planes are reconstructed and a real-time image of the position of the patient's column is provided. Navigation is performed on these

reconstructions and a manual registration phase is not needed. One of the advantages of this system compared to the previous generations is that it allows the realization of an intraoperative CT to confirm the correct placement of the screws [20, 21].

Navigation with conical source CT: It is the latest generation of browsers and improves the intraoperative CT image by 360 rotations on the patient obtaining 390 images. The prototype is the O-arm. It is of high quality especially in complex spaces such as the cervico-dorsal hinge and is capable of acquiring more volume than the iso-C 3D but has a series of drawbacks, especially the lower versatility, since it has limitations due to the surgical table and its internal diameter. Its cost is 3 times higher than iso-C 3D occupies more space and will need qualified personnel [22]. Table 3 summarizes the advantages of the system. Both systems allow intraoperative verification of implant placement, the equipment does not require a previous registration, the time and dose of radiation is reduced, repeated movements of the fluoroscope during surgery are avoided since the visualization of the surgical instruments in relation to the anatomy of the patient is determined from the beginning of the surgery [23].

The rate of violation of the medial wall of the pedicle that can cause catastrophic neurological damage is 0% compared to 5% in the fluoroscopy group [23].

Regarding the point of comparison of both navigation systems Tian and colleagues after a meta-analysis of 54 studies (35 *in vivo* and 20 *in vitro*) conclude that navigation based on CT image provides greater precision in the placement of pedicle screws in both groups (*in vivo* = 90.76%, *in vitro* = 94.59%) compared to the 2D fluoronavigation group (*in vivo* = 85.48%, *in vitro* = 90.12%) [24]. In our study group, using a third-generation navigation system guided by CT imaging, we achieved a reliability of 98.4% in the insertion of pedicle screws, which corresponds to the results of the series published in the meta-analysis of Tian [24].

I Screw Relocation

The relocation of the screw is not always essential when a completely intraosseous path is not visualized by the intraoperative CT scan. It should be noted that 85%-90% of the deviated screws are clinically asymptomatic and although it is true that depending on the deviation can alter the biomechanics of the fusion, it is also true that the completion of another transpedicular path can alter it by itself [25].

II Contraindications

Currently and in our experience, there are no formal contraindications for the use of the browser. Our operating rooms, equipped with a Jackson table, maintain the stability of the spine and reduce to almost zero the possibilities of movements and induction of error of the navigator. In the same way if the segment where it is planned to place the registration star is unstable, we can always overcome this inconvenience with the placement of the star in the iliac crest.

Many of the allusions to the lack of use of the column navigator is the theoretical learning curve that the system has and the added surgical time it represents. This curve, if it exists, is minimal and only related to the familiarization of the technology. Reason that shows that in our service

11 different attachments use the same technique, and even finding ourselves in a university hospital the resident is able to perform such techniques on numerous occasions.

In our experience, the surgical time with the use of navigation is less, once the learning curve has been overcome. In our study it was not possible to make such a comparison but according to the studies referred to in the literature [26, 27]. Other perioperative findings are exposure to radiation, blood loss and the functional status of patients [28].

As for the lower irradiation that it means for doctors and patients; the authors have not quantified the total irradiation with dosimeter but if we take into account the number of shots; an average of 2 shots per patient will be made, compared to the minimum of 4 or more shots per screw in a procedure without navigation. In the prospective study conducted by Gebhard *et al.*, 2D fluoronav was found to produce less radiation than the conventional C arm, but more radiation than CTNav. In addition, it was observed that 3D fluoronav had an additional reduction in intraoperative radiation dose compared to other navigation methods [29].

Slomczykowski *et al.* analyses the radiation of three different CT-based navigation system protocols, noted that when CTNav was used, the spiral CT mode was recommended. Theoretically fluoronav could reduce the operating time of the radiation compared to the conventional fluoroscopy method, because such systems do not need repeated movement of the C arm intraoperatively [30].

Conclusion

Different studies performed both *in vivo* and *in vitro* indicate that image-guided surgery significantly improves the correct placement of the screws within the pedicle when compared to the traditional method.

Computer-assisted surgery improves accuracy during transpedicular fixation and minimizes the risk of neurological and vascular injuries. In addition to reducing possible complications, there is an additional advantage since the interosseous placement of each screw provides a better grip strength for each instrumented level.

Funding

None.

Conflicts of Interest

None.

REFERENCES

1. Florensa R, Noboa R, Muñoz J, Colet S, Cladellas JM *et al.* (2001) Complicaciones de la artrodesis transpedicular lumbar. *Neurocirugía*, 12: 216-217.
2. Florensa R, Noboa R, Muñoz J, Colet S, Cladellas JM *et al.* (2002) Results of C1-C2 transarticular screw fixation in a series of 20 patients. *Neurocirugía (Astur)*, 13: 429-435. [[Crossref](#)]
3. Kim JM, Bowers AL, Chin KR (2007) Intraoperative Imaging Techniques in Spine Surgery. *J Spinal Disord Tech* 20: 78-86.

4. Wiesner L, Kothe R, Schulitz KP, Rütther W (2000) Clinical evaluation and computed tomography scan analysis of screw tracts after percutaneous insertion of pedicle screws in the lumbar spine. *Spine (Phila Pa 1976)* 25: 615-621. [[Crossref](#)]
5. Schizas C, Michel J, Kosmopoulos V, Theumann N (2007) Computer tomography assessment of pedicle screw insertion in percutaneous posterior transpedicular stabilization. *Eur Spine J* 16: 613-617. [[Crossref](#)]
6. Krag MH, Weaver DL, Beynon BD, Haugh LD (1988) Morphometry of the thoracic and lumbar spine related to transpedicular screw placement for surgical spinal fixation. *Spine (Phila Pa 1976)* 13: 27-32. [[Crossref](#)]
7. Gertzbein SD, Robbins SE (1990) Accuracy of pedicular screw placement *in vivo*. *Spine (Phila Pa 1976)* 15: 11-14. [[Crossref](#)]
8. Gómez de la Riva A, Isla A, Pérez López C, Ortega R, Fernández-Miranda JC et al. (2006) Causes of reoperations in patients with lumbar spinal stenosis treated with instrumentations. *Neurocirugia (Astur)* 17: 232-239. [[Crossref](#)]
9. George DC, Krag MH, Johnson CC, Van Hal ME, Haugh LD et al. (1991) Hole preparation techniques for transpedicle screws. Effect on pull-out strength from human cadaveric vertebrae. *Spine (Phila Pa 1976)* 16: 181-184. [[Crossref](#)]
10. Frank EH, Chamberland DL (1997) An endoscopic pedicle probe: preliminary development. *Neurol Res* 19: 657-661. [[Crossref](#)]
11. Amiot LP, Lang K, Putzier M, Zippel H, Labelle H (2000) Comparative results between conventional and computer-assisted pedicle screw installation in the thoracic, lumbar, and sacral spine. *Spine (Phila Pa 1976)* 25: 606-614. [[Crossref](#)]
12. Laine T, Schlenzka D, Mäkitalo K, Tallroth K, Nolte LP et al. (1997) Improved accuracy of pedicle screw insertion with computer-assisted surgery. A prospective clinical trial of 30 patients. *Spine (Phila Pa 1976)* 22: 1254-1258. [[Crossref](#)]
13. Kim JM, Bowers AL, Chin KR (2007) Intraoperative Imaging Techniques in Spine Surgery. *J Spinal Disord Tech* 20: 78-86.
14. Amiot LP, Lang K, Putzier M, Zippel H, Labelle H (2000) Comparative results between conventional and computer-assisted pedicle screw installation in the thoracic, lumbar, and sacral spine. *Spine (Phila Pa 1976)* 25: 606-614. [[Crossref](#)]
15. Laine T, Lund T, Ylikoski M, Lohikoski J, Schlenzka D (2000) Accuracy of pedicle screw insertion with and without computer assistance: a randomised controlled clinical study in 100 consecutive patients. *Eur Spine J* 9: 235-240. [[Crossref](#)]
16. Jutte PC, Castelein RM (2002) Complications of pedicle screws in lumbar and lumbosacral fusions in 105 consecutive primary operations. *Eur Spine J* 11: 594-598. [[Crossref](#)]
17. Fu TS, Wong CB, Tsai TT, Liang YC, Chen LH et al. (2008) Pedicle screw insertion: computed tomography versus fluoroscopic image guidance. *Int Orthop* 32: 517-521. [[Crossref](#)]
18. Gruetzner PA, Waelti H, Vock B (2004) Navigation using fluoro-CT technology, concept and clinical experience in a new method for intraoperative navigation. *Eur J Trauma* 30: 161-170.
19. Nottmeier EW, Seemer W, Young PM (2009) Placement of thoracolumbar pedicle screws using three-dimensional image guidance: experience in a large patient cohort. *J Neurosurg Spine* 10: 33-39. [[Crossref](#)]
20. Merloz P, Troccaz J, Vouaillat H, Vasile C, Tonetti J et al. (2007) Fluoroscopy-based navigation system in spine surgery. *Proc Inst Mech Eng H* 221: 813-820. [[Crossref](#)]
21. Park P, Foley KT, Cowan JA, Marca FL (2010) Minimally invasive pedicle screw fixation utilizing O-arm fluoroscopy with computer-assisted navigation: Feasibility, technique, and preliminary results. *Surg Neurol Int* 1: 44. [[Crossref](#)]
22. Hott JS, Deshmukh VR, Klopfenstein JD, Sonntag VK, Dickman CA et al. (2004) Intraoperative Iso-C C-arm navigation in craniospinal surgery: the first 60 cases. *Neurosurgery* 54: 1131-1136. [[Crossref](#)]
23. Wendl K, von Recum J, Wentzensen A, Grütznier PA (2003) Iso-C(3D0-assisted) navigated implantation of pedicle screws in thoracic lumbar vertebrae. *Unfallchirurg* 106: 907-913. [[Crossref](#)]
24. Tian NF, Xu HZ (2009) Image-guided pedicle screw insertion accuracy: a meta-analysis. *Int Orthop* 33: 895-903. [[Crossref](#)]
25. Kendoff D, Citak M, Hufner T, Chaudhary S, Krettek C (2007) Current concepts and applications of computer navigation in orthopedic trauma surgery. *Central Eur J Med* 2: 392-403.
26. Verma R, Krishan S, Haendlmyer K, Mohsen A (2010) Functional outcome of computer-assisted spinal pedicle screw placement: a systematic review and meta-analysis of 23 studies including 5,992 pedicle screws. *Eur Spine J* 19: 370-375. [[Crossref](#)]
27. Quiñones Hinojosa A, Kolen ER, Jun P, Rosenberg WS, Weinstein PR (2006) Accuracy over space and time of computer-assisted fluoroscopic navigation in the lumbar spine *in vivo*. *J Spinal Disord Tech* 19: 109-113. [[Crossref](#)]
28. Florensa R, Muñoz J, Cardiel I, Bescós A, Tardáguila M et al. (2011) Posterior spinal instrumentation image guided and assisted by neuronavigation. Experience in 120 cases. *Neurocirugia (Astur)* 22: 224-234. [[Crossref](#)]
29. Gebhard FT, Kraus MD, Schneider E, Liener UC, Kinzl L et al. (2006) Does computer-assisted spine surgery reduce intraoperative radiation doses? *Spine (Phila Pa 1976)* 31: 2024-2027. [[Crossref](#)]
30. Slomczykowski M, Roberto M, Schneeberger P, Ozdoba C, Vock P (1999) Radiation dose for pedicle screw insertion. Fluoroscopic method versus computer-assisted surgery. *Spine (Phila Pa 1976)* 24: 975-982. [[Crossref](#)]