

Available online at www.sciencerepository.org

Science Repository



Case Report

Finding the Way Back Home: Report of 2 Cases of Oral Metastasis

Madhur Sharma^{1*}, Anjali Narwal², Anju Devi² and Mala Kamboj³

¹Post Graduate Student, Department of Oral maxillofacial Pathology and Microbiology, Pandit Bhagwat Dayal Sharma Post Graduate Institute of Medical Sciences, Rohtak, Haryana, India

²Professor, Department of Oral maxillofacial Pathology and Microbiology, Pandit Bhagwat Dayal Sharma Post Graduate Institute of Medical Sciences, Rohtak, Haryana, India

³Senior Professor & Head, Department of Oral maxillofacial Pathology and Microbiology, Pandit Bhagwat Dayal Sharma Post Graduate Institute of Medical Sciences, Rohtak, Haryana, India

ARTICLE INFO

Article history:

Received: 5 June, 2023

Accepted: 6 July, 2023

Published: 28 July, 2023

Keywords:

Metastasis

prostate adenocarcinoma

adenoid cystic carcinoma

lung metastasis

ABSTRACT

Around 1-1.5 % of all malignant tumors in oral cavity are caused by metastatic dissemination to this region. Lung, kidney, breast, bone and colorectal regions are primary sites which act as source of metastases to oral cavity. Similarly, metastasis from primary oral malignancy to distant sites is not uncommon with metastasis mainly occurring to lung, followed by bone and liver. Here we report 2 cases showing different primary origins but presentation in oral cavity being the first symptom. One case is of an 82 year old male with a complaint of swelling in right mandible and a diagnosis of prostatic adenocarcinoma metastasizing to oral cavity was established. The other case presented here is of a 42 year old male with pain and swelling in right mandible. The diagnosis of adenoid cystic carcinoma was made and a full body scan helped in early identification of metastatic deposits in lung. Despite the infrequent occurrence of metastases in oral region, dental surgeon should be aware of the possibilities for correct diagnostic conduction and subsequently, the initiation of treatment in early stages of disease.

© 2023 Madhur Sharma. Hosting by Science Repository.

Introduction

Metastatic lesions in the oral cavity are a rarity and comprise only 1-1.5% of all oral malignant tumors. The primary sites which metastasize to the oral cavity include breast, lung, prostate and kidney in decreasing order of incidence [1]. Since it is a bidirectional phenomenon the metastatic sites most favoured by carcinomas from oral cavity are mainly lung, followed by bone and liver [2]. One of serious concerns about malignant tumors is their ability to metastasize, whereby the tumor cells detach from the primary tumor and invade adjacent tissues and enter the lymphatics or vascular compartment before getting lodged at a distant site. According to the 'seed and soil' hypothesis, it has been suggested that metastasizing tumor cells (seed) grow in an organ that provides a suitable environment (soil) [3].

The metastatic lesions could occur either in soft or osseous tissues or both. The symptoms of a metastatic tumor to the jaw from any distant organ could mimic other oral malignancies, thus it becomes difficult to diagnose them clinically which affects its overall survival [4]. In certain conditions the unknown or an occult primary is detected and diagnosed on its secondary site after metastasis, making the diagnosis both delayed as well as challenging. Keeping the gravity of the situation in mind, we present one case diagnosed as prostate carcinoma from its metastatic deposits in the mandible and the other one of adenoid cystic carcinoma of the oral cavity with multiple metastatic deposits in lung.

Case Report 1

In the current report we describe case of an eighty-two-year-old male with no comorbidities and systemic illness who presented with a complaint of painful swelling in the right lower jaw region for past three

*Correspondence to: Dr. Madhur Sharma, Post Graduate Student, Department of Oral maxillofacial Pathology and Microbiology, Pandit Bhagwat Dayal Sharma Post Graduate Institute of Medical Sciences, Rohtak, 124001 Haryana, India; ORCID: 0000-0002-5570-1686; Tel: +919711123449; E-mail: madhurbhardwaj12@gmail.com

months. Clinical examination revealed a diffuse extra oral swelling of approximate size 5×4 centimetres involving the right mandibular angle region which was firm but tender on palpation (Figure 1A). The ipsilateral submandibular lymph nodes were found hard and tender on palpation. Intraoral examination showed edentulous arches with expansion of buccal and lingual cortex with overlying normal mucosa. Additional investigation by orthopantomogram revealed a mixed radiolucent-radiopaque lesion in posterior mandibular angle with sun ray appearance towards lower border of mandible (Figure 1B). A provisional

diagnosis of osteosarcoma was considered with other malignant lesions as differential diagnoses. Histopathological examination after an incisional biopsy revealed numerous pleomorphic hyperchromatic tumor cells arranged singly as well as in small clusters scattered within the connective tissue (Figures 1C & 1D). On immunohistochemistry, these tumor cells showed diffuse strong positivity for prostate specific antigen (PSA) and focal strong positivity for NKX3.1 (Figure 1E & 1F). A final diagnosis of metastatic prostate adenocarcinoma was rendered and the patient was referred for primary tumor assessment.

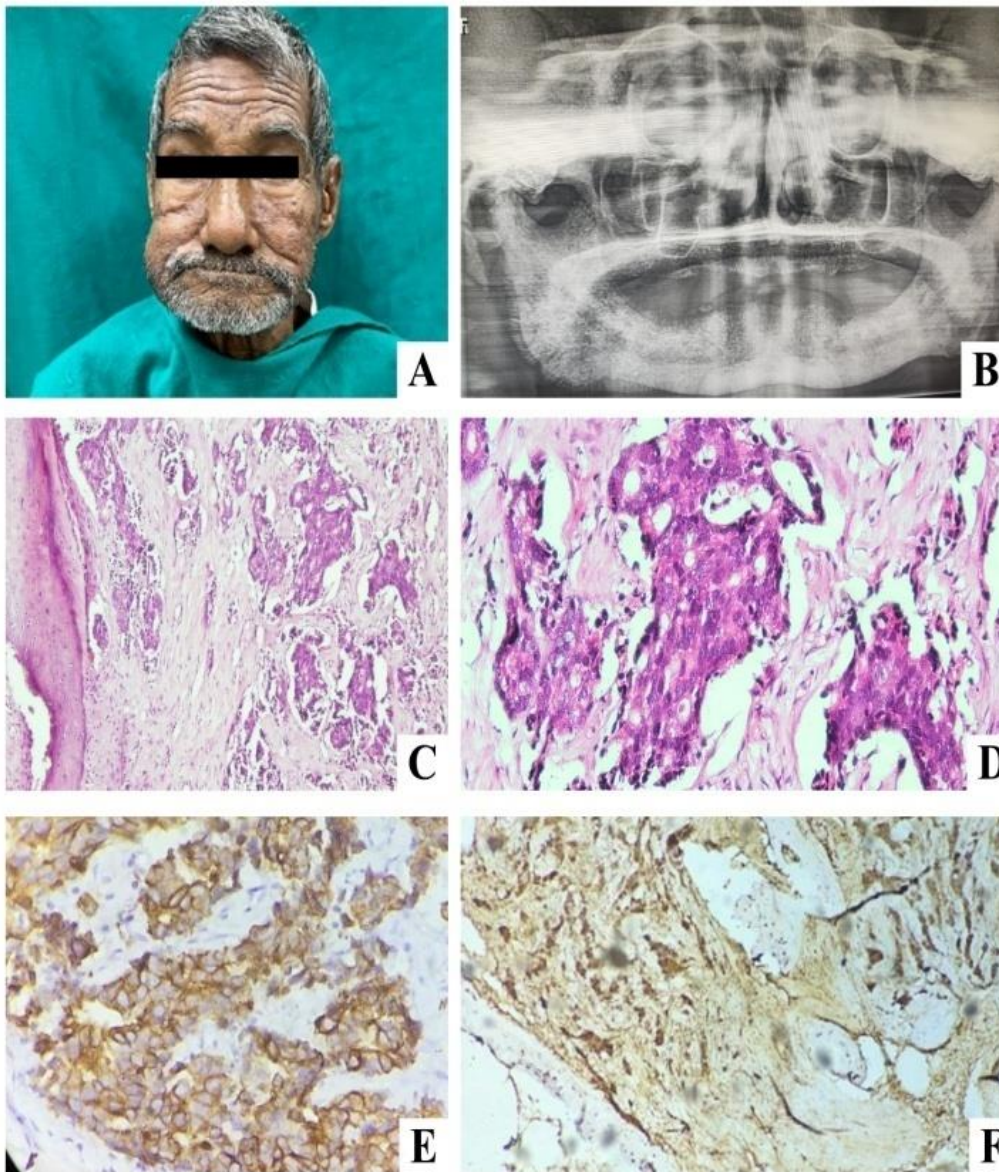


Figure 1: A) Patient with facial asymmetry due to swelling in right mandible. B) Orthopantomogram showing sun burst appearance in right mandibular angle region. C & D) Histopathological findings revealing osteoblastic reaction and tumor cells (4x H & E and 10x H & E). E & F) Immunohistochemistry showing positivity for PSA and NKX 3.1.

The serum prostate specific antigen values were found to be more than 146 ng/mL which indicated a primary prostatic adenocarcinoma. The true cut biopsy from prostate confirmed the diagnosis with a gleason score 8. Subsequently, the patient was put on chemotherapy; however, he succumbed to the disease within four weeks of treatment.

Case Report 2

The second case is of a forty-two-year-old male with a chief complaint of painful swelling in right mandible from past six months, with a habit of chronic smoking for 15 years, with no co morbidities or systemic illness. Clinical examination revealed a diffuse, soft and tender swelling

of approximate size 3 × 4 centimetres, in region of right angle of mandible (Figure 2A). On intraoral examination, right mandibular teeth were tender on percussion and vestibular obliteration was seen. The radiographic findings were not contributory (Figure 2B). Fine needle aspiration cytology revealed oval to round tumor cells with scanty

cytoplasm scattered singly and also arranged in the form of strands and sheets. Eosinophilic globular material seemed to be secreted by these tumor cells in their close vicinity. The findings were indicative of a salivary gland neoplasm.

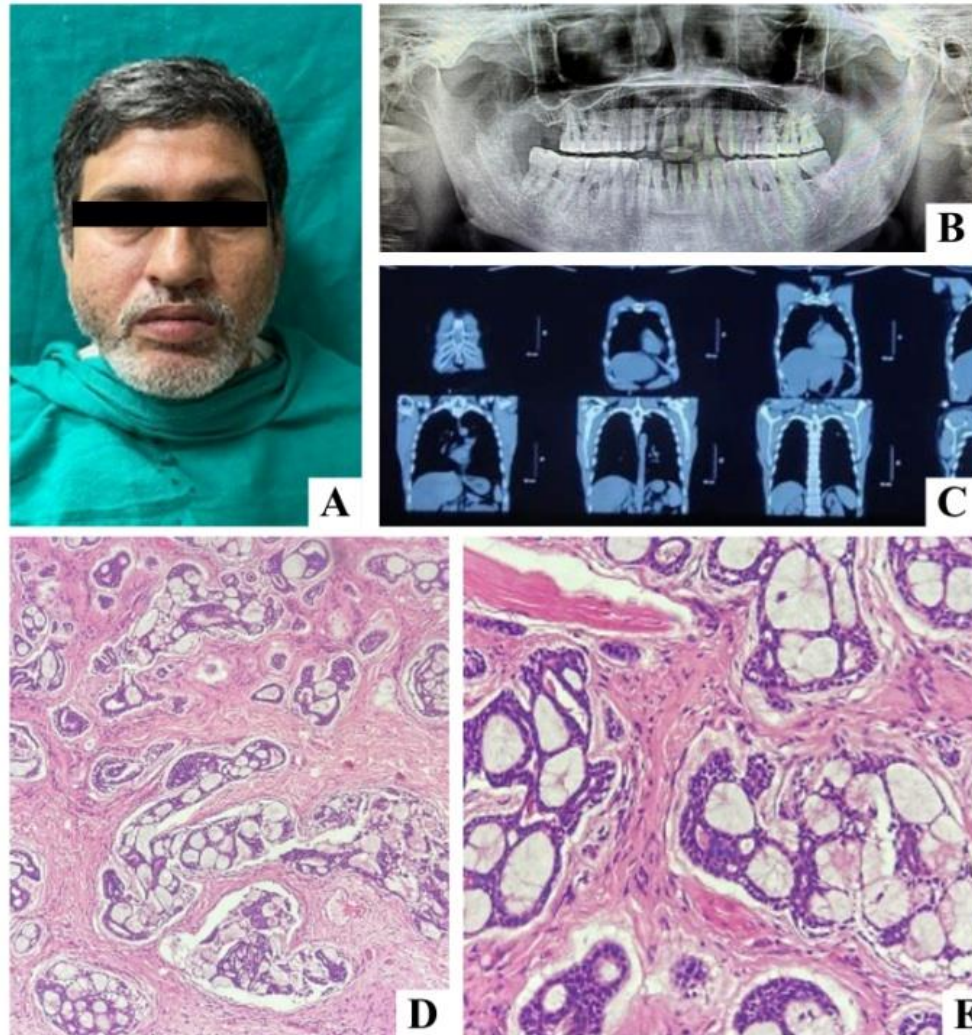


Figure 2: A) Patient with diffuse swelling on right mandible region, B) OPG revealing normal bony architecture. C) Lung opacities seen on HRCT. D & E) Histopathological view showing cribriform arrangement in adenoid cystic carcinoma (4x H & E and 10x H & E).

Incisional biopsy from right buccal mucosa and retromolar region, revealed overlying parenchymal squamous epithelium with adjacent connective tissue stroma showing presence of sebaceous glands and focal lymphoplasmacytic infiltrate (Figures 2D & 2E). The deeper areas of connective tissue showed hyperchromatic basaloid cells arranged in the form of a duct like pattern giving a swiss cheese appearance. The findings were consistent with a diagnosis of adenoid cystic carcinoma (ACC).

Owing to the high metastatic rates of ACC, a positron emission tomography (PET) scan was advised, which revealed multiple discrete parenchymal nodular opacities involving bilateral lung fields, likely metastatic deposits which was also confirmed by high resolution computed tomography (HRCT) (Figure 2C). The patient underwent radiotherapy and has been kept on regular follow-up.

Discussion

Metastatic lesions to the oral cavity are exceedingly difficult to diagnose based on their initial clinical presentations. The mandibular molar region is the most prevalent site for a hematogenous metastasis. A rich vascular supply and active areas of haematopoiesis is thought to provide adequate oxygen rich environment for the tumor growth. It could be challenging to distinguish between a distant metastasis, recurrence of a disease, or metastatic lesion of an undiscovered primary malignancy due to the vast clinical spectrum as they may resemble common odontogenic and non-odontogenic lesions of the jaws [4].

According to literature, prostate cancer metastasis is more likely to occur in the jawbones preferably mandible than the soft tissues [5]. Higher levels of growth factors like platelet derived growth factor, insulin like

growth factor, osteoprotegerin, bone morphogenetic protein, transforming growth factor-beta and vascular endothelial growth factor promote tumor cell proliferation and cause changes in normal bone architecture which are responsible for metastasis [6]. Patients with metastatic lesions often present with complaints of jaw pain, exophytic lesion and numbness. Similar findings were present in our case except the lack of paraesthesia or numb chin syndrome as reported in the past [3, 4]. In a study by Hirshberg *et al.*, oral findings were the first sign of metastatic disease in 23% of the reported cases [7]. Cases which showed oral lesions as the first presentation of the disease without any symptoms of underlying malignancy, mandate a thorough medical history followed by quick multidisciplinary approach for treatment in order to improve the survival rate.

In the second scenario the primary adenoid cystic carcinoma of minor salivary gland in retromolar region of mouth was diagnosed after the occurrence of its multiple metastatic lung deposits. The primary site showed no evident clinical features but a very small ambiguous swelling in cheek. Adenoid cystic carcinoma is a tumor with a remarkable propensity for recurrence that grows slowly but is highly malignant [8]. The slow but constant growth, numerous local recurrences, and hematogenous dissemination, primarily to the lung, liver, bone, and brain, are characteristics of ACC's natural history [8]. The risk factors for lung metastasis include tumor size, perineural invasion and local recurrence [2]. Lung metastasis in ACC is usually asymptomatic for a long time and a size more than 2.5 centimetres has been identified as a risk factor for metastasis [2, 9]. In the present case, the clinical presentation was similar to that reported in literature except lack of paresthesia [2, 8, 9]. The size of tumor combined with metastatic nature of ACC prompted us to get a full body PET scan for the patient, which revealed pulmonary deposits in an otherwise asymptomatic patient.

Early distant metastasis is usually attributed to a solid type of ACC and literature states that lung metastasis may occur as late as thirty years post treatment of the primary, thus, an unlimited follow-up is desirable throughout life [10]. In contrast, the present case showed early metastases, within six months, pointing towards the aggressive nature of ACC and its propensity to rapidly spread to distant sites. The mean survival times after lung metastasis and other metastases were 32.3 months and 20.6 months, respectively as reported by Van der Wal *et al.* [11]. In our case, early identification of lung deposits aided in quick beginning of the treatment protocol and currently patient is asymptomatic and has been kept on a regular follow up for two years. Thus, it is imperative to advise a thorough body scan to rule out metastatic deposits at the time of initial presentation for timely management of the patient as such lesions are life threatening.

Conclusion

Each reported case opens a new perspective and is a reminder of how grave are these metastatic tumors. For the oral pathologist, faced with suspected metastatic tumor, thorough immunohistochemical workup, occasionally supplemented by molecular tests, are required to define the origin of primary tumor. Dental surgeons should also be vigilant to

establish an early diagnosis for the administration of therapy in the early stages of the disease and increase the chances of survival.

Funding

None.

Acknowledgements

None.

Conflicts of Interest

None.

REFERENCES

- Lombardo EM, Ponce K, Tregnago L, Pagnoncelli RM, Heitz C et al. (2020) Metastasis of Prostate Adenocarcinoma in the Mandible: Rare Occurrence in Maxillary Bones. *J Craniofac Surg* 31: e75-e78. [[Crossref](#)]
- Ohta K, Matsuda S, Okada A, Sasaki M, Imamura Y et al. (2021) Adenoid cystic carcinoma of the sublingual gland developing lung metastasis 20 years after primary treatment: A case report and literature review. *Medicine (Baltimore)* 100: e28098. [[Crossref](#)]
- Khalid R, Ramanathan A, Lun HT, Lim D (2022) Aberrant Expression of p63 in an Adenocarcinoma of the Prostate That Has Metastasized to the Oral Cavity. *Cureus* 14: e22753. [[Crossref](#)]
- Ahuja US, Shetty DC, Rathore A, Dhillon M (2021) Occult prostate carcinoma with metastasis to the mandible presenting as numb chin syndrome. *J Oral Biol Craniofac Res* 11: 393-395. [[Crossref](#)]
- Clausen F, Poulsen H (1963) METASTATIC CARCINOMA OF THE JAWS. *Acta Pathol Microbiol Scand* 57: 361-374. [[Crossref](#)]
- Srichinthu KK, Raveendran AP, Tamilthangam P, Joe J, Duraisamy C et al. (2017) Molecular Pathogenesis and Diagnostic Imaging of Metastatic Jaw Tumors. *J Pharm Bioallied Sci* 9(Suppl 1): S15-S22. [[Crossref](#)]
- Hirshberg A, Berger R, Allon I, Kaplan I (2014) Metastatic tumors to the jaws and mouth. *Head Neck Pathol* 8: 463-474. [[Crossref](#)]
- Savithri V, Suresh R, Janardhanan M, Aravind T, Mohan M (2021) Primary Intraosseous Adenoid Cystic Carcinoma with Widespread Skeletal Metastases Showing Features of High-Grade Transformation. *Head Neck Pathol* 15: 715-722. [[Crossref](#)]
- Seok J, Lee DY, Kim WS, Jeong WJ, Chung EJ et al. (2019) Lung metastasis in adenoid cystic carcinoma of the head and neck. *Head Neck* 41: 3976-3983. [[Crossref](#)]
- Ishida E, Ogawa T, Rokugo M, Ishikawa T, Wakamori S et al. (2020) Management of adenoid cystic carcinoma of the head and neck: a single-institute study with over 25-year follow-up. *Head Face Med* 16: 14. [[Crossref](#)]
- Van der Wal JE, Becking AG, Snow GB, van der Waal I (2002) Distant metastases of adenoid cystic carcinoma of the salivary glands and the value of diagnostic examinations during follow-up. *Head Neck* 24: 779-783. [[Crossref](#)]