

Available online at [www.sciencerepository.org](http://www.sciencerepository.org)

Science Repository



## Case Report

# Giant Hematoma of Rectus Abdominis Muscle in a Patient with Schistosomiasis without Periportal Abnormalities

Alexandre Sacchetti Bezerra<sup>1\*</sup>, Walter Moisés Tobias Braga<sup>2</sup>, Raphaela Ferrari<sup>3</sup>, Rafi Felício Bauab Dauar<sup>4</sup>, Heitor Andrei Miranda de Carvalho<sup>5</sup> and Rodrigo Delfino Nascimento<sup>6</sup>

<sup>1</sup>Vascular Surgery, Instituto de Infectologia Emilio Ribas, São Paulo, Brazil

<sup>2</sup>Hematologia, Universidade Federal de São Paulo, São Paulo, Brazil

<sup>3</sup>Infectology, Instituto de Infectologia Emilio Ribas, São Paulo, Brazil

<sup>4</sup>Neurosurgery, Rede Dor, São Paulo, Brazil

<sup>5</sup>Vascular Surgery, Instituto de Radiologia HCFMUSP (InRad), São Paulo, Brazil

<sup>6</sup>Radiology, Hospital Universitário da Faculdade de Medicina da Universidade de São Paulo, São Paulo, Brazil

### ARTICLE INFO

#### Article history:

Received: 9 January, 2023

Accepted: 30 January, 2023

Published: 6 February, 2023

#### Keywords:

*Schistosomiasis mansoni*

*rectus abdominis*

*platelet function tests*

*shock*

*hemorrhagic*

### ABSTRACT

A 60-year-old patient came to the IIER due to abdominal pain for 2 days, associated with flu with cough. The patient treated schistosomiasis twice without effects. During physical examination and complementary exams, she presented ecchymosis in the midline of the abdomen, normal platelet level, giant hematoma in the rectus abdominis muscle without periportal changes. A careful retrospective analysis shows inconsistency between the initial platelet levels and the severe progression of the clinical. The investigation and confirmation of thrombocytopenia is very important, and some medical center recommend manual counting through blood smears. Prospective studies are needed to know how platelet measurements should be performed in schistosomiasis.

© 2023 Alexandre Sacchetti Bezerra. Hosting by Science Repository.

## Introduction

Rectus abdominis muscle hematoma (RSH: Rectus Sheath Hematoma) is defined as an accumulation of blood in the rectus muscle sheath from the rupture of one or more branches of the inferior epigastric artery (AEI) [1]. Except in cases of anatomical variation, the AEI appears as a branch of external iliac artery with the function of perfusing the rectus abdominis muscle (RAM) together with the superior epigastric artery that comes from the internal thoracic artery [1, 2]. The anatomical study of RSH shows absence of a posterior sheath in its distal third delimited by the arcuate line (AL). Proximal to the AL, the branches of AEI are fixed, which favours vascular injury due to movement of the distal portion of the RAM [2].

In addition of clinical signs and non-specific symptoms like abdominal pain and ecchymosis, patients with RSH present some particular characteristics, as shown in (Table 1) [1, 3]. Some epidemiological conditions, such as elderly women, can predispose the RSH. Table 2 presents some risk factors to RSH [4]. For a long time, the diagnosis of RSH has been performed through computerized tomography, allowing classification and to make a clinical decision to this condition in three stages (Table 3). This method cannot measure precisely the size of the hematoma [5, 6]. Most patients do not need surgical treatment, but those with stages II and III can present haemodynamic instability, requiring surgical intervention [7-9].

Differently from RSH, Schistosomiasis is an infectious disease defined by the presence of *Schistosoma* (parasitic worm) in the bloodstream [10-12]. It is believed that *Schistosoma mansoni* (SM) eggs secrete proteins

\*Correspondence to: Alexandre Sacchetti Bezerra, Vascular Surgery, Instituto de Infectologia Emilio Ribas, Av. Engenheiro Luiz Carlos Berrini 1748, cj 810, 1510, Cidade Monções, 04571000 São Paulo, Brazil; ORCID: 0000-0001-6870-7465; Tel: +551128936661, +551128936662; E-mail: a.bezerra@uol.com.br, dr.bezerra@einstein.br

causing an immune response (Th-1 e Th-2) in the host, leading to an eosinophilic granulomatous reaction [13, 14]. Although most patients are asymptomatic, (Table 4) shows important clinical features at different

stages of the disease caused by MS [10, 11]. Eradication of adult worms in the context of newly acquired schistosomiasis usually leads to complete remission of urinary and intestinal lesions [10, 11].

**Table 1:** Possible clinical manifestations of RSH.

Hypovolemic shock
Abdominal compartment syndrome
Carnett's sign
Fothergill's sign

**Table 2:** Risk factors to RSH.

Systemic arterial hypertension
Liver cirrhosis
Peripheral obstructive pulmonary disease
Pneumonia
Cough
Anticoagulant and antiplatelet drugs

**Table 3:** Classification of RSH.

TYPE	CLINICAL PRESENTATION	CONDUCT
I	Small, RAM-restricted hematoma	Outpatient treatment. Clinical conservative management;
II	Significant hematoma restricted to the RAM, can exceed the midline	Inpatient treatment. Clinical or surgical management
III	Major hematoma with the possibility of: -Haemoperitoneum -Hematoma in the space of Retzius -Hematoma below the arcuate line	Inpatient treatment. Clinical or surgical management

**Table 4:** Stages of Schistosomiasis by SM.

ACUTE PHASE	CHRONIC PHASE
KATAYAMA'S FEVER URTICARIA MYALGIA HEADACHE DIARRHEA EOSINOPHILIA (causing encephalitis without vasculitis)	ABDOMINAL PAIN INAPETENCE DIARRHEA IRON DEFICIENCY ANEMIA NO HEMATIC CHANGES (no eosinophilia) NORMAL TRANSAMINASES SYMMERS' FIBROSIS - occlusion of the portal vein (non-cirrhotic) by collagen deposition along the stellate cells of the periportal space SPLENOMEGALY SHUNT PORTO CAVA GLOMERULOPATHY (proteinuria with nephrotic syndrome)

## Case Report

Female patient, black, 60 years old, from an endemic area for Schistosomiasis came to the emergency room of Emilio Ribas Hospital (IER) complaining of severe abdominal pain for 1 day after severe coughing episode 2 days ago, associated with flu symptoms for 6 days. She denied headache, fever, nausea, diarrhea, constipation, urticaria or myalgia.

## I Previous Treatments

### i Schistosomiasis

Treated twice with Praziquantel (150 mg 8/8h) without medication side effects as abdominal pain, nausea, diarrhea, vomiting, dizziness, drowsiness, headaches and no increase in sweating.

### ii Asthma and Pulmonary Hypertension

Treated with Carvedilol (12.5 mg 12/12h), Furosemide (40 mg 24/24h) and Salbutamol (100 mcg 12/12h).

On physical examination, the patient was lucid, oriented and haemodynamically stable. Abdominal examination revealed ecchymosis in the midline of approximately 18 cm in extension not adhered to deep planes, without pulsatility or fremitus, with pain on superficial palpation, negative abrupt decompression, rectal examination without alterations such as melena, positive Carnett and Fothergill signs (Figure 1).

## II Laboratory Exams at the Time of Admission

Platelets: 114 mil/mm<sup>3</sup> (normal 150 - 450 mil/mm<sup>3</sup>)  
Eosinophil: 0.7% (normal: 1-5%)

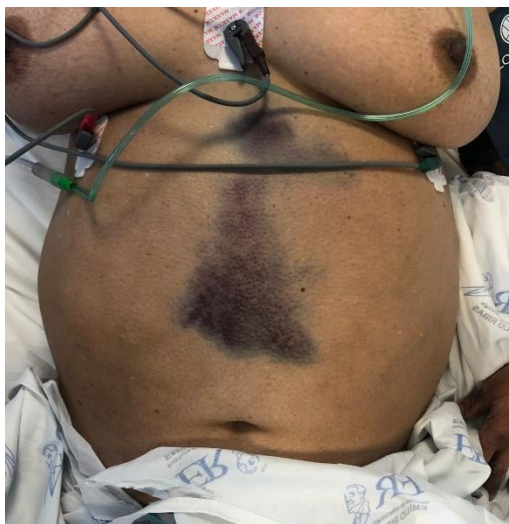AST: 40 U/L (normal < 31 U/L)

ALT: 53 U/L (normal < 45 U/L)

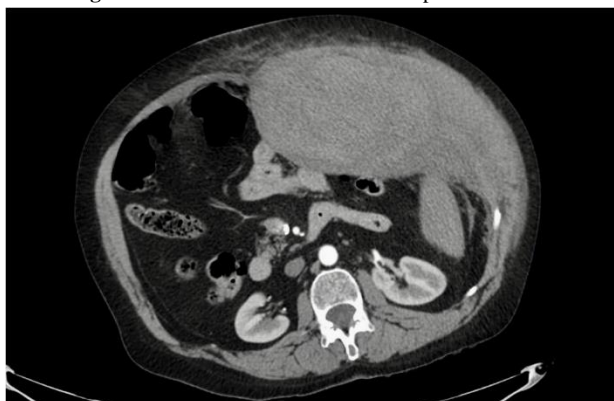Prothrombin time: 17.9 / AP: 56% (normal > 70%).

Abdominal ultrasonography demonstrated splenomegaly ( $14 \times 7.7$  cm) normal sized liver. Upper digestive endoscopy demonstrated esophageal

varices and esophageal candidiasis KODSI II. Patient refers endoscopic ligation eight years ago. Computed tomography (CT) of abdomen confirmed an extensive hematoma of the rectus abdominis muscle crossing the arcuate line and midline. Despite not having haemoperitoneum or blood in the pre-vesical space of Retzius, it was classified as RSH type III (Figure 2).



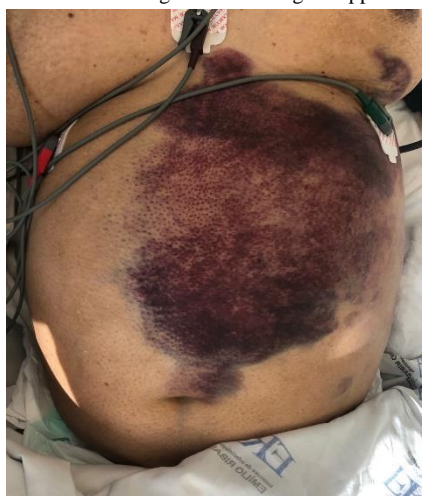**Figure 1:** Abdominal examination at hospital admission.



**Figure 2:** Axial image of abdominal tomography.

In 48 hours, the patient presented significant bleeding with changes in the static (Figure 3) and dynamic physical examinations, which showed haemodynamic instability due to significant volume loss while waiting

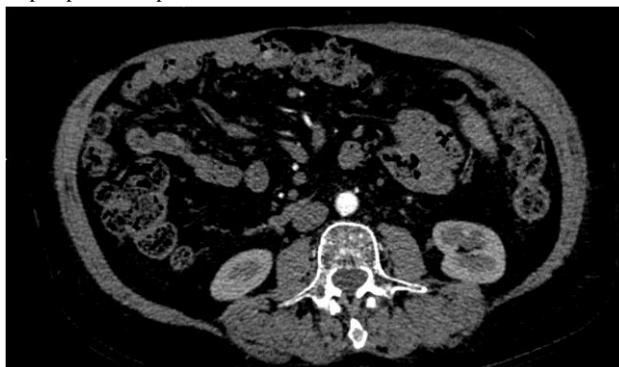for the procedure to be performed, evolving with hypovolemic shock, requiring vasoactive drug (noradrenaline 0,22mcg/Kg/min). Indicated surgical approach through armed arteriography.



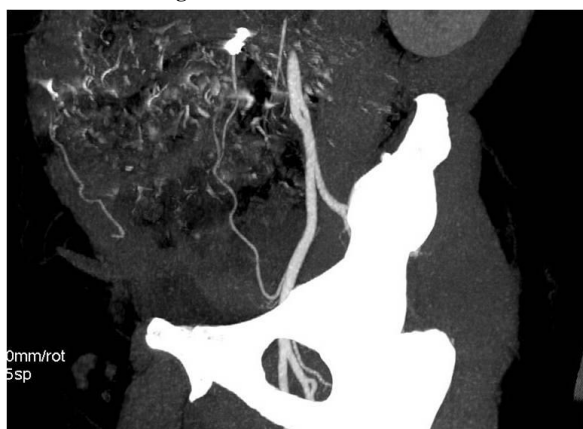
**Figure 3:** Expanding hematoma after 48 h.

During the surgical procedure, she was haemodynamically unstable, and embolization of the left inferior epigastric artery was performed using a 2.7F microcatheter and use of a 0.018 non-fibered coil. In 24 hours there was haemodynamic stabilization with norepinephrine suspension. The

patient remained at hospital for 16 days when he was discharged with significant resorption of the hematoma and no signs of infection. The patient had no hematoma after 10 months (Figures 4 & 5).



**Figure 4:** Absence of hematoma.



**Figure 5:** Angiotomography with the presence of a metallic coil in the arterial path.

## Discussion

In addition to the diseases traditionally known as etiologic diagnoses of acute abdomen, literature reviews of RSH establish a close link with spontaneous retroperitoneal hematomas (SRH), which range from coagulopathies to ruptured aortic aneurysm [15]. Patients with SRH also presents with nonspecific abdominal pain similar to RSH, but with other

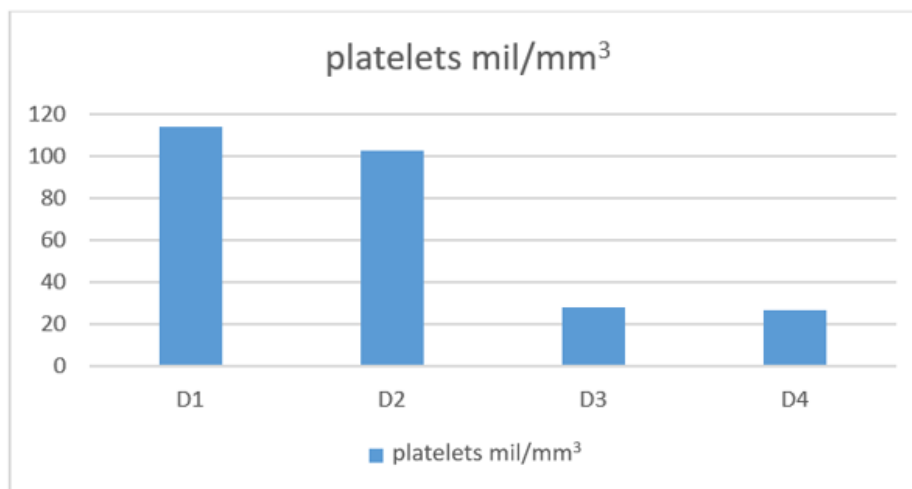
important clinical signs that should be investigated in patients with acute abdomen. (Table 5). Despite the ecchymosis shown in Figure 1, we did not observe the specific signs in (Table 5) in our physical exam. The reported case presented positive Carnett and Fothergill signs, which increased the specificity and sensitivity of the diagnostic hypothesis of RSH [1, 3].

**Table 5:** Specific clinical signs SRH.

SIGN	CHARACTERISTICS
Grey Turner	Flank ecchymosis
Cullen	Periumbilical ecchymosis
Stabler	Inguinal and/or pubic hematoma
Bryant	Ecchymosis in scrotum
Fox	Inguinal ecchymosis

Logically, all these cases of abdominal pain with suspected RSH should undergo computed tomography in order to eliminate the possibility of SRH. Table 2 lists the use of antiplatelet agents, anticoagulants or coagulation disorders as a possible etiology of RSH. The patient was not using these medications but had thrombocytopenia. The investigation and confirmation of thrombocytopenic conditions in MS is very important, and some services recommend manual counting through blood smears [16, 17].

Graph 1 demonstrates the importance of an efficient measurement of platelets in patients with SM. But it is important to confirm that the change in the correct platelet levels is not related to the stage or severity of the disease [17, 18]. In a sample of 187 patients, Medeiros *et al.* concluded that the level of serum platelets establishes an inverse relationship with the severity of portal fibrosis and with the diameter of the spleen [18, 19].



**Graph 1:** Platelets in the first four days of hospitalization.

In the case reported, the patient had significant thrombocytopenia with almost no changes on liver and spleen anatomy. Even in patients with Symmers fibrosis and who have periportal involvement, schistosomiasis does not make elevation of AST, ALT or coagulation disorders, which is consistent with the data obtained in the serum tests of the case presented [10, 11, 19]. Based on the physical examination and complementary history, it is evident that the cough associated with thrombocytopenia caused the RSH. Once the diagnosis and classification of RSH has been performed, as shown in (Table 3), doctors can choose between clinical or surgical treatment. In most cases, there is no indication for surgery even with radiological examinations characterizing type III RSH.

However, in the presence of patients with RSH with haemodynamic instability, surgical correction is imperative. The conventional surgical technique (open technique) has greater morbidity in addition to greater difficulty in resolving multiple foci of bleeding when present. Endovascular treatment with embolization is less morbid, especially in patients using vasoactive drugs, but does not allow removal of the hematoma, which, when presented in large dimensions, may not be reabsorbed by the body, and have a high potential for infection [20, 21]. Regardless of the choice of therapy in the presence of RSH it is mandatory that these patients have urgent diagnoses and have complications or recurrences identified promptly, keeping outpatient observation.

#### Funding

None.

#### Conflicts of Interest

None.

#### REFERENCES

- Hatjipetrou A, Anyfantakis D, Kastanakis M (2015) Rectus sheath hematoma: a review of the literature. *Int J Surg* 13: 267-271. [Crossref]
- Mwachaka PM, Saidi HS, Odula PO, Awori KO, Kaisha WO (2010) Locating the arcuate line of Douglas: is it of surgical relevance? *Clin Anat* 23: 84-86. [Crossref]
- Schneiderman H, Lopetegui Lia N, Nichols J (2020) The Enduring and Practical Power of Physical Examination: Carnett Sign. *Am J Med* 133: 682-684. [Crossref]
- Kasotakis G (2014) Retroperitoneal and rectus sheath hematomas. *Surg Clin North Am* 94: 71-76. [Crossref]
- Berná JD, García Medina V, Guirao J, García Medina J (1996) Rectus sheath hematoma: diagnostic classification by CT. *Abdom Imaging* 21: 62-64. [Crossref]
- Bello G, Blanco P (2019) Giant rectus sheath hematoma. *Ultrasound J* 11: 13. [Crossref]
- Warren MH, Bhattacharya B, Maung AA, Davis KA (2020) Contemporary management of spontaneous retroperitoneal and rectus sheath hematomas. *Am J Surg* 219: 707-710. [Crossref]
- Baekgaard JS, Eskesen TG, Lee JM, Yeh DD, Kaafarani HMA et al. (2019) Spontaneous Retroperitoneal and Rectus Sheath Hemorrhage-Management, Risk Factors and Outcomes. *World J Surg* 43: 1890-1897. [Crossref]
- Rimola J, Perendreu J, Falcó J, Fortuño JR, Massuet A et al. (2007) Percutaneous arterial embolization in the management of rectus sheath hematoma. *AJR Am J Roentgenol* 188: W497-W502. [Crossref]
- Léger E, Borlase A, Fall CB, Diouf ND, Diop SD et al. (2020) Prevalence and distribution of schistosomiasis in human, livestock, and snail populations in northern Senegal: a One Health epidemiological study of a multi-host system. *Lancet Planet Health* 4: e330-e342. [Crossref]
- Kamdem SD, Moyou Somo R, Brombacher F, Nono JK (2018) Host Regulators of Liver Fibrosis During Human Schistosomiasis. *Front Immunol* 9: 2781. [Crossref]
- Carson JP, Ramm GA, Robinson MW, McManus DP, Gobert GN (2018) Schistosome-Induced Fibrotic Disease: The Role of Hepatic Stellate Cells. *Trends Parasitol* 34: 524-540. [Crossref]
- Coutinho HM, Acosta LP, Wu HW, McGarvey ST, Su L et al. (2007) Th2 cytokines are associated with persistent hepatic fibrosis in human *Schistosoma japonicum* infection. *J Infect Dis* 195: 288-295. [Crossref]
- Kullberg MC, Pearce EJ, Hieny SE, Sher A, Berzofsky JA (1992) Infection with *Schistosoma mansoni* alters Th1/Th2 cytokine responses to a non-parasite antigen. *J Immunol* 148: 3264-3270. [Crossref]

15. Sahu KK, Mishra AK, Lal A, George SV, Siddiqui AD (2020) Clinical spectrum, risk factors, management and outcome of patients with retroperitoneal hematoma: a retrospective analysis of 3-year experience. *Expert Rev Hematol* 13: 545-555. [[Crossref](#)]
16. Çolakoğlu MK, Özdemir A, Kalcan S, Demir A, Demiral G et al. (2020) Spontaneous abdomen and abdominal wall hematomas due to anticoagulant/antiplatelet use: Surgeons' perspective in a single center. *Ulus Travma Acil Cerrahi Derg* 26: 50-54. [[Crossref](#)]
17. Vaz de Melo Trindade G, Pereira TA, Caporali JFM, Vaz de Melo Trindade D, Roriz SJ et al. (2021) EDTA-dependent pseudothrombocytopenia in patients with hepatosplenic schistosomiasis mansoni: a clinical management alert. *Trans R Soc Trop Med Hyg* 115: 1168-1173. [[Crossref](#)]
18. Medeiros TB, Domingues AL, Luna CF, Lopes EP (2014) Correlation between platelet count and both liver fibrosis and spleen diameter in patients with schistosomiasis mansoni. *Arq Gastroenterol* 51: 34-38. [[Crossref](#)]
19. Camacho Lobato L, Borges DR (1998) Early liver dysfunction in schistosomiasis. *J Hepatol* 29: 233-240. [[Crossref](#)]
20. Pieri S, Agresti P, Buquicchio GL, Di Giampietro I, Trinci M et al. (2015) Endovascular management of the rectus muscle hematoma. *Radiol Med* 120: 951-958. [[Crossref](#)]
21. Albuquerque TVC, Monsignore LM, de Castro Afonso LH, Elias Junior J, Muglia VF et al. (2020) Transarterial embolization with n-butyl cyanoacrylate for the treatment of abdominal wall hemorrhage. *Diagn Interv Radiol* 26: 216-222. [[Crossref](#)]