

Available online at www.sciencerepository.org

Science Repository



Case Report and Review of the Literature

Non-Hemorrhagic Pericardial Effusion in Penetrating Thoracic Trauma from Incidental Coxsackie B Virus

Kathryn M. Haberman^{1*}, Pamela L. Souders¹, Joyce L. Sanchez², Jill C. R. Streams³ and Christopher S. Davis¹

¹Department of Surgery, Division of Trauma and Acute Care Surgery, Medical College of Wisconsin, Wisconsin, USA

²Department of Medicine, Division of Infectious Diseases, Medical College of Wisconsin, Wisconsin, USA

³Department of Surgery, Division of Acute Care Surgery, Vanderbilt University Medical Center, Tennessee, USA

ARTICLE INFO

Article history:

Received: 2 June, 2022

Accepted: 17 June, 2022

Published: 30 June, 2022

Keywords:

Non-hemorrhagic pericardial effusion
serous pericardial effusion
penetrating thoracic trauma
penetrating cardiac injury
pericardial window
Coxsackie B virus

ABSTRACT

Cardiac ultrasound is an integral part of the assessment and evaluation of penetrating thoracic trauma. Positive findings of pericardial fluid are an indication for subxiphoid pericardial window and/or sternotomy. Little has been published regarding non-hemorrhagic pericardial effusions in the setting of penetrating thoracic trauma. We present the first reported case of non-hemorrhagic pericardial effusion following a thoracic gunshot wound (GSW) incidentally caused by Coxsackie B virus and discuss our review of the literature. A 19-year-old male presented to the Emergency Department following GSWs to the face, hand, and thorax. The patient was hemodynamically normal; however, a pericardial effusion was noted on cardiac ultrasound, as was a large left-sided hemothorax. The patient was brought emergently to the operating room where a pericardial window demonstrated a large, non-hemorrhagic pericardial effusion. Laboratory analysis was consistent with current Coxsackie B viral infection. All other evaluations returned negative. As there are no guidelines for this population, we propose guidelines for the work-up of non-hemorrhagic pericardial effusion in the setting of penetrating thoracic trauma. We also discuss the safety and efficacy of a pericardial window in a hemodynamically normal patient with concern for hemopericardium prior to performing a median sternotomy.

© 2022 Kathryn M. Haberman. Hosting by Science Repository.

Introduction

The majority of patients who sustain a penetrating cardiac injury die prior to hospital presentation, though survival has improved with recent advancements in emergency medical services [1, 2]. Of those who do arrive in the Emergency Department (ED), there is a wide variation in clinical presentation: from asymptomatic to extremis.

Up to 80% of cardiac stab wounds result in pericardial tamponade [3]. However, the clinical diagnosis of impending cardiac tamponade is difficult given the noisy and busy environment of the trauma bay. Additionally, Beck's Triad is found in only one third of patients. Thus, cardiac ultrasound is an integral part of the assessment and evaluation of penetrating thoracic trauma. In a trained surgeon's hand, the sensitivity and specificity of diagnosing a pericardial effusion approaches 100% [4-

6]. It must be noted, however, that sensitivity diminishes in the setting of left-sided hemothorax, when violation of the pericardium can decompress blood from an underlying cardiac injury into the left hemithorax.

Little has been published regarding the presence of a non-hemorrhagic pericardial effusion in penetrating thoracic trauma, and its incidence in this setting is unknown. Mitiku and Heidenreich noted incidental small pericardial effusions in 5.7% of the general population undergoing echocardiography for reasons unrelated to evaluation of pericardium or cardiac surgery [7]. Most studies evaluating cardiac ultrasound in the setting of penetrating thoracic trauma do not describe the incidental effusion. Of those that do describe the fluid, the incidence of serous fluid ranges from 0-9% (Table 1).

*Correspondence to: Dr. Kathryn M. Haberman, M.D., Department of Surgery, Division of Trauma and Acute Care Surgery, Medical College of Wisconsin, 8701 W. Watertown Plank Road, Wauwatosa, Wisconsin 53226, USA; E-mail: khberman@mcw.edu

Table 1: Diagnosis of pericardial effusion following penetrating thoracic trauma.

Study	Design	Patients with penetrating thoracic injury (n)	Cardiac Injuries confirmed at surgery (n)	Sensitivity (%)	Specificity (%)	False negative (n)	False positive (n)	Serous Fluid Noted (n)
Ma <i>et al.</i> ('95) [16]	Prospective single center	245	6	100	99	0	1	NR
Meyer <i>et al.</i> ('95) [20]	Prospective single center	105	9	56	93	0	8	0
Nagy <i>et al.</i> ('95) [19]	Retrospective single center	121	12	96.8	100	0	15	11
Rozycki <i>et al.</i> ('96) [4]	Prospective single center	347	11	100	100	0	0	NR
Rozycki <i>et al.</i> ('98) [5]	Prospective single center	313	22	100	99	0	2	0
Rozycki <i>et al.</i> ('99) [6]	Prospective multicenter	261	29	100	97	0	7	6
Bokhari <i>et al.</i> ('04) [17]	Prospective single center	49	NR	100	50	0	20	NR
Tayal <i>et al.</i> ('04) [18]	Prospective single center	32	8	100	100	0	0	NR
Nichol <i>et al.</i> ('15) [14]	Prospective single center	172	135	86.7	NR	18	35	NR

NR: Not Recorded.

The differential diagnosis for a serous/non-hemorrhagic pericardial effusion is quite extensive. While most pericardial effusions are idiopathic (incidence ranging 7-48%) a large proportion of effusions are secondary to infection (6-28%) and malignancy (13-38%). Additionally, uremia, collagen vascular disease, and hypothyroidism account for 2-12%, 3-12%, and 0-10% respectively [8-11]. While many do not require intervention, the diagnosis of the underlying etiology can be important for further workup and treatment, particularly in the setting of human immunodeficiency virus (HIV) or malignancy, for example.

Case Presentation

A previously healthy 19-year-old male was brought to the ED after he sustained gunshot wounds to the face, hand, and left thorax. On presentation to the trauma bay his airway, breathing, and circulation were intact, and the patient’s vitals were within normal limits and stable on room air. A chest radiograph demonstrated a left-sided hemothorax and a ballistic missile abutting the patient’s spine near T10-11 (Figure 1). Cardiac ultrasound revealed a large pericardial effusion (Figure 2). A chest tube was placed with return of frank blood, and the patient was taken to the operating room.

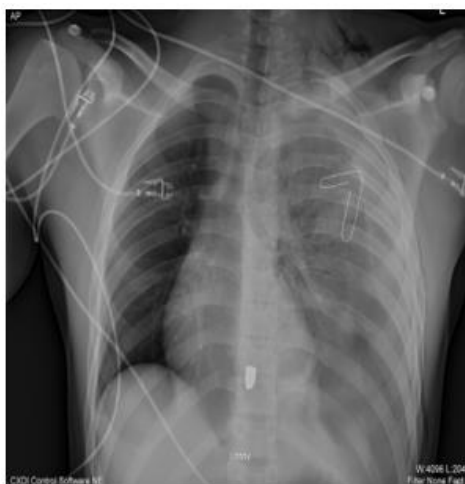

Figure 1: Chest radiograph prior to chest tube placement, notable for presumed entrance site at tip of paper clip, retained missile at T10, and left-sided hemothorax.

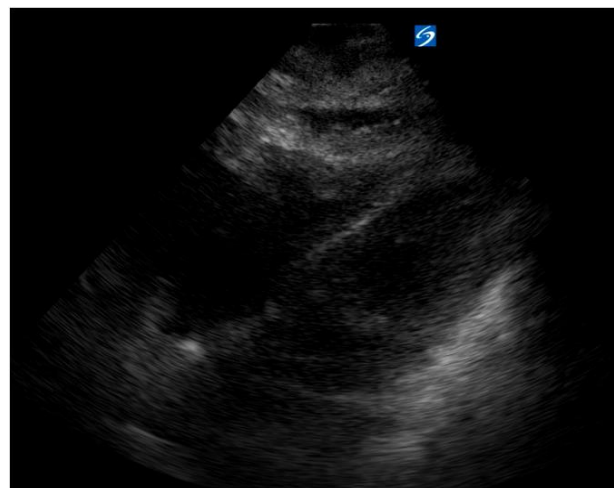


Figure 2: Pericardial effusion seen by ultrasound. Representative sub-xiphoid cardiac view, courtesy of Tom Carver, MD, as our case’s images never saved.

Given the patient’s hemodynamic stability and tolerance of anaesthetic induction, we proceeded with a sub-xiphoid pericardial window. Upon incising the pericardium, there was a large gush of straw-coloured serous fluid, measuring roughly 150-200 cc. The pericardium was irrigated and the effluent remained clear. A pericardial drain was placed, and the patient was transferred to the Surgical Intensive Care Unit (SICU) for recovery. Bronchoscopy and endoscopy to evaluate the patient’s trachea and esophagus were negative for injury. Cardiology consultation was obtained to investigate the etiology of the pericardial effusion initiating the following evaluation: electrocardiogram (ECG), transthoracic echocardiogram (TTE), pericardial fluid analysis, and serum tests for coxsackie virus, human immunodeficiency virus (HIV), and thyroid-stimulating hormone (TSH).

The ECG, which was obtained after the pericardial window, demonstrated ST elevation and PR segment elevation in lead aVR consistent with pericarditis. Unfortunately, we had no pre-operative ECGs to exclude pre-existing inflammation. Fluid from continued drainage was sent for aerobic, anaerobic and fungal cultures and were negative. The etiology of the pericardial fluid was not considered to be

traumatic due to its characteristics, colour, and immediacy to the time of trauma itself. Serum sent for TSH and HIV was normal. The coxsackie antibody panel was positive for serum Coxsackie B-2 antibody titer $\geq 1:80$, which was indicative of a past or current infection. Based on these preliminary results, colchicine was prescribed for 3 months due to its anti-inflammatory properties via inhibition of the tubulin polymerization pathway [12]. A TTE was completed on hospital day (HD) 2 which revealed a normal left ventricle with normal systolic/diastolic function, normal right ventricle size and systolic function, and no pericardial effusion. The pericardial drain was removed on HD 4 without complications. Repeat Coxsackie virus titers 4 weeks later revealed coxsackie B-2, B-3, and B-5 antibody titers all $\geq 1:80$. This confirmed the diagnosis of a current/recent coxsackie B infection. Further detailed history revealed that the patient’s mother had recently suffered an upper respiratory infection.

Discussion

We present the first reported case of a pericardial effusion secondary to coxsackie B virus in the setting of penetrating thoracic trauma. Most coxsackie infections are generally mild with minimal symptoms, manifesting as the “common cold”, rash, or sore throat. The cost of a missed diagnosis of Coxsackie B virus is essentially negligible, as care is supportive. However, the consequences of missing a diagnosis such as HIV, bacterial pericarditis, tuberculosis, hypothyroidism, or malignancy is much greater. It is important to remember to evaluate for these medical diagnoses, particularly as many trauma patients are not followed closely in the healthcare system. Although establishing a definitive etiology in all patients may not be possible under the circumstances, reasonable efforts should be attempted to investigate a non-hemorrhagic pericardial effusion following penetrating thoracic trauma, as these patients may require other interventions to treat malignancies or infectious causes. As such, we recommend the basic work-up for non-hemorrhagic pericardial effusions following thoracic trauma as shown in (Table 2).

Table 2: Acute pericardial non-hemorrhagic effusion evaluation following trauma.

Evaluation	Considerations
ECG	Distinguish ECG from early repolarization - typically seen in 30 % of young adults
Chest radiograph	Typically, normal - approximately 200 mL of fluid before notable cardiac silhouette enlargement
Complete blood count, chemistry profile, troponin level, erythrocyte sedimentation rate, and serum C-reactive protein level	Inflammatory disease can demonstrate serum elevations are neither sensitive nor specific and may not be helpful acutely; may only see elevation on follow up
HIV/serum viral studies	Yield dependent on risk factors (frequently low); viral studies not routine (unless predictive presenting history) - management unchanged for most viral etiologies
TTE	Small effusion can confirm pericarditis; Formal TTE post-operatively recommended for evaluation of anatomic structure and function
Additional testing to be considered based on detailed history	<ul style="list-style-type: none"> - Blood cultures if fever > 38 degrees - Antinuclear antibody titer (esp. in young women with suggestive history) - Computed tomography to differentiate pulmonary disease/malignancy - Tuberculin skin test or interferon-gamma release assay - Thyroid stimulating hormone (based on history)
Pericardial fluid analysis	Cultures are strongly recommended for effusions that appear purulent <ul style="list-style-type: none"> - Gram stain with aerobic and anaerobic cultures - Fungal stain and culture - Acid fast stain and mycobacterial culture - Cytology - Polymerase chain reaction) for viruses may be considered (low yield, specific studies dependent on risk factors and presentation)

Despite our patient’s hemodynamic stability, in the setting of a positive cardiac ultrasound in penetrating thoracic trauma, we fully expected to find blood secondary to cardiac injury. Yet in finding a serous effusion there are two important points to consider. First, as mentioned previously, the true incidence of non-hemorrhagic effusion in penetrating trauma is unknown. Given the generous range of variability in incidence, one has to wonder about the circumstances of those studies reporting high rates. It is possible that geography, seasonality, or patient age leads to this variability, or that some studies do not differentiate hemorrhagic from non-hemorrhagic pericardial effusion in their reporting. Second, this case demonstrates the diagnostic and therapeutic utility of pericardial window and drain placement in hemodynamically

normal patients with thoracic trauma. Hemodynamic instability and penetrating trauma were found to be independent predictors of therapeutic sternotomy [13]. In performing a pericardial window in a hemodynamically stable patient, we were able to accurately and safely diagnose a non-hemorrhagic effusion, all the while avoiding the morbidity of sternotomy. Median sternotomy complications occur in 0.5-5% of patients, with up to 28% of patients having functional limitations post-operatively [14]. Specific to pericardial window in penetrating cardiac trauma, Nichol *et al.* found no difference in mortality, but an average 1.8 and 2.4 fewer days spent in the ICU and hospital, respectively, in patients who were hemodynamically stable with confirmed hemopericardium and no evidence of active bleed [15].

Similarly, Chestovich *et al.* found that hemodynamically stable patients who sustained penetrating chest injury could be safely managed with pericardial window provided the bleeding had ceased [16].

We present the first reported case of a pericardial effusion secondary to Coxsackie B virus in the setting of penetrating thoracic trauma. While the true incidence of non-hemorrhagic pericardial effusion at the time of thoracic trauma is unknown, it should approximate that of the general population. Accordingly, the astute traumatologist must be prepared to investigate its etiology so as not to miss a major illness. We propose the aforementioned guidelines as a basis for the work-up of non-hemorrhagic pericardial effusions. Finally, in the setting of a hemodynamically normal and stable patient, a pericardial window is a safe and effective method for confirming the diagnosis of hemopericardium following a positive cardiac ultrasound, prior to undergoing median sternotomy.

Data Availability

The data that support the findings of this study are openly available in PubMed. Please see References for specific article information.

Conflicts of Interest

None.

Funding

None.

Acknowledgement

Figure 2: Representative pericardial effusion seen by ultrasound was provided courtesy of Tom Carver, MD.

REFERENCES

- Campbell NC, Thomson SR, Muckart DJJ, Meumann CM, Middelkoop IV et al. (1997) Review of 1198 cases of penetrating cardiac trauma. *Br J Surg* 84: 1737-1740. [[Crossref](#)]
- Thourani VH, Feliciano DV, Cooper WA, Brady KM, Adams AB et al. (1999) Penetrating cardiac trauma at an urban trauma center: a 22-year perspective. *Am Surg* 65: 811-816. [[Crossref](#)]
- Wall MJ, Tsai PI, Mattox KL (2017) Heart and Thoracic Vascular Injuries. In Moore EE, Feliciano DV, & Mattox KL, eds. Trauma. 8th ed. McGraw-Hill Education.
- Rozycki GS, Feliciano DV, Schmidt JA, Cushman JG, Sisley AC et al. (1996) The role of surgeon-performed ultrasound in patients with possible cardiac wounds. *Ann Surg* 223: 737-746. [[Crossref](#)]
- Rozycki GS, Ballard RB, Feliciano DV, Schmidt JA, Pennington SD (1998) Surgeon-performed ultrasound for the assessment of truncal injuries: lessons learned from 1540 patients. *Ann Surg* 228: 557-567. [[Crossref](#)]
- Rozycki GS, Feliciano DV, Oschner MG, Knudson MM, Hoyt DB et al. (1999) The role of ultrasound in patients with possible penetrating cardiac wounds: a prospective multicenter study. *J Trauma* 46: 543-552. [[Crossref](#)]
- Mitiku TY, Heidenreich PA (2011) A small pericardial effusion is a marker of increased mortality. *Am Heart J* 161: 152-157. [[Crossref](#)]
- Sagrìsta Saulea J, Mercé J, Permanyer Miralda G, Soler Soler J (2000) Clinical clues to the causes of large pericardial effusions. *Am J Med* 109: 95-101. [[Crossref](#)]
- Corey GR, Campbell PT, Van Tright P, Kenney RT, O'Connor CM et al. (1993) Etiology of large pericardial effusions. *Am J Med* 95: 209-213. [[Crossref](#)]
- Levy PY, Corey R, Berger P, Habib G, Bonnet JL et al. (2003) Etiologic diagnosis of 204 pericardial effusions. *Medicine* 82: 385-391. [[Crossref](#)]
- Ma W, Liu J, Zeng Y, Chen S, Zheng Y et al. (2011) Causes of moderate to large pericardial effusion requiring pericardiocentesis in 140 Han Chinese patients. *Herz* 37: 183-187. [[Crossref](#)]
- Thorson CM, Namias N, Haren RM, Guarch GA, Ginzburg E et al. (2012) Does hemopericardium after chest trauma mandate sternotomy? *J Trauma Acute Care Surg* 72: 1518-1525. [[Crossref](#)]
- Olbrecht VA, Barreiro CJ, Bonde PN, Williams JA, Baumgartner WA et al. (2006) Clinical Outcomes of Noninfectious Sternal Dehiscence After Median Sternotomy. *Ann Thorac Surg* 82: 902-907. [[Crossref](#)]
- Nicol AJ, Navsaria PH, Beningfield S, Hommes M, Kahn D (2015) Screening for occult penetrating cardiac injuries. *Ann Surg* 261: 573-578. [[Crossref](#)]
- Chestovich PJ, Mcnicoll CF, Fraser DR, Patel PP, Kuhls DA et al. (2018) Selective use of pericardial window and drainage as sole treatment for hemopericardium from penetrating chest trauma. *Trauma Surg Acute Care Open* 3: e000187. [[Crossref](#)]
- Ma OJ, Mateer JR, Ogata MP, Kefer M, Wittmann D et al. (1995) Prospective Analysis of a Rapid Trauma Ultrasound Examination Performed by Emergency Physicians. *J Trauma* 38: 879-885. [[Crossref](#)]
- Bokhari F, Nagy K, Brakenridge S, Smith R, Joseph KNG et al. (2004) The ultrasound screen for penetrating truncal trauma. *Am Surg* 70: 316-321. [[Crossref](#)]
- Tayal VS, Beatty MA, Marx JA, Tomaszewski CA, Thomason MH (2004) FAST (focused assessment with sonography in trauma) accurate for cardiac and intraperitoneal injury in penetrating anterior chest trauma. *J Ultrasound Med* 23: 467-472. [[Crossref](#)]
- Nagy KK, Lohmann C, Kim DO, Barrett J (1995) Role of Echocardiography in the Diagnosis of Occult Penetrating Cardiac Injury. *J Trauma* 38: 859-862. [[Crossref](#)]
- Meyer DM, Jessen ME, Grayburn PA (1995) Use of Echocardiography to Detect Occult Cardiac Injury after Penetrating Thoracic Trauma. *J Trauma* 39: 902-909. [[Crossref](#)]