

Available online at [www.sciencerepository.org](http://www.sciencerepository.org)

Science Repository



## Case Report and Review of the Literature

# Acute Lumbar Paraspinal Compartment Syndrome after a Tug of War: A Case Report and Review of the Literature

Raphael Sedlmayer<sup>1</sup>, Irakli Tinikashvili<sup>1</sup>, Sebastian F. Bigdon<sup>1</sup>, Helena Milavec<sup>1</sup>, Susanne Eichenberger<sup>2</sup>, Paul G. Fairhurst<sup>1</sup> and Moritz C. Deml<sup>1\*</sup>

<sup>1</sup>Department of Orthopaedic Surgery and Traumatology, Inselspital, University Hospital Bern, University of Bern, Switzerland

<sup>2</sup>Department of Emergency Medicine, Inselspital, University Hospital Bern, University of Bern, Switzerland

### ARTICLE INFO

#### Article history:

Received: 4 December, 2020

Accepted: 18 December, 2020

Published: 31 December, 2020

#### Keywords:

Compartment syndrome  
paraspinal compartment  
spine  
spinal injury  
sports injury  
fasciotomy

### ABSTRACT

Compartment syndrome of the upper and the lower extremities is a well-known entity in emergency medicine and traumatology. However, compartment syndrome of the paraspinal musculature is a very rare cause of acute back pain and may be missed at presentation despite its clinical importance. Therefore, we present a case of paraspinal compartment syndrome embedded in an overview of the actual literature. A 21-year-old woman presented with acute back pain refractory to analgesia with opiates after a tug of war match. A CT-scan of the abdomen demonstrated paraspinal swelling and an MRI ruled out intra-spinal pathologies. A compartment measurement yielded a pressure of 135mmHg. Even though conservative treatment attempts are often described, an emergency fasciotomy was carried out. Further rehabilitation was uneventful. Nevertheless, the timing of fasciotomy in the paraspinal region is under discussion, especially due to very rare experiences. Even if surgery is delayed by more than 24 hours following symptom onset, favourable postoperative outcomes have been observed.

© 2020 Moritz C. Deml. Hosting by Science Repository.

### Introduction

Compartment syndrome, especially of the lower extremities, is a well-known post-traumatic and postoperative complication but can also occur in other settings [1]. The most common cause of compartment syndrome is trauma in combination with a fracture [1]. Other causes, for example, are arterial injury and occlusions, reperfusion injury, crush injuries, circumferential burns, or stressful athletic activity [1, 2]. It can occur where muscles are restricted by their fascia, and the increase of compartmental pressure can cause muscle necrosis, as well as neurovascular compression. Typical symptoms include pain, pallor, pulselessness, paraesthesia and paralysis. The initial finding is often only severe pain refractory to opioid analgesia. If the other symptoms occur, the onset of irreversible necrosis must be assumed [1, 2]. Compartment pressures can be measured with a manometer. The normal compartment pressure ranges between 0-8mmHg. In compartment pressures higher than 30mmHg, surgical treatment has to be considered [3]. The surgical therapy of choice is the longitudinal incision of the fascia [4].

We report the first case of a young woman suffering from extreme pain in her right flank following a tug of war match 12 hours earlier, caused by a paraspinal compartment syndrome of the erector spinae muscles. This was initially missed, despite thorough investigation as often described in the even rare literature [5]. In the current literature, the time-point and the need for fasciotomy in paraspinal compartment syndrome are still under discussion due to very rare experiences [5]. Therefore, we report the mentioned case in detail, give an overview of the current literature, standards of diagnostics, and treatment guidelines for this rare pathology.

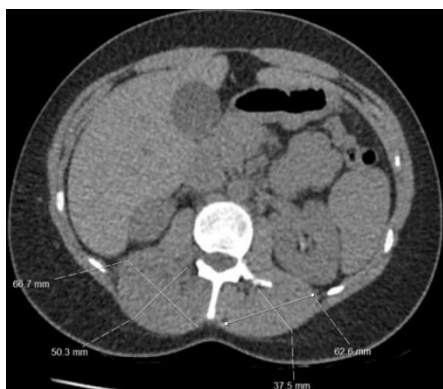### Case Report

A 21-year-old young woman was referred from a peripheral hospital to our Emergency Department with query right-sided acute tubular necrosis. There was no history of trauma but an additional physical load due to a tug-of-war match the day before. She reported an increase in right-sided flank pain three hours following the match. Initially, she reported reduced right leg sensation, which has returned to normal upon

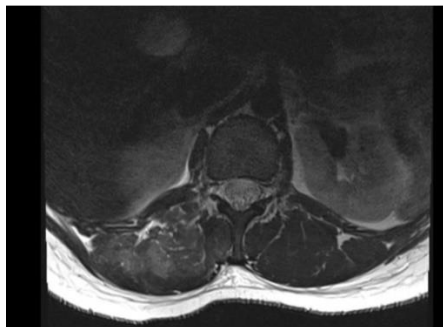
\*Correspondence to: Dr. med. Moritz C. Deml, M.D., Co-Head Spine Surgery, Head Pediatric Spine, Department of Orthopaedic Surgery and Traumatology, Inselspital, University Hospital Bern, University of Bern, Freiburgstrasse 8, 3010 Bern, Switzerland; E-mail: [moritz.deml@insel.ch](mailto:moritz.deml@insel.ch)

presentation. Before being transferred to our hospital, the patient received the following analgesia: Tramadol 400mg, Pethidine 175mg, Fentanyl 100µg, Dafalgan 1g, Novalgine 1g, Voltaren 75mg. There was no dysuria reported. Observations on arrival: Blood pressure 143/78mmHg, pulse 71/min, SpO2 97%, temperature 36.2°C. Abnormal blood results: Creatine kinase (CK) 12268 U/L. Clinical examination revealed solid paravertebral musculature with soft tissue swelling and diminished sensibility in the right thoracolumbar region. There was no local hematoma. Further neurological examination revealed a normal ankle dorsal/plantarflexion with full power (5/5) bilaterally, decreased right-sided knee extension, and hip flexion with power 4/5 (left: 5/5). There was no sensory deficit in all lower limb dermatomes but a loss of sensibility over the right flank and the lower back at the lumbar region.

The CT-scan of the abdomen showed right-sided perifocal edema of the paraspinal muscles (erector spinae and quadratus lumborum) in the thoracolumbar region. There was no active bleeding. Both kidneys had a normal appearance (Figure 1). We conducted a compartment pressure measurement using Compass Universal Hg (Centurion ®) with an 18-gauge needle, saline-filled syringe, and injection of 0.3cc of saline at the level of L2. This yielded a pressure measurement of 135mmHg. The contralateral side was not measured due to missing clinical symptoms. An emergency MRI was performed due to non-specific neurological symptoms as described above to exclude intraspinal pathology. The MRI confirmed intramuscular edema of the right paraspinal musculature, without intraspinal pathology or compression of neurologic structures (Figure 2).



**Figure 1:** Axial view of the abdominal CT-scan shows a right-sided paraspinal muscle swelling compared to the healthy left side and no active bleeding. We excluded kidneys, bony and other pathologies.



**Figure 2:** Axial T2-sequence of the lumbar MRI shows right-sided paraspinal muscle edema and intra-compartmental muscle swelling compared to the left side. An intraspinal pathology was excluded.

Emergency surgery was performed directly following diagnosis. A midline approach over the spinous processes in the thoracolumbar area was used. The muscle fascia was indurated. The thoracolumbar fascia was prepared and a longitudinal right sided paraspinal incision of about 12 cm was performed. A blunt dissection along the intermuscular Wiltse interval showed no visible necrosis of the superficial and deep muscle fibers. However, hypoperfusion indicated by pale-coloured muscle fibers was observed [6]. The fascia was loosely closed with sutures, followed by primary wound closure. The postoperative recovery was unremarkable. There was immediate significant pain reduction postoperatively (Visual-Analog-Scale before surgery 10/10 decreased to 4/10). On the first postoperative day, mobilization with physiotherapy was possible with reduced analgesia.

The CK value (normal <170U/L) increased, however, to 20995 U/L within the first two days after surgery. The renal values remained normal. However, this was treated by high-volume intravenous fluid rehydration (4L/24h). The CK decreased on the third postoperative day. At discharge, the value was 4143U/L. Mobilization did not lead to pain exacerbation. The described sensory deficit improved gradually and at discharge was near normal. The patient was discharged home five days after surgery. Two weeks after surgery, the CK level was 247 U/L. Six weeks postoperatively, the patient reported being pain-free and was able to perform all activities of daily living. The neurologic deterioration fully recovered. No postoperative wound problems occurred. The wound healing was unremarkable, and there was no protrusion of the musculature through the fascia.

## Discussion

Compartment syndrome is a surgical emergency [3]. The most common sites of acute compartment syndrome are the legs, followed by the forearm, arm, foot, and the gluteal region [1, 3]. Paraspinal compartment syndrome is rare and often missed by primary care clinicians [7]. The first case was described in 1985: A young man with severe post-exertional back pain [4]. Most of the reported cases have a primarily atraumatic etiology. Only one study reported a direct trauma [5, 8]. The most common etiology was weightlifting including the famous upcoming cross-fit programmes, followed by skiing. A paraspinal compartment syndrome following a tug of war match has not yet been described [4, 5, 7, 9-15]. This case shows that in the case of acute back pain with indurated back musculature, even without major trauma, compartment syndrome represents an important differential diagnosis in patients presenting with severe abdominal, lumbar and paraspinal pain.

The paraspinal compartment is enclosed by the thoracolumbar fascia on all, but the medial side where it is bordered by the spinous processes and interspinous ligament [6]. An elevated CK is a consistent finding, and this response rapidly to surgical decompression [5]. Manual pressure measurement is the ideal test, providing direct information regarding the intra-compartment pressure, with normal ranges well documented by previous literature [1, 2]. The intra-compartment pressure was 135 mmHg in our case and is reported from 14.7 to 150 mmHg for paraspinal compartment syndrome [4, 5, 7, 9-15]. For diagnosing compartment syndrome in the extremities, imaging is typically neither required nor recommended [2]. In paraspinal compartment syndrome, it can be very useful due to diagnostic uncertainty and a lack of experience with the

condition. MRI is the imaging of choice and showed significant features in most of the reported cases [5, 7, 8]. Our patient had paraspinal enhancement on T2-weighted images, indicating edema within the compartment. The CT-scan was also useful, showing swelling of the paraspinal musculature. Both modalities also helped to exclude differential diagnoses such as spinal stenosis, nucleus pulposus prolapses, infection, tumor, or fracture.

Most authors recommend a conservative treatment with rest, pain medication and high volume therapy to prevent high CK-serum levels. Nevertheless, the literature describes an increased recovery time and overall poor outcome with conservative treatment compared with surgical treatment. But no clear treatment recommendation can be given [5, 8, 13, 14, 16-18]. Moreover, fasciotomy is associated with good outcomes in all reported cases, even with a significant delay from the time of symptom onset (up to 7 days) [5, 8, 14]. Regarding these promising results and taking our good clinical results into consideration, emergent fasciotomy should be a valid treatment-option for heavily suffering patients, high levels of intramuscular pressures and proof for rhabdomyolysis due to high CK-serum levels. A compartment pressure value and CK-serum-level as cut off for or against a surgical treatment cannot be given for this specific pathology due to the low number of reported cases. Recommendations regarding a cut-off value for fasciotomy range from 30-70mmHg intracompartment pressure [8].

In our case, we used a Wiltse approach through a midline incision and adapted the fascia loosely and closed the skin primarily due to a loose subcutis and cutis. Pitifully the wound closure techniques are not well described in other reports. Alexander *et al.* and Maeckelbergh and colleagues used a paramedian incision to prevent exposed bony structures as the processi spinosi. With a paramedian incision, a delayed soft tissue closure or grafting over viable muscle beds would be possible due to the lower risk of exposed bony structures [5, 8]. It is also not clear whether or not a primary wound closure over a partly adapted fascia can be the treatment of choice [8]. But compared to the lower extremities where subcutis is very thin, primary wound closure in the thoracolumbar region in light obese patients can be a viable option. In skinny patients, a secondary wound closure of a paramedian incision might be the better treatment of choice. In our case, the patient was a little overweight; thus, we had no problem closing the wound over the opened fascia primarily. No muscle induration at the last follow-up was seen.

## Conclusion

Paraspinal compartment syndrome is a very rare pathology and is often caused by exertional rhabdomyolysis. Based on the good outcomes after fasciotomy reported in the literature as well as our favourable experience, in this case, urgent fasciotomy in case of increased interfacial pressure, swollen lumbar paraspinal region, and exclusion of other differential diagnoses is a viable treatment option. Nevertheless, there exists no consensus about diagnostic criteria helping in the decision for or against an operative treatment. A paraspinal approach is favourable to prevent exposed bony structures. The primary wound closure of the skin seems to be an option in obese or mild overweight patients with low soft-tissue tension over the thoracolumbar fascia. Secondary wound closures are also described with good clinical results.

## Ethical Approval

The authors of this manuscript declare that this scientific work complies with reporting quality, formatting, and reproducibility guidelines set forth by the EQUATOR Network. The authors also attest that this clinical investigation does not require the Institutional Review Board / Ethics Committee review. Therefore, no corresponding protocol/approval number exists. Due to local ethics regulation, no further ethical approval is necessary for single case presentations.

## Consent

The patient in question gave its written consent to the anonymized publication of clinical data and imaging reported in this case report.

## Author Contributions

MCD, RS, and IT set up the study protocol. RS, SE, IT, and SFB selected the data. RS, SE, and HM performed data analyses. RS, MCD, PEF, SFB, and HM prepared the manuscript. All authors approved the final manuscript.

## Conflicts of Interest

None.

## Funding

None.

## REFERENCES

1. Brandao RA, St John JM, Langan TM, Schneekloth BJ, Burns PR (2018) Acute Compartment Syndrome of the Foot Due To Frostbite: Literature Review and Case Report. *J Foot Ankle Surg* 57: 382-387. [[Crossref](#)]
2. Liu B, Barraqueta G, Ruchelsman DE (2017) Chronic Exertional Compartment Syndrome in Athletes. *J Hand Surg Am* 42: 917-923. [[Crossref](#)]
3. Santistevan JR (2017) Acute Limb Ischemia: An Emergency Medicine Approach. *Emerg Med Clin North Am* 35: 889-909. [[Crossref](#)]
4. Kitajima I, Tachibana S, Hirota Y, Nakamichi K. Acute paraspinal muscle compartment syndrome treated with surgical decompression: a case report. *Am J Sports Med* 30: 283-285. [[Crossref](#)]
5. Alexander W, Low N, Pratt G (2018) Acute lumbar paraspinal compartment syndrome: a systematic review. *ANZ J Surg* 88: 854-859. [[Crossref](#)]
6. Wiltse LL, Bateman JG, Hutchinson RH, Nelson WE (1968) The paraspinal sacrospinalis-splitting approach to the lumbar spine. *J Bone Joint Surg Am* 50: 919-926. [[Crossref](#)]
7. Rogers ME, Lowe JA, Vanlandingham SC (2014) Acute erector spinae compartment syndrome: case report and review of diagnostic criteria. *Injury* 45: 813-815. [[Crossref](#)]
8. Maeckelbergh L, Moke L (2019) An Acute Paraspinal Compartment Syndrome: Anatomic Description of the Compartment and Surgical Technique. *Clin Spine Surg* 32: E277-E281. [[Crossref](#)]

9. Minnema BJ, Neligan PC, Quraishi NA, Fehlings MG, Prakash S (2008) A case of occult compartment syndrome and nonresolving rhabdomyolysis. *J Gen Intern Med* 23: 871-874. [[Crossref](#)]
10. Paryavi E, Jobin CM, Ludwig SC, Zahiri H, Cushman J (2010) Acute exertional lumbar paraspinal compartment syndrome. *Spine* 35: E1529-E1533. [[Crossref](#)]
11. Rha EY, Kim DH, Yoo G (2014) Acute exertional lumbar paraspinal compartment syndrome treated with fasciotomy and dermatotraction: case report. *J Plast Reconstr Aesthet Surg* 67: 425-426. [[Crossref](#)]
12. Nathan ST, Roberts CS, Deliberato D (2012) Lumbar paraspinal compartment syndrome. *Int Orthop* 36: 1221-1227. [[Crossref](#)]
13. Hoyle A, Tang V, Baker A, Blades R (2015) Acute paraspinal compartment syndrome as a rare cause of loin pain. *Ann R Coll Surg Engl* 97: e11-e12. [[Crossref](#)]
14. DiFazio FA, Barth RA, Frymoyer JW (1991) Acute lumbar paraspinal compartment syndrome. A case report. *J Bone Joint Surg Am* 73: 1101-1103. [[Crossref](#)]
15. Carr D, Gilbertson L, Frymoyer J, Krag M, Pope M (1985) Lumbar paraspinal compartment syndrome. A case report with physiologic and anatomic studies. *Spine* 10: 816-820. [[Crossref](#)]
16. Karam MD, Amendola A, Lattes SM (2010) Case report: successful treatment of acute exertional paraspinal compartment syndrome with hyperbaric oxygen therapy. *Iowa Orthop J* 30: 188-190. [[Crossref](#)]
17. Wik L, Patterson JM, Oswald AE (2010) Exertional paraspinal muscle rhabdomyolysis and compartment syndrome: a cause of back pain not to be missed. *Clin Rheumatol* 29: 803-805. [[Crossref](#)]
18. Kanaya H, Enokida M, Tanishima S, Hayashi I, Tanida A et al. (2017) Conservative treatment for lumbar compartment syndrome shows efficacy over 2-year follow-up: a case report and literature review. *Arch Orthop Trauma Surg* 137: 1233-1238. [[Crossref](#)]