

Available online at [www.sciencerepository.org](http://www.sciencerepository.org)

Science Repository



## Case Report

# Anaphylaxis: An Infrequent Presentation of Hydatid Disease

MT Moreno\*, M Maes, N Rodriguez, P Froján and García M

Ourense Hospital Complex, Ourense, Spain

### ARTICLE INFO

#### Article history:

Received: 26 October, 2020

Accepted: 9 November, 2020

Published: 30 November, 2020

#### Keywords:

*Echinococcus*

anaphylaxis

hepatic cyst

### ABSTRACT

**Background:** Hydatid disease in humans is caused by the taeniid *Echinococcus*. It usually presents as an asymptomatic hepatic cyst. Its manifestation as anaphylactic shock is exceptional.

**Aim:** To present a clinical case of anaphylaxis due to hydatidosis.

**Material and Methods:** A 32-year-old farmer man was admitted as emergency with pruritus in the hands, feet and armpits associated with erythema, facial edema and generalized haborasal lesions. He referred feeling of respiratory distress. The examination revealed a hypotensive and tachycardia patient, with a baseline oxygen saturation of 90%. Blood analysis revealed leukocytosis stands, without other notable findings as a normal liver profile. During hospital care, he presented a single episode of fever of 38°C without focaloty. After 48 hours of close monitoring, the patient remains asymptomatic, so discharge home is decided.

**Results:** The study by allergology showed eosinophilia, high levels of IgE with low C4 and positive serology for *E. granulosus* stand out. A thoraco-abdominopelvic computed tomography showed a lesion of a cystic nature in the right hepatic lobe, corresponding to a CE3 transitional hydatid cyst (WHO classification). After treatment with Albendazol, a closed cystopericystectomy is performed using a right subcostal laparotomy that proceeds without incident.

**Conclusion:** Despite the fact that anaphylaxis secondary to hydatid disease is rare, it should always be included in the differential diagnosis of an episode of anaphylactic reaction of unknown cause due to the severity of the disease and the specificity of the required treatment.

© 2020 María Teresa Moreno Asencio. Hosting by Science Repository.

Hydatid disease or echinococcosis in humans is caused by infection of the *Echinococcus* genus cestodes. *E. granulosus* is the most frequent in Spain and it is associated with cystic echinococcosis [1]. Its frequency has increased in recent years [2]. It usually presents asymptotically, although an increase in the size of the cyst may lead to the appearance of symptoms. Its manifestation as anaphylactic shock is exceptional, but it should be considered a differential diagnosis that gave the increase in incidence in recent years [3].

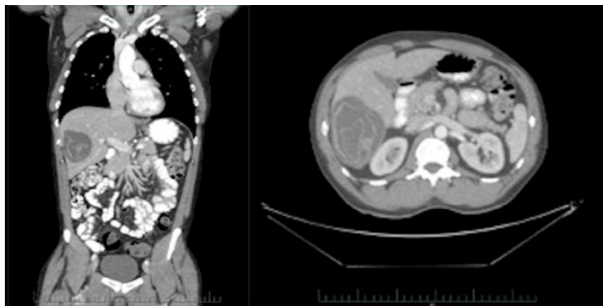
A 32-year-old farmer man was admitted as an emergency with pruritus predominantly in the hands, feet, and armpits associated with erythema, facial edema, and generalized raised rash lesions. He referred to respiratory distress and dizziness. The examination revealed

hypotension and tachycardia (BP 90/55 mmHg, HR 115 bpm), with a basal oxygen saturation of 90%, without respiratory drainage. Symptoms and hemodynamic status improved after the administration of corticosteroids, epinephrine, and dexchlorpheniramine (BP 110/89 mmHg, HR 52 bpm).

Blood analysis revealed leukocytosis (20,890 / mm<sup>3</sup>), without other notable findings. Liver enzymes were at normal levels. Chest radiography showed no pathological findings. During hospital care, he presented one episode of fever of 38°C of unknown origin (negative blood cultures, non-pathological urine analysis, and not associated with respiratory symptoms). After 48 hours of monitoring and close following, the patient remained asymptomatic, and it was discharged home.

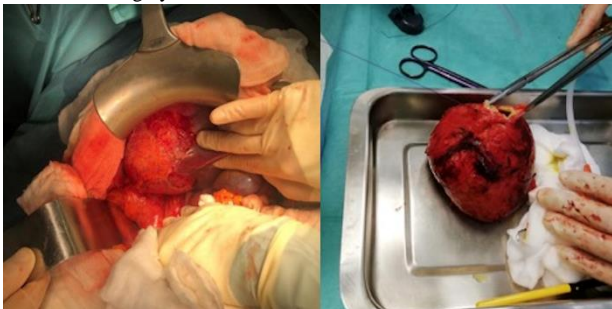
\*Correspondence to: María Teresa Moreno Asencio, Ourense Hospital Complex, Ramón Puga Noguero, 54, Ourense, 32005, Spain; E-mail: [mtma\\_87@yahoo.es](mailto:mtma_87@yahoo.es)

The study by the specialty of Allergology showed eosinophilia (15%), high levels of IgE with low C4 (total IgE 1274 kU / L; complement C4 12.2 mg / dL) and positive serology for *E. granulosus* (antibody titer: 2560). A thoracic-abdominopelvic computed tomography (CT) was performed and showed a 10.6 cm x 7.3 cm x 8 cm well-defined cystic lesion in the right hepatic lobe with small peripheral calcifications, as well as dense membranes and papillary-looking lesions, corresponding to a CE3 transitional hydatid cyst (WHO classification) (Figure 1).



**Figure 1:** CT abdomen; C3 transitional type hydatid cyst (WHO classification); Coronal and axial sections.

Following these findings, a surgical intervention was decided and antiparasitic albendazole 500mg every 12 hours was started for a month prior to it. A cystopericystectomy was performed using a right subcostal laparotomy without incident (Figure 2). The patient was discharged after 6 days in hospital without postoperative complications, completing treatment with albendazole 500 mg every 12 hours for an additional month after surgery.



**Figure 2:** Hydatid cyst; Closed cystopericystectomy.

Hydatidosis is an endemic disease in Spain. Although the epidemiological situation is not well established, there has been an increase in its incidence in recent years, especially because of the weak control programs in both animals and young people [4-6].

An anaphylactic reaction is a rare presentation of hydatid disease (between 1-7.5%) [7]. It can occur if the content of the cyst is released to a host that has IgE antibodies developed by a previous leak. We can find anaphylaxis without identifying macroscopic ruptures of the cyst [2]. The management of hydatid cysts varies depending on the location,

extension in the affected organ, and possible associated complications (rupture or haemorrhage) [8]. Standard treatment includes adjuvant chemotherapy and surgical resection. Cystopericystectomy is considered the curative surgical approach. The recommended chemotherapy treatment (four days before surgery and at least one month after) is 10-15mg/kg of albendazole daily divided into two doses [9, 10].

The most common toxic effect of albendazole is the elevation of liver enzymes (20% of cases). It has also a suppressive effect on the bone marrow. Therefore, it is important to monitor liver enzyme levels and blood count [10]. In conclusion, even though secondary anaphylaxis to hydatid disease is rare (1-7%), it should always be included in the differential diagnosis of an episode of the anaphylactic reaction of unknown cause due to the severity of the disease and the specificity of the required treatment.

## REFERENCES

1. Ángel JMR, Llamas RDL, Vázquez AM (2018) Quistes hepáticos parasitarios y abscesos hepáticos. En: Robles Campos, R, Parrilla Paricio, P(eds.). Guía De Cirugía Hepática (2ª Ed.) Madrid: Arán 259-272.
2. Gavara CGI, Andújar RL, Ibáñez TB, Ángel JMR, Herraiz AM et al. (2015) Review of the treatment of liver hydatid cysts. *World J Gastroenterol* 21: 124-131. [[Crossref](#)]
3. Mincullo PL, Cascio A, David A, Pernice LM, Calapai G et al. (2012) Anaphylaxis caused by helminthes: Review of the literature. *Eur Rev Med Pharmacol Sci* 16: 1513-1518. [[Crossref](#)]
4. García MSDSM, Ordoñez MDCL, Zorita BD, Baeza ML (2018) An infrequent case of anaphylaxis. *Ann Allergy Asthma Immunol* 120: 104-105. [[Crossref](#)]
5. Pardo J, Muro A, Galindo I, Cordero M, Carpio A et al. (2005) Hidatidosis en la provincia de Salamanca (España): ¿debemos bajar la guardia? *Enferm Infecc Microbiol Clin* 23: 266-269.
6. Bernus AL, García M, Sardón MA, Pérez AC, Tirado VV et al. (2015) Human Echinococcosis in Castilla-Leon, Spain, between 2000-2012. *PLoS Negl Trop Dis* 9: e0004154. [[Crossref](#)]
7. Sezgin O, Altintas E, Saritas U, Sahin B (2005) Hepatic alveolar echinococcosis: clinical and radiologic features and endoscopic Management. *J Clin Gastroenterol* 39: 160-167. [[Crossref](#)]
8. Symeonidis N, Pavlidis T, Baltatzis M, Ballas K, Psarras K et al. (2013) Complicated liver echinococcosis: 30 years of experience from an endemic area. *Scand J Surg* 102: 171-177. [[Crossref](#)]
9. Brunetti E, Kern P, Vuitton DA, Writing Panel for the WHO-IWGE (2010) Expert consensus for the diagnosis and treatment of cystic and alveolar echinococcosis in humans. *Acta Trop* 114: 1-16. [[Crossref](#)]
10. Keong B, Wilkie B, Sutherland T, Fox A (2018) Hepatic cystic echinococcosis in Australia: an update on diagnosis and management. *ANZ J Surg* 88: 26-31. [[Crossref](#)]