

Available online at www.sciencerepository.org

Science Repository



Review Article

Teaching Review on Approach of Esophageal Intubation as Complications in Emergency Airway Management

Adel Hamed Elbaih^{1,2*} and Mohammad Assef Mousa³

¹Associate Professor of Emergency Medicine, Faculty of Medicine, Suez Canal University, Ismailia, Egypt

²Associate Professor of Emergency Medicine, Sulaiman AlRajhi University, Clinical Medical Science, Saudi Arabia

³Emergency Medicine, College of Medicine, Sulaiman AlRajhi University, Clinical Medical Science, Saudi Arabia

ARTICLE INFO

Article history:

Received: 26 August, 2020

Accepted: 25 September, 2020

Published: 29 October, 2020

Keywords:

Airway

emergency physicians

skill approach

management

ABSTRACT

Background: Intubation is daily process in hospitals, it's insertion of tube to secure an airway, non-emergent intubation is done in well controlled circumstances, while emergent intubation is not. Most emergency intubated are cardiac or respiratory arrest patients. Intubation helps to secure airway for patient breathing, also could protect from aspiration. Most common complications are: esophagus intubation and hypotension. This research will be divided into two main topics, emergency intubation as a whole, and unrecognized esophagus intubation as a complication. Emergency intubation discuss: knowledge about the procedure, equipment needed, airway assessment, preoxygenation, difficulties and risks, outcomes. While Unrecognized esophagus intubation will be discussed as complication in ER settings, point to clear: Epidemiology, tools of detection, equipment, human and environmental bias and consideration for cardiac arrest patients. Finishing with a conclusion and recommendation. Therefore, we aim to look into the common pitfalls that both medical students and new physicians face in the recognition, diagnosis, and Emergency Airway Management.

Targeted Population: Airway cardiorespiratory arrest patients who are requiring urgent management in the ED, with emergency physicians for teaching approach protocol.

Aim of the Study: Appropriate for assessment and priorities for Airway cardiorespiratory arrest patients by training protocol to emergency physicians. Based on patients' causes of Airway injuries.

Methods: Collection of all possible available data about the Esophageal Intubation as Complications in the Emergency department. By many research questions to achieve these aims so a midline literature search was performed with the keywords "critical care", "emergency medicine", "principals of airway management", "Esophageal Intubation as Complications". Literature search included an overview of recent definition, causes and recent therapeutic strategies.

Results: All studies introduced that the initial diagnosis of Esophageal Intubation as Complications is a lifesaving conditions that face patients of the emergency and critical care departments.

Conclusion: Intubation in emergency settings require a good preparation, available equipment (e.g. ready cart for all time), and supportive anatomical airway of the patient. Following a checklist will improve outcomes, prevent malpractice and complications. Preoxygenation and RSI play major roles for successful intubations with decrease risk of complications. Follow procedure steps, and expect difficult intubation for any patient, so consider LEMON mnemonic to evaluate risk of difficulty, and after 3 attempts try a different technique or equipment. More training and education are essential to decrease congenital and equipotential mistakes/errors.

© 2020 Adel Hamed Elbaih. Hosting by Science Repository.

*Correspondence to: Dr. Adel Hamed Elbaih, M.D., Associate Professor of Emergency Medicine, Suez Canal University, Ismailia, Egypt, Associate Professor of Emergency Medicine, Sulaiman AlRajhi University, Clinical Medical Science, Saudi Arabia; Tel: 00201154599748; E-mail: elbaihziico@yahoo.com

Introduction

Intubations in the hospital is a daily process aimed to secure an airway, which further makes a route for oxygen and ventilation delivery, also protect from aspiration. Our topic is going to discuss the emergent intubation, which is different than the nonemergent, which done under controlled circumstances [1]. Emergent intubation usually involves a patient suffers cardiac or respiratory arrest, and it's done under resuscitation activities. Endotracheal intubation plays the cornerstone role of emergent airway management. Intubation maybe accomplished by the emergency physician, anaesthesiologist, pulmonologist, respiratory therapist or even a nurse practitioner. Before intubation many preparations are taken to improve the outcomes, like rapid sequence intubation, preoxygenation, equipment checking and positioning the patient. Mallampati criteria and LEMON mnemonic give idea about difficulty of intubation [2].

During emergency intubation, some complications may surface, and most common two are esophagus intubation and hypotension, while esophagus intubation results from mispositioning, hypotension usually is result of RSI induction [3]. Unrecognized esophagus intubation of ETT has incidence between 3-17%, it is the most common complication of emergency intubation, and it's a found cause of morbidity and mortality in emergency rooms, specially brain damage and death. Because of danger effects esophagus intubation may cause, some checklists and tools are used to check positioning as ETCO₂. However, arrest patients need better alternative and Acoustic reflectometry shows a promising one [3].

To Do Before Intubation

TABLE 29A-1	Equipment Needed for Airway Management
•	Oxygen source and tubing
•	Ambu bag
•	Mask with valve, various sizes and shapes
•	Oropharyngeal airways—small, medium, large
•	Nasopharyngeal airways—small, medium, large
•	Suction catheters: Yankauer, tracheal suction catheters, nasogastric suction connection tubing for particulate and large amounts of vomitus
•	Suction source
•	Pulse oximetry
•	Carbon dioxide detector
•	Endotracheal tubes—various sizes
•	Laryngoscope blades and handles
•	Syringes
•	Magill forceps
•	Stylets, assorted
•	Tongue blade
•	Intubating stylet (gum elastic bougie)
•	Water-soluble lubricant or anesthetic jelly
•	Rescue devices: video laryngoscopes, laryngeal mask airway, intubating laryngeal mask airway, i-gel® (Intersurgical Inc., Liverpool, NY), King LT® (King Systems, Noblesville, IN)
•	Surgical cricothyroidotomy kit
•	Medications for topical airway anesthesia, sedation, and rapid-sequence intubation

Figure 1: Tools Pre-intubations.

The preparation is very important for a successful intubation, and for that there is a list of equipment practitioner should prepare before the procedure (Figure 1). This equipment preferably be ready in the special cart, along with other considerations, like a small sized laryngoscope in case of pediatric case, next step would be ensuring ongoing cardiac rhythm, heart rate, blood pressure, O₂ saturation and carbon dioxide partial pressure. During the preparation patient is ventilated and oxygenated with bag-mask ventilation (BMV, Figure 2).



Figure 2: The Bag Mask Ventilation.

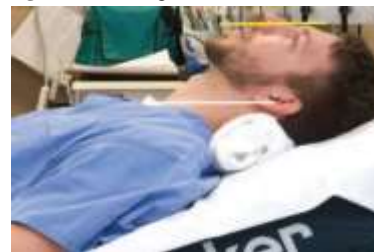

Figure 3: Positioning During Intubation.

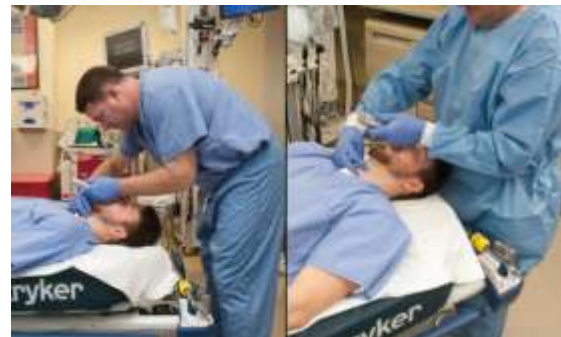

Figure 4: Intubation Operator isn't correct on the left; Intubation Operator is correct on the right.

Next, IV access establishment and appropriate fluids: Next, patient positioning, a trained staff is called to adjust patient position, patient need to be supine, with head hyperextended in a 'sniffing' position, his external ear is aligned with the sternal notch (Figure 3) this shall help for better glottis visualization. The bed should be elevated till the operator's xiphoid; this will give a better access to the mouth above patient head during intubation (Figure 4). It's not optimal for intubation to apply padding under neck or shoulder [1].



Figure 5: Yankauer Catheter.

Sometimes a more upright intubation position might be used when patient can't lay supine, as a patient with severe pulmonary edema or is morbidly obese (Figure 7). If patient is vomiting or with large stuck particles, use Yankauer catheter (Figure 5) or other suction tube in the side of the mouth, suction will be made along with intubation (Figure 6).

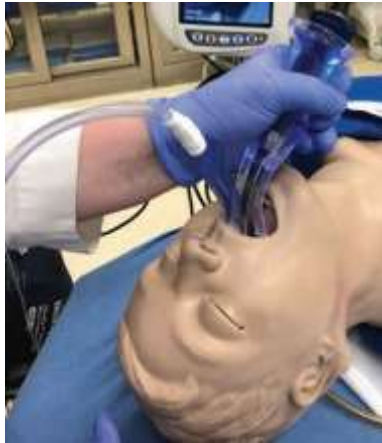

Figure 6: Suction with Intubation.

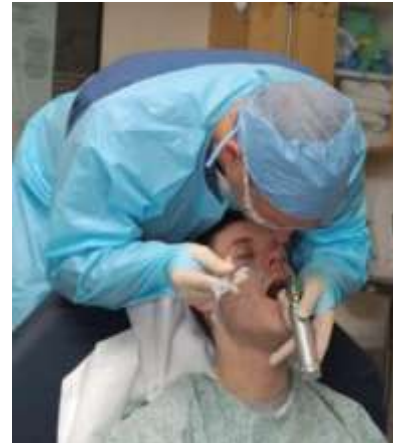


Figure 7: Intubations in morbid obese with pulmonary edema.

Endotracheal Intubation - 1

No Steps Attempted

Start Time: Stop Time:

STEPS

Remove airway foreign body	<input type="radio"/> Yes <input type="radio"/> No <input type="radio"/> V <input type="radio"/> M <input type="radio"/> NI
Check light on laryngoscope before putting blade in mouth	<input type="radio"/> Yes <input type="radio"/> No <input type="radio"/> V <input type="radio"/> M <input type="radio"/> NI
Places stylet in ETT	<input type="radio"/> Yes <input type="radio"/> No <input type="radio"/> V <input type="radio"/> M <input type="radio"/> NI
Check cuff on ETT by inflating/deflating it before use	<input type="radio"/> Yes <input type="radio"/> No <input type="radio"/> V <input type="radio"/> M <input type="radio"/> NI
Has all necessary equipment prepared and within reach prior to starting ETI attempt	<input type="radio"/> Yes <input type="radio"/> No <input type="radio"/> V <input type="radio"/> M <input type="radio"/> NI
Place patient's head into neutral or sniffing position	<input type="radio"/> Yes <input type="radio"/> No <input type="radio"/> V <input type="radio"/> M <input type="radio"/> NI
Open patient's mouth	<input type="radio"/> Yes <input type="radio"/> No <input type="radio"/> V <input type="radio"/> M <input type="radio"/> NI
Hold laryngoscope blade in LEFT hand	<input type="radio"/> Yes <input type="radio"/> No <input type="radio"/> V <input type="radio"/> M <input type="radio"/> NI
Places laryngoscope blade in RIGHT side of mouth AND then moves blade to midline	<input type="radio"/> Yes <input type="radio"/> No <input type="radio"/> V <input type="radio"/> M <input type="radio"/> NI
Elevates tongue and mandible without rocking back on laryngoscope	<input type="radio"/> Yes <input type="radio"/> No <input type="radio"/> V <input type="radio"/> M <input type="radio"/> NI
Visualizes epiglottis	<input type="radio"/> Yes <input type="radio"/> No <input type="radio"/> V <input type="radio"/> M <input type="radio"/> NI
Places tip of laryngoscope blade in vallecula	<input type="radio"/> Yes <input type="radio"/> No <input type="radio"/> V <input type="radio"/> M <input type="radio"/> NI
Engages hyoepiglottic ligament with tip of laryngoscope blade	<input type="radio"/> Yes <input type="radio"/> No <input type="radio"/> V <input type="radio"/> M <input type="radio"/> NI
Pass ETT and entire ETT cuff (balloon) through vocal cords	<input type="radio"/> Yes <input type="radio"/> No <input type="radio"/> V <input type="radio"/> M <input type="radio"/> NI
Remove stylet (if used)	<input type="radio"/> Yes <input type="radio"/> No <input type="radio"/> V <input type="radio"/> M <input type="radio"/> NI
Inflate cuff AND remove syringe	<input type="radio"/> Yes <input type="radio"/> No <input type="radio"/> V <input type="radio"/> M <input type="radio"/> NI
Checks ETT cuff after inflation by feeling balloon	<input type="radio"/> Yes <input type="radio"/> No <input type="radio"/> V <input type="radio"/> M <input type="radio"/> NI
Check for air exchange AND tube placement (ear to tube) PRIOR to securing tube	<input type="radio"/> Yes <input type="radio"/> No <input type="radio"/> V <input type="radio"/> M <input type="radio"/> NI
Verify placement using EtCO2 and/or EDD	<input type="radio"/> Yes <input type="radio"/> No <input type="radio"/> V <input type="radio"/> M <input type="radio"/> NI
Check O2 saturation using pulse oximeter	<input type="radio"/> Yes <input type="radio"/> No <input type="radio"/> V <input type="radio"/> M <input type="radio"/> NI
Secure the ETT with tape, cloth ties, or other	<input type="radio"/> Yes <input type="radio"/> No <input type="radio"/> V <input type="radio"/> M <input type="radio"/> NI

Endotracheal Intubation - 2

of ETI attempts:

ERRORS

Was the tube placed too shallow or too deep (<21cm OR >25cm at the teeth)?	<input type="radio"/> Yes <input type="radio"/> No <input type="radio"/> V <input type="radio"/> M <input type="radio"/> NI
Advances tube down the "barrel" (middle) of the blade (ie. not from corner of mouth)	<input type="radio"/> Yes <input type="radio"/> No <input type="radio"/> V <input type="radio"/> M <input type="radio"/> NI
Was the patient intubated too early or too late (poor MARCHE order)?	<input type="radio"/> Yes <input type="radio"/> No <input type="radio"/> V <input type="radio"/> M <input type="radio"/> NI
Did student take action if ETT was placed too deep (>25cm)?	<input type="radio"/> Yes <input type="radio"/> No <input type="radio"/> V <input type="radio"/> M <input type="radio"/> NI
Breaks teeth	<input type="radio"/> Yes <input type="radio"/> No <input type="radio"/> V <input type="radio"/> M <input type="radio"/> NI

CRITICAL ERROR

Did the student take action if tube was malpositioned in esophagus or hypopharynx (not below cords in trachea)?	<input type="radio"/> Yes <input type="radio"/> No <input type="radio"/> V <input type="radio"/> M <input type="radio"/> NI
Was the airway restored within 3.5 minutes of the procedure being indicated or within 3 attempts at ETI?	<input type="radio"/> Yes <input type="radio"/> No <input type="radio"/> V <input type="radio"/> M <input type="radio"/> NI

CRITICAL FAIL (NOTE: subject must have started procedure)

RATER intervened to save patient / prevent harm	<input type="radio"/> Yes <input type="radio"/> No <input type="radio"/> NI
---	---

Figure 8: A & B) Emergency Airway Procedures.

After you finish preparing your equipment, make sure of its functionality, including oxygen mask, suction tube, laryngoscope lighting and blade and so on. Check the availability of a mechanical ventilator for applying after intubation has been made, do not forget to calculate the body mass and appropriate doses of the adjuvant intubation medications, rapid sequence induction (RSI) and types of laryngoscopes will be covered later on in this research [4]. Collect all possible clinical information, patient condition, his history and define your care goals and discuss it with your team. A checklist could be used for easy application and for prevention of any kind of errors (Figure 8). Patient parameters are important to normalize before intubating drugs induction, it includes

heart rate, oxygen saturation and blood pressure, the reason that cardiac arrests are possible when any parameter of these are abnormal [2].

Airway Assessment

About 15% of initial emergent intubation attempts fail in recent study, and 2% of overall endotracheal attempts also fail with the standard method, "Expect difficulty with all emergency airway cases, apply a uniform approach to all patients" Tintinalli said in his 9th edition [1]. Some factors defined for airway management and intubation difficulty, which are: facial hair, lack teeth, history of OSAS, short neck, limited

neck mobility, small or large chin, prominent incisors, high arched palate, facial or airway trauma, head or neck tumors, angioedema, Ludwig's angina and finally inflammation of the airway as in burning patients. Mallampati criteria suggests the difficulty of intubation according to tongue level (Figure 9) [1].

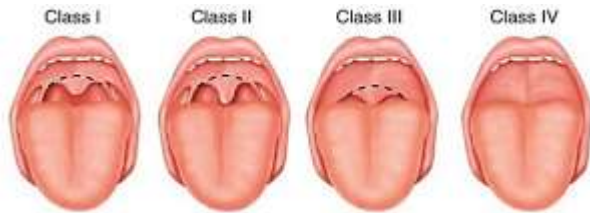

Figure 9: Mallampati criteria for Assessment Airway.

Preoxygenation

Process of giving O₂ before the intubation, aim of it to improve oxygen saturation, further decreases risks of dysrhythmias, decompensation and cardiac arrest, also helps to make more space for oxygen by removing nitrogen from alveoli. Preoxygenation is induced with tidal breathing and with sealing the mask. If oxygen saturation fails to reach above 90% with spontaneous breathing, bag-valve-mask, continuous positive airway pressure or other solutions should be considered. Sometimes, head elevation could be useful, as sedatives for agitated patients [4].

Procedure (Back to Figure 8 for more details)

- i. Clear the mouth, remove any unsecured particles (e.g. fallen tooth, food).
- ii. Carry the laryngoscope (Figure 10) from its base with left hand.
- iii. With your right hand, open the mouth, insert suction tube, manipulate the larynx, insert ETT (Endo tracheal tube).
- iv. Insert the blade into the right side of the mouth, and carefully advance through it.
- v. After reaching epiglottis and visualize glottis (Figure 11), lift it to provide access for ETT.
- vi. CARE for vocal cords injury by excessive insertion.
- vii. Put the ETT with caution.
- viii. Inflate the balloon, use from 5-7 mL of air.
- ix. Confirm correct placing, by stethoscope, bilateral breath sounds, no epigastric sounds. Also, by colorimetric carbon dioxide detector (Figure 12), usually accompany ETT. Later, radiograph (end tube has a 'shiny' part) (Figure 13) and echo shall be made to confirm the positioning.
- x. Secure ETT, use taping or tube holder [1].



Figure 10: laryngoscope.

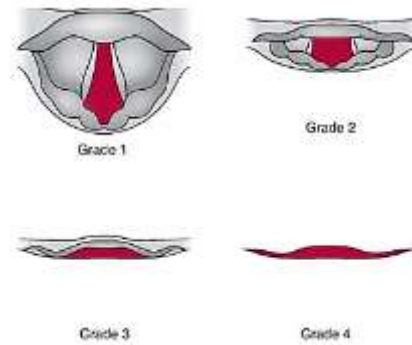


Figure 11: Uvula for Assessment Airway.



Figure 12: Colorimetric Carbon Dioxide Detector.

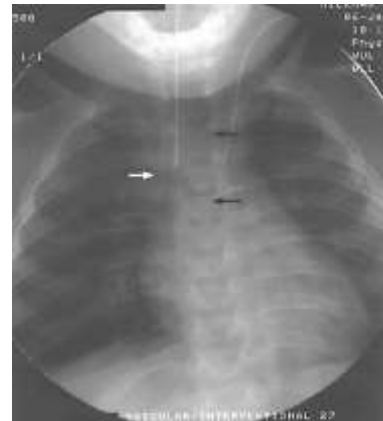

Figure 13: Endotracheal Tube on X-ray to confirm position by "a shiny part".

Difficulties of Emergency Intubation

Researchers usually use the number of attempts to evaluate intubation success. Some indications for difficult intubation prior the procedure forms a mnemonic: LEMON, it's been tested in adult cases only not children.

L: Look for indications for difficult intubation, facial hair, burns... etc.

E: Evaluate mouth opening, thyromental and mandible to thyroid cartilage distances with head fully extended.

M: Mallampati score (Figure 9).

O: Obstruction of upper airway tract signs, stridor, wheezing and muffled voice.

N: Neck immobility, cervical injury and congenital abnormalities.

However, many studies conducted to measure success rate of intubation, two examples were studies that made on 10 years. First between 1990

and 2000, the other between 2002 and 2012, it found 68% success rate in first attempt, while 83% in the other one, putting into consideration, the larger sample size of second study (19,629), compared to smaller (2,833) sample size in the first one [1, 4, 5]

Complications of Emergency Intubation

Preparation could prevent many complications that may arise, but few issues to be expected or associated with three or more attempts, such as, hypoxemia, regurgitation and aspiration, tract trauma, bradycardia and esophageal intubation. Other possible complications, like: teeth trauma, right bronchus intubation, damage to vocal cords and infections.

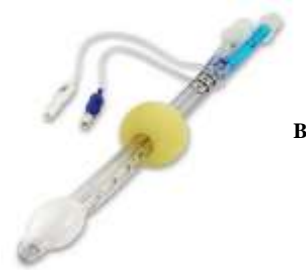
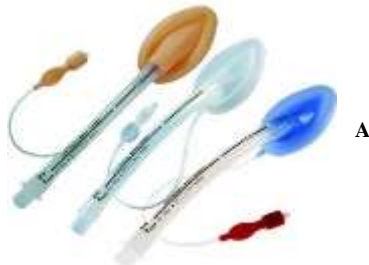
Figure 14: A) laryngeal mask airway; B) Multiple Lumen Esophageal Airway (Combitube).

That is why the American Society of Anaesthesiologists, advices to limit attempts of 3 times, if procedures kept failing to switch to other alternatives and use of special aids, laryngeal mask airway (Figure 14A). Or esophageal tracheal double lumen airway (Figure 14B). Along through, most frequent complication for intubation was esophagus intubation, comes hypotension in next (other complications with prevention and correction strategies) (Figure 15) [4, 5].

TABLE 29A-5 Complications of Endotracheal Intubation, Preventive Strategies, and Potential Corrective Actions		
Complication	Preventive Strategies	Corrective Action
ETT misplacement	View ETT entry through glottis	Quick recognition. Remove and replace ETT.
ETT dislodgement	Secure ETT, minimize patient movement, use continuous capnography	Quick recognition. Remove and replace ETT.
Mainstem intubation	View ETT entry through glottis, know appropriate ETT depth	Quick recognition. Adjust ETT position.
Oxygen desaturation	Preoxygenate patient prior to intubation	Verify ETT position. Clear ETT. Hyperventilate.
Hypotension	Ensure adequate blood pressure before intubation efforts, minimize use of medications known to induce hypotension	Place patient in Trendelenburg position. Give IV fluids. Give pressors. Avoid hyperventilation.
Bradycardia	Ensure adequate heart rate before intubation efforts	Hyperventilate. Give atropine or epinephrine.
Cardiac arrest	Ensure adequate heart rate, blood pressure, oxygen saturation before intubation efforts	Initiate CPR.
Aspiration	Avoid aggressive BVM ventilation, keep patient upright before intubation	Large-bore suction or oropharynx and ETT.
Injury to oropharynx or hypopharynx	Careful laryngoscopy	
Pneumothorax	Careful laryngoscopy, avoid aggressive BVM ventilation	Insert chest tube or pigtail.
Gastric/visceral perforation	Careful laryngoscopy, avoid aggressive BVM ventilation	
Vocal cord injury	Careful laryngoscopy, careful ETT placement	
ETT cuff leak	Check cuff before intubation, avoid rubbing cuff against teeth	Remove and replace ETT.
ETT obstruction (secretions, vomitus, foreign body)	Suction oropharynx before intubation efforts	Suction ETT. Clear obstruction.
Hyperventilation	Judicious control of manual ventilations	
Interruptions in CPR chest compressions	Minimize CPR interruptions during intubation, use a supraglottic airway instead of ETT	
Failed intubation/Inability to intubate	Anticipate and plan for intubation difficulty	Immediate rescue with supraglottic or other airway.

Figure 15: Complications of Endotracheal Intubation with Correct Actions.

In 1980, 11% of brain death cases raise a claim of esophagus intubation, number decreased to 3% in 1990 after invention of end-tidal CO₂ monitoring (ETCO₂, Figure 16). This doesn't mean misplacement wasn't occurring anymore, more clearly, it was corrected due the detection by CO₂ monitor. In some study, auscultation, ETCO₂, self-inflating bulb and transillumination using torchlight were all used to determine which one is more reliable in ETT insertion, ETCO₂ was best for verification the proper placement, but poorer outcomes showed with people of cardiac arrests.



Figure 16: End-tidal CO₂ Monitoring.

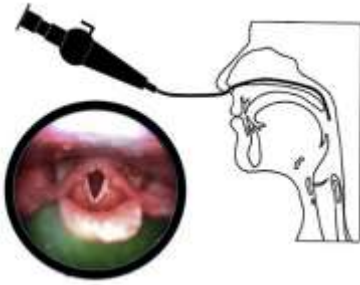


Figure 17: Fiberoptic Evaluation technique.

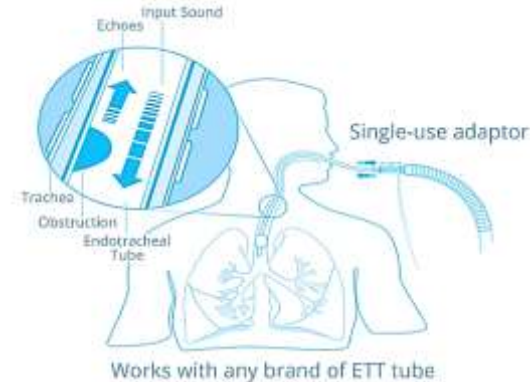


Figure 18: Acoustic Reflectometry.

So, what could make an excellent choice for cardiac arrest patients? X-rays are of limited value, because delay of diagnosis. Fiberoptic evaluation (Figure 17) needs special equipment and preparation, hence, time consuming. Acoustic reflectometry (Figure 18) shows promising results with experienced hands, Raphael and colleagues made a study on 200 adults intubated with acoustic reflectometry, having a 99% correct endotracheal intubation, 100% esophageal intubation detection [6-8].

The ETT displacement is common among inexperienced anaesthetics, but being unrecognized is actually rare, most of these cases arise due neglecting use of confirmation procedures and could be easily fixed if noticed. Confirmation procedures as vocal cords visualization while installing the tube, CO₂ detectors, equal chest expansion, auscultation, ultrasound and radiographs could all prevent the displacement. Unfortunately, problem may appear after following some clinical procedures because lack of experience, thus it needs more training to reach practicality. Sometimes, issue connected to cognitional factors, top 3 that were identified are: fixation error, confirmation bias and overconfidence.

For example, fast air flowing to stomach may mistake the practitioner that tube is inserted correctly, mechanical ventilator tidal volume if high might be mistaken as breath sound as leakage of NG tube prevents abdomen distention. In some settings, lack of proper equipment as ET/CO₂ monitors caused delayed detection, further death [9-11].

Conclusion and Recommendations

Intubation is a daily procedure, and emergency intubation usually involves patients with cardiac or pulmonary arrests, and as esophagus

intubation is most common complication but with less reliability to arrest patients using ET/CO₂, alternative gold standard method should be defined. Intubation in emergency settings require a good preparation, available equipment (e.g. ready cart for all time), and supportive anatomical airway of the patient.

Following a checklist will improve outcomes, prevent malpractice and complications. Preoxygenation and RSI play major roles for successful intubations with decreased complications. Follow procedure steps, and expect difficult intubation for any patient, so consider LEMON mnemonic to evaluate risk of difficulty, and after 3 attempts try a different technique or equipment. More training and education are essential to decrease congenital and equipotential mistakes/errors. Workplace should be supportive with adequate materials and space.

REFERENCES

1. TINTINALLI'S Emergency Medicine 9th edition.
2. Hart D, Clinton J, Anders S, Reihisen T, McNeil MA et al. (2016) Validation of an Assessment Tool for Field Endotracheal Intubation. *Mil Med* 181: e1484-e1490. [Crossref]
3. Elbaih AH, Taha M, Elsakaya MS, Elshemally AA, Alshorbagy ME (2019) Assessment of cardiopulmonary resuscitation knowledge and experiences between emergency department nurses hospital pre and post basic life support training course, Egypt. *Ann Med Res* 26: 2320-2327.
4. Pruitt B (2019) Emergency intubations are almost always associated with cardiac or respiratory arrest in hospitalized patients and often occur during intense resuscitation activities.
5. Elbaih AH, Elsayed ZM, Ahmed RM, Abd Elwahed SA (2019) Sepsis patient evaluation emergency department (SPEED) score & mortality in emergency department sepsis (MEDS) score in predicting 28-day mortality of emergency sepsis patients. *Chin J Traumatol* 22: 316-322. [Crossref]
6. Kumar N, Kumar A, Dubey PK, Kumar S (2018) Delayed detection of esophageal intubation: Nasogastric tube was the cause? *Saudi Crit Care J* 2: 27-28.
7. Krafft P, Frass M (2007) Airway Management in Intensive Care Medicine. *Benumof's Airway Management* 1016-1054.
8. Elbaih AH, Basyouni FH (2020) Teaching Approach of Primary Survey in Trauma Patients. *SurText Rev Surg* 1: 1-7.
9. Mansfield JP, Wodicka GR (1995) Using Acoustic Reflectometry To Determine Breathing Tube Position And Patency. *J Sound Vibration* 188: 167-188.
10. Boqué MC, Gualis B, Sandiumenge A, Rello J (2004) Endotracheal tube intraluminal diameter narrowing after mechanical ventilation: use of acoustic reflectometry. *Intensive Care Med* 30: 2204-2209. [Crossref]
11. Elbaih AH, El Sayed DA, Abou Zeid AE, Elhadary GK (2018) Patterns of brain injuries associated with maxillofacial fractures and its fate in emergency Egyptian polytrauma patients. *Chin J Traumatol* 21: 287-292. [Crossref]