

Available online at [www.sciencerepository.org](http://www.sciencerepository.org)

Science Repository



## Case Report

# Three-Dimensional Biomodels: Use of Different Materials for the Surgical Planning in Relation to Two Mandibular Cysts Cases

Astigueta José Mariano<sup>1,2\*</sup>, Mendoza Cuello Norbin José<sup>1,2</sup>, Benitez Javier Alejandro<sup>1,2</sup>, Attaguile Alberto<sup>1,2</sup> and Giannunzio Graciela Ana<sup>1,2,3</sup>

<sup>1</sup>Department of Oral and Maxillofacial Surgery, HZGA General Manuel Belgrano, San Martín, Buenos Aires, Argentina

<sup>2</sup>Maxillofacial Surgery Fellowship, Universidad Católica Argentina, CABA, Argentina

<sup>3</sup>Head of Department of Oral and Maxillofacial Surgery, HZGA General Manuel Belgrano, San Martín, Buenos Aires, Argentina

### ARTICLE INFO

#### Article history:

Received: 21 September, 2020

Accepted: 5 October, 2020

Published: 15 October, 2020

#### Keywords:

Three-dimensional imaging

three-dimensional printing

mandibular diseases

osteosynthesis

mandibular biomodel

### ABSTRACT

**Introduction:** The use of three-dimensional models in the diagnosis, planification and treatment of the maxillofacial area pathology has been included in publications since 1980, and has enabled to minimize surgical time, reducing peri and postoperative morbidity, and optimizing surgical results. Currently, the market offers a huge range of 3D printers and materials which allows biomodels to be printed for medical purposes. The purpose of the following paper is to describe the use of two types of three-dimensional models in the therapeutic planning of two cases of mandibular cysts.

**Case Report:** Two cases of mandibular dentigerous cysts are described, in which osteosynthesis plates were used to prevent pathological fractures, pre-modeled together with acrylic positioners on three-dimensional models and printed in different ways. Postoperative clinical and tomographic controls were performed.

**Conclusion:** The knowledge of the properties of the different materials available for the construction of three-dimensional models allows selecting the one that best suits the case needs required, minimizing surgical times and optimizing the results.

© 2020 Astigueta José Mariano. Hosting by Science Repository.

## Introduction

Nowadays, introducing technology to all medical fields is a necessity, such as during diagnostic procedures like the planning and treatment of pathologies that take place in different medical and dental specialties. Within the Oral and Maxillofacial Surgery (OMFS) field, the arrival of different imaging techniques (helical CT scan, cone-beam computed tomography [CBCT], magnetic resonance, etc.) and a wide range of software options to carry them out have transformed the methodology used for diagnostics, therapeutic planning, and postoperative follow-ups of all the pathologies this speciality covers [1, 2]. These technological advances have forced professionals to enter the virtual world, demanding improved surgical times and results, and reducing peri and postoperative morbidity [3]. A clear example of the use of technology in OMFS is the making of 3D models for guidance and assistance during surgical

procedures. Three-dimensional models, largely known as stereolithographic models or biomodels, have been used for different purposes since their development [1-3].

The making of three-dimensional models using tomographic images started in 1980, and the first registry of a craniofacial model was published in 1986 [2-5]. Chuck Hull patented the Stereolithography in 1984 and defined it as a method of object solidification by successively “printing” thin layers of the ultraviolet (UV) curable material, one on top of each other [1, 3, 6]. In 1986, Hull founded 3D systems and started to sell 3D printers and printing materials for diverse purposes, being widely used in the automotive industry [1, 3]. Then, new, and cheaper printing methods of three-dimensional models started to be used, such as the fused deposition modeling (FDM), which was developed and patented by Scott Crum in 1992 under the brand name Stratasys [2]. Nowadays,

\*Correspondence to: Astigueta José Mariano, D.D.S., Trainee, Maxillofacial Surgery Service, HZGA General Manuel Belgrano, San Martín, Buenos Aires, Maxillofacial Surgery Fellowship, Universidad Católica Argentina, CABA, Argentina; E-mail: [marianoastigueta@hotmail.com](mailto:marianoastigueta@hotmail.com)

there is a vast supply of three-dimensional printers on the market with multiple materials of different costs and characteristics for the acquisition of biomodels for medical purposes.

The printing process for medical or dental models begins with tomographic images, which are edited to add/subtract elements, extract impurities, and isolate anatomical structures of interest with digital design programs. These images are depicted on DICOM format (Digital Imaging and Communications in Medicine); however, to be processed

by 3D printing programs, they need to be converted into Standard Tessellation Language (STL) format [1-3]. Mechanical properties of 3D-printed parts can be affected by the manufacturing method (Table 1). Each material has advantages and disadvantages and will be used according to the desired outcome [1, 3]. Stereolithographic models (Figure 10) are made by UV-photo-curable acrylic or epoxy resin. The process begins when the platform moves below a vat which holds this liquid photopolymer.

**Table 1:** Comparison of 3D model production techniques.

	Photochemical elements		Extrusion	Grainy texture
Method of production	Photopolymerization through UV light	Photopolymerization through UV light	Fused deposition modeling	Binder Jetting
Materials	Acrylics	Epoxy resin	PLA – ABS (among others)	Gypsum plaster, metal, sand
Properties	Photochemical properties	Photochemical properties	Thermoplastics	Powder
Choice of color	YES	NO	NO	YES
Sterilization	YES	NOT RECOMMENDED	NO	NOT RECOMMENDED
Cost	250 dol.	250 dol.	10 dol.	250 dol.

With the help of a computer-aided design software integrated with the STL files, the UV laser solidifies this material, with a layer thickness of 0.05 to 0.15 mm. This process is repeated for each layer of the design until the 3D object is complete. At the end of the process, the model is placed in a UV oven for final curing [1, 3, 6]. With Binder Jetting technology, a binder is deposited onto the powder bed, bonding these areas together to form a solid part. The materials commonly used in Binder Jetting are gypsum plaster, sand, ceramics, metals, and polymers that come in a granular form. The printing process begins with a rotating roller spreading a thin layer of powder over the build platform; then, a carriage passes over the bed depositing droplets of a binding agent of approximately 80 µm. This binder agent glues the powder particles together and the process then repeats until the whole part is complete (Figure 4). After printing, the part is removed from the powder bin, cleaning the excess, and is left to cure and gain strength [2].

Three-dimensional printers with FDM technology use thermoplastic polymers such as the Acrylonitrile Butadiene Styrene (ABS) or the polylactic acid (PLA). These substrates are significantly cheaper but with more limited properties. The printers work by melting the thermoplastics' filaments with a diameter of 1.75 mm to 3 mm. These filaments that are led by a digital program integrated by STL files create layer by layer on the machine platform. Therefore, a three-dimensional model that is faithful to the tomographic images is obtained [1-3, 6].

Stereolithographic models polymerized by UV light offer mechanical strength and thermal stability. This technique allows starting with the drilling process for the pre-selection of screws, the cutting process to delimit resections and the sterilization using autoclave or ethylene oxide, which makes possible its use during the surgery. These models also present a lower moisture absorption and lower shrinkage rate, which permits to create a high level of fidelity of the tomographic images in shape and size [1, 3, 7]. The models made by Binder Jetting technique present a granular texture. Often, these models are superficially

impregnated with resin to gain strength and impermeability, which allows them to be sterilized using ethylene oxide. Cutting or drilling processes make the powder fall from the model, causing a significant deformation, so the osteosynthesis plate can be pre-molded but the selection of screws and delimitation of resections is limited.

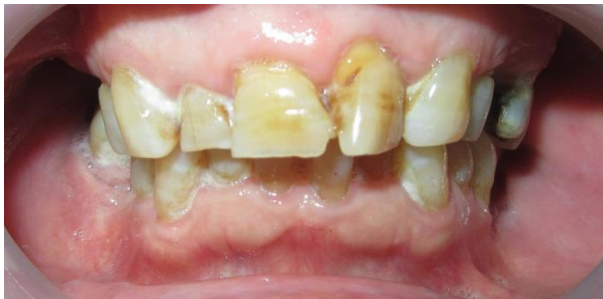The models made by FDM technique are useful for educational purposes, identification of anatomical structures, and pre-molding of titanium plates. However, since they are made of thermoplastic materials, they cannot be sterilized by conventional methods, and drilling process for the pre-selection of screws and cutting process causes a significant deformity on the model, which limits its function during the surgery planning. On the other hand, a key advantage of FDM over Stereolithography is that the elaboration cost is significantly lower (Table 1) [1-3, 6]. For years, this type of technology was only accessible at high complexity centers. Nowadays, the gold standard for any maxillofacial surgery requires at least one computed tomography. This tomography enables the making of three-dimensional models, with a great variability of materials and printers suitable for making biomodels. They have different costs and features and are accessible in most health care centers.

The purpose of this paper is to describe the use of different three-dimensional models during the therapeutic planning of two cases of mandibular cystic pathology.

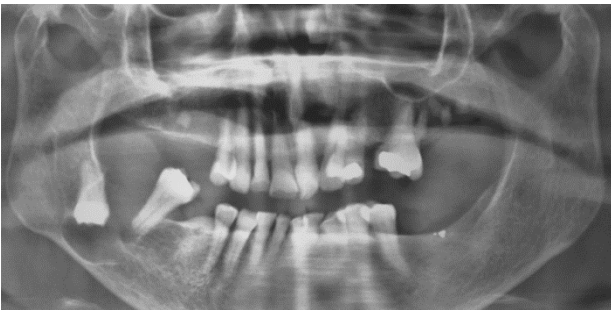### Case 1

A 78-year-old female patient attended the Maxillofacial Surgery Service of the HZGA Gral. Manuel Belgrano because of a painful swelling in the right side of the posterior area of the mandible. The adjacent mucosa was normal (Figure 1). Panoramic radiograph revealed the presence of an osteolytic image associated with tooth 4.8 (Figure 2). A serial incisional biopsy was carried out and the histopathological evaluation confirmed

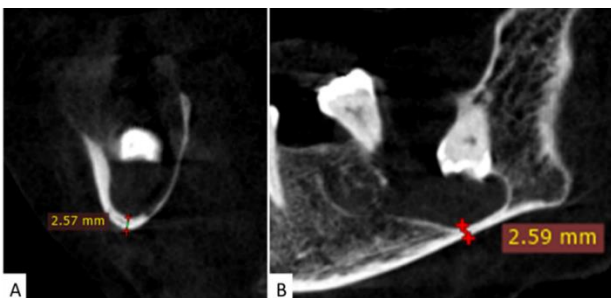
the diagnosis of dentigerous cyst. For the surgical planning, a CBTC was requested. The CT scan was performed by a Planmeca Promax 3D device that revealed a hypodense image at the posterior body and right ramus of the mandible measuring 26 x 25 x 24 mm; with a hyperdense image compatible with tooth 4.8 on its inside and basal displacement of the inferior alveolar ducts. Since the basal buttress around the injury presented a thickness of 2.6 mm (Figure 3), it was decided to use a mandibular reconstruction plate during the surgical treatment to prevent a possible pathologic fracture [8].



**Figure 1:** Initial clinical image. Vestibular inflammation of the right side of the mandible. Mucosa looks normal.



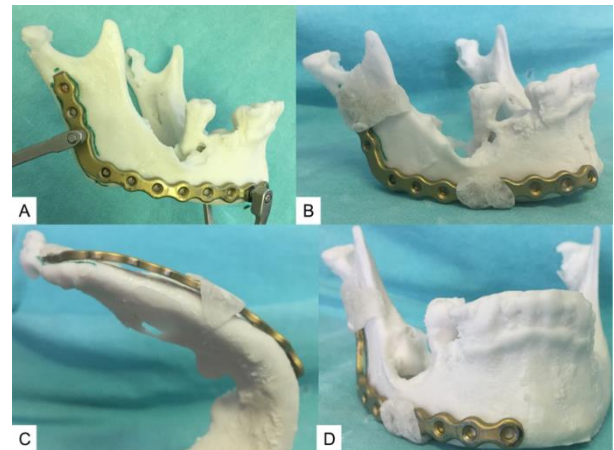
**Figure 2:** Initial panoramic radiograph. Radiolucent image associated with retained tooth 4.8.



**Figure 3:** Case 1 initial CBCT. **A)** Coronal section shows a hyperdense image at the center of the lesion compatible with retained tooth; basal thickness measuring 2.57 mm. **B)** Sagittal section shows included in the posterior side of the lesion; basal thickness measuring 2.59 mm.

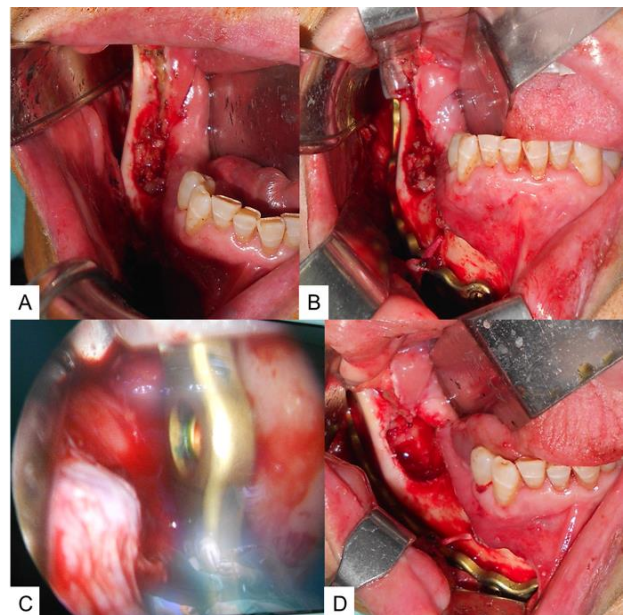
A three-dimensional model was made through CBTC images by injecting liquid binder (Binder Jetting) with a 3D Systems Projet 360 print (Figure 4). The material chosen for this model was VisiJet PXL, which was superficially impregnated with resin to gain strength and impermeability. The locked mandibular reconstruction plate from the 2.4 system was pre-molded on the tridimensional model. The selection of screws was based on the CBCT, since the drilling process can make material fall from powder-based models. Two self-cure acrylic positioners were made for the osteosynthesis plate. One of them was made on the mandibular ramus with retentions around the osteosynthesis

plate, and holdings placed on the posterior border, anterior border, and the mandibular notch. The second one was made with a retention around the anterior holes of the plate and a holding on the mandibular basal bone (Figure 4).



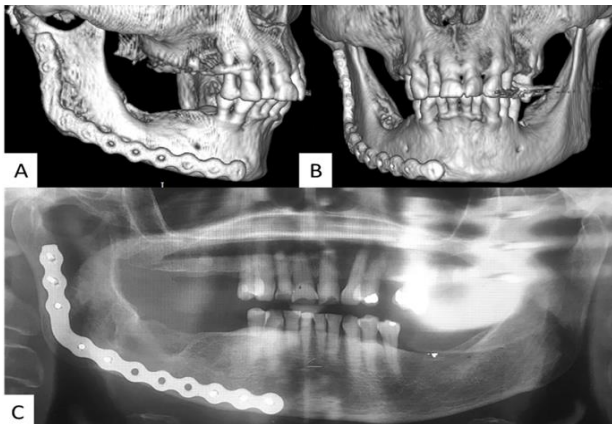
**Figure 4:** Case 1 three-dimensional model made by VisiJet PXL through the Binder Jetting technique. **A)** Pre-molded mandibular reconstruction plate. **B), C) & D)** Crystal self-curing acrylic positioners.

The surgical treatment was carried out under general anaesthesia, with an intraoral approach on the anterior border of the ramus of the mandible and the vestibular extension up to tooth 4.1 (Figure 5A). Through video-endoscopy assistance, the plate was fixed and positioned with the acrylic devices (Figures 5B & 5C). During the procedure, the surgeon had to adapt the plate due to little poor adjustments. Then, cystic enucleation and tooth extraction was done (Figure 5D). The material was sent to the anatomic pathology laboratory, which confirmed the diagnosis. The postoperative result was evaluated through a panoramic radiograph and a computed tomography, which showed a proper adaptation of the osteosynthesis material (Figure 6).



**Figure 5:** **A)** Approach on the anterior border of the ramus with vestibular extension. **B)** Fixation of mandibular reconstruction plate with acrylic positioners. **C)** Video-endoscopy assistance. **D)** Cystic enucleation and dental extraction of the retained tooth.

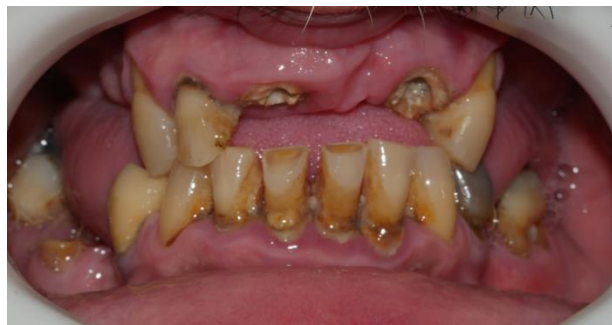



**Figure 6:** Case 1 postoperative images (6 months). **A) & B)** 3D volumetric reconstruction. **A), B) & C)** Panoramic radiograph. All the images show a proper adaptation of the osteosynthesis plate and bone resorption.

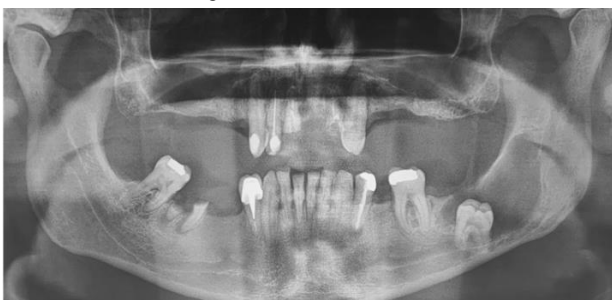**Case 2**

A 50-year-old male patient was referred to the Maxillofacial Surgery Service of the HZGA Gral. Manuel Belgrano due to an osteolytic image found in his panoramic radiograph. The clinical examination showed a poor state of his oral health, with absence of tooth 3.7 (Figure 7).



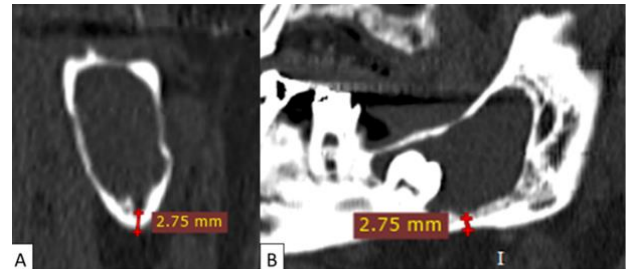
**Figure 7:** Intraoral image. Overall poor oral health. Clinical absence of tooth 3.7.

This image showed a radiolucent area in the posterior body and left ramus of the mandible associated with a radiopaque structure compatible with a retained tooth (Figure 8).



**Figure 8:** Initial panoramic radiograph. Radiolucent image in body and left ramus of the mandible with dental piece included in the lesion.

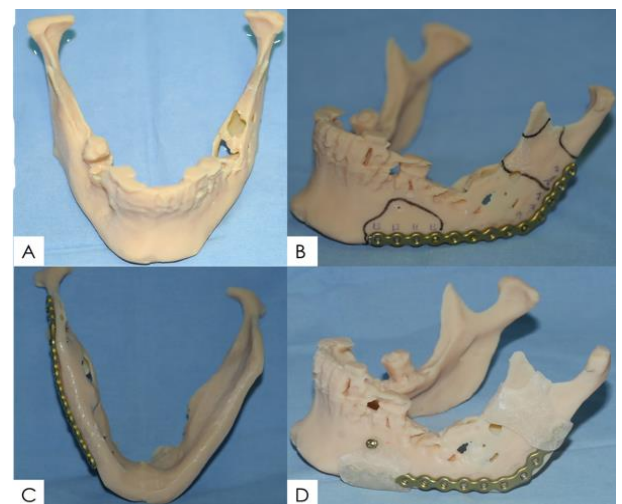
A serial incisional biopsy was performed with a histopathological result of a dentigerous cyst. A CBCT was requested for the surgical planning, which was performed on a Planmeca Promax 3D. This scan showed a hypodense image on the left side of the mandible, measuring 40 x 24 x 13 mm. Inside the lesion, a hyperdense image was observed at the anterior edge of the mandible, compatible with a retained tooth. A basal displacement of the inferior alveolar ducts was detected, with a superior cortex fenestrated connected to the lesion. The basal buttress thickness was 2.75 mm, so it was decided to place a mandibular reconstruction plate to avoid a possible pathological fracture (Figure 9) [8].



**Figure 9:** Case 2 initial TC. **A)** Coronal plane shows a fenestration of the superior cortical of the inferior alveolar duct; basal thickness measuring 2.75 mm. **B)** Sagittal section shows retained dental piece at anterior edge of the lesion; basal thickness measuring 2.75 mm.

**Table 2:** Materials for the stereolithographic model-Case #2.

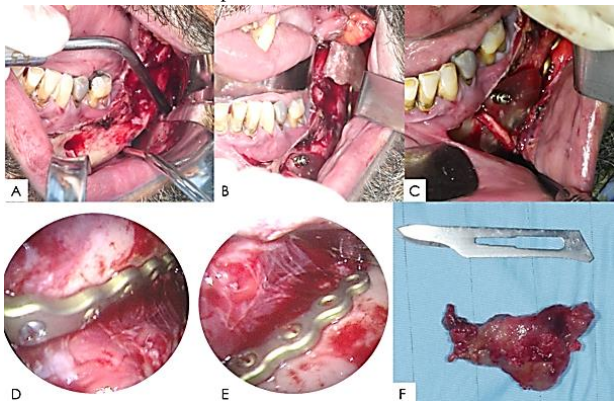
CASE 2 STEREO LITHOGRAPHIC MODEL	
Material	Amount (%)
Acrylate monomer	30
2-Propenoic acid, 1,7,7-trimethylbicyclo ester	25
Acrylate oligomer	15
Photoinitiator	3
Titanium dioxide	0.8
Esters of acrylic acid	0.3
CARBON BLACK	1
Xylenes (o-, m-, p.isomers)	0.1
n-Butyl acetate	0.1
Ethylbenzene	0.1
Propylene Glycol Methyl Ether Acetate	0.1
Phosphoric acid	0.002
Others	14.5



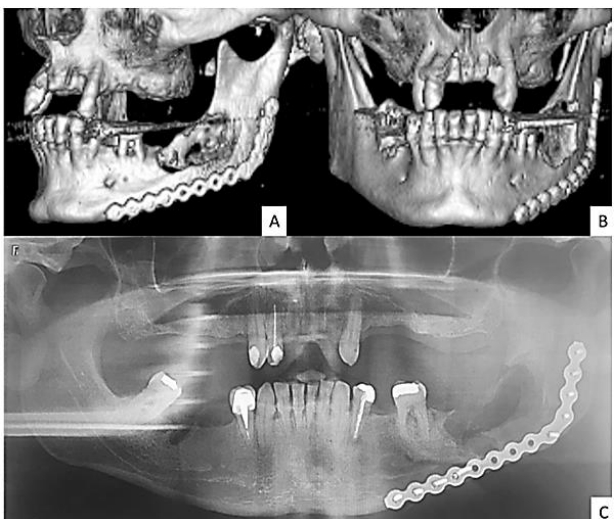
**Figure 10:** **A)** An acrylic stereolithographic model. **B)** Pre-molding of mandibular reconstruction plate and selection of screws. **C)** Adaptation of mandibular reconstruction plate to the contour of the mandible. **D)** Adaptation of mandibular reconstruction plate to the contour of the mandible.

Crystal self-curing acrylic positioners, the anterior fixed on with an IMF screw.

A photo-curing acrylic stereolithographic model was made (Table 2) based on CBCT images (Figure 10). The printer used was Stratasys Eden Dental Selection, specific for dentofacial biomodels. On the model, a 2.0-mm locking mandibular reconstruction plate system was pre-molded. The corresponding perforations and selection of the screws size were also carried out (Figure 10). Two self-cure acrylic positioners were made after the plate was molded. The posterior presented retentions around the osteosynthesis plate, and holding placed on the posterior border, anterior border, and the mandibular notch. The anterior showed retentions around the plate, holding around the basal, and a hole for an IMF screw, having measured it in the CBCT to avoid dental or nerve lesions (Figure 10). The use of the fixation screw for the positioner was required since the model did not have a copy of free occlusal surfaces because it was made on a patient in occlusion.



**Figure 11:** A) Intraoral incision. B) Osteosynthesis plate with acrylic positioners. C) Fixation of the anterior positioner with an IMF screw. D) & E) Video-endoscopy assistance. F) Cyst membrane macroscopy



**Figure 12:** Case 2 postoperative images (2 weeks). A) & B) Tomographic volume reconstruction. C) Panoramic radiograph. All the images show a proper adaptation of the osteosynthesis material.

The surgical treatment was carried out under general anaesthesia, with an intraoral approach on the anterior border of the left ramus of the mandible and vestibular extension up to tooth 3.2, curettage of mucoperiosteal flap and exposure of the lesion (Figure 11A). The

reconstruction plate and the positioners were taken and the anterior was fixed with an IMF screw, as planned (Figures 11B & 11C). Through video-endoscopy assistance, their position was ensured, and the plate was fixed and positioned with preselected screws (Figures 11D & 11E). Cystic enucleation and tooth extraction were carried out, then the material was sent to the pathological anatomy laboratory, which confirmed the diagnosis (Figure 11F). The postoperative result was evaluated through a panoramic radiograph and computed tomography, which showed a proper adaptation of the osteosynthesis to the contour of the mandible (Figure 12).

## Discussion

The use of three-dimensional models for diverse maxillofacial pathologies is widely explained throughout the scientific literature. The advantages attributed to three-dimensional assisted surgery are identifying anatomical structures, measuring, and delimitating resections, pre-contouring osteosynthesis plates and selecting the corresponding screws, and designing and positioning the cutting guides. These steps involve a meticulous surgical planning, which results in a reduced surgery time up to 1.5 hours in the operating room [2, 3]. Greater precision during the planning and shorter operating times reduce per and postoperative morbidity and provide greater predictability in the results [3, 6, 7, 9].

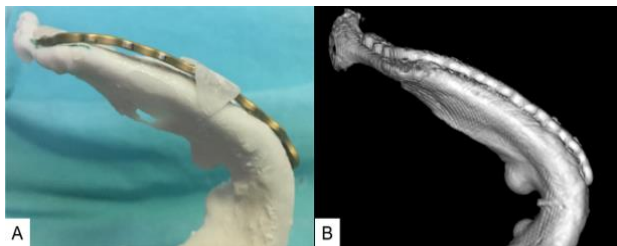
The use of biomodels at university hospitals with oral and maxillofacial training programs presents a great academic applicability [2, 10]. These two cases were used by staff surgeons at the Maxillofacial Surgery Service for academic teaching of trainee in the preoperative planning phase. This allows surgeons getting familiar with the anatomy of the lesion and forces them to choose an approach that will enable adapting the pre-molded plates to their positioners on the patient, reducing risks during the procedure.

It is important to know the materials and the production technique of these types of models since not all of them have the same properties (Table 1). Biomodels are frequently requested from the patient's medical insurance, and the surgeon must know the laboratory that will print it to ensure that it meets the required needs [2, 3].

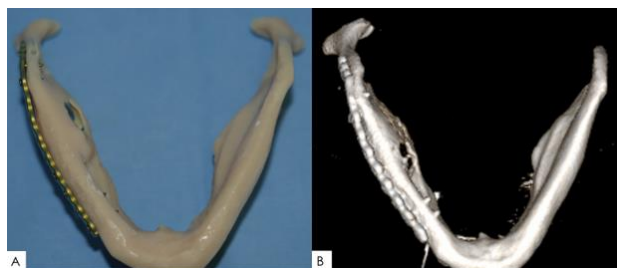In Case 1, a model made by Binder Jetting technique (Figure 4) was used. In this technique, a binding liquid is deposited to join powder material together to duplicate tomographic images. It is usual that, after printing, the parts are impregnated with resin so that the powder stays on the surface of the model. This process diminishes the gas absorption and allows its sterilization. Thanks to this manufacturing technique, it was possible to pre-mold the plate and design the positioners, but the selection of screws was limited by the impossibility of drilling on the model. Due to some discrepancies, during the surgical procedure adjustment of the plate was required. This may be related to not having selected the screws in the preoperative phase or to a lack of fidelity of copying the tomographic images to the model. The postoperative tomography reveals a correct adaptation of the osteosynthesis material to the contour of the mandible (Figure 13).

In Case 2, a stereolithographic model was used (Figure 10), a technique that uses polymerization of acrylics using UV-light (Table 2). The printer used was Stratasys Eden DS, a specific printer for dentofacial

models. Through this printing technique, a unique piece is obtained, which presents a lower moisture absorption and lower shrinkage. This model presented a smooth surface with no pores. Thanks to the polymerization through UV light, a stereolithographic model is heat resistant and tolerates conventional methods of sterilization (autoclave or ethylene oxide). The drilling or cutting of the models, whether for the pre-selection of the screws or to establish limits for the resection, does not cause a significant deformation, allowing a more exact surgical planning. During the surgery, the plate and positioners could adapt without complications (Figure 14). Postoperative tomographic images and panoramic radiography reveal a correct adaptation of the osteosynthesis material to the contour of the mandible (Figure 12).



**Figure 13:** Osteosynthesis plate adaptation Case 1. **A)** Pre-molding of the osteosynthesis plate in a three-dimensional model (Binder Jetting technique). **B)** Postoperative CT with greater adaptation of the plate with respect to planning.



**Figure 14:** Osteosynthesis plate adaptation Case 2. **A)** Pre-molding of the osteosynthesis plate in an acrylic stereolithographic model (polymerization by UV light). **B)** Postoperative CT with adaptation equivalent to planning.

In both cases, the CBCT was performed on patients in occlusion, so the occlusal surfaces did not show in the images used for the making of the models. Due to this, the acrylic positioners did not hold on the occlusal surface of the teeth, and in Case 2, the use of an IMF screw to fix the positioner was necessary. For this type of intervention, the authors of this paper suggest performing the CBCT on an open mouth. The making of self-cure acrylic positioners and the pre-molding of the mandibular reconstruction plate allowed solving both cases through an intraoral approach, resulting in a proper adaptation of the osteosynthesis material and a low cost added to the procedure (Figure 12). The models made

through the fused deposition modeling (FDM) technique are useful for teaching methods and identification of anatomic structures, and its production cost is significantly lower. The disadvantage is these models are made with thermolabile materials. The authors consider that the use of the FDM technique is limited for the surgical planning since these models cannot be sterilized.

## Conclusion

Knowledge on the materials available for the making of three-dimensional mandible models allows solving cyst pathology cases that require the use of osteosynthesis, reducing operating time and added value to the procedure.

## REFERENCES

1. Mehra P, Miner J, D'Innocenzo R, Nadershah M (2011) Use of 3-D Stereolithographic Models in Oral and Maxillofacial Surgery. *J Maxillofac Oral Surg* 10: 6-13. [[Crossref](#)]
2. Mantrana GA, Jacobo O, Hartwig DK, Giachero V (2018) Three-Dimensional printing models in the preoperative planning and academic education of mandible fractures. *Cir Plast Iberolatinoam* 44: 193-201.
3. Cunningham LL, Madsen MJ, Peterson G (2005) Stereolithographic Modeling Technology Applied to Tumor Resection. *J Oral Maxillofac Surg* 63: 873-878. [[Crossref](#)]
4. Abe M, Tabuchi K, Goto M, Uchino A (1998) Model-based surgical planning and simulation of cranial base surgery. *Neurol Med Chir (Tokyo)* 38: 746-750. [[Crossref](#)]
5. Berry E, Brown JM, Connell M, Craven CM, Efford ND et al. (1997) Preliminary experience with medical applications of rapid prototyping by selective laser sintering. *Med Eng Phys* 19: 90-96. [[Crossref](#)]
6. Chow LK, Cheung LK (2007) The Usefulness of Stereomodels in Maxillofacial Surgical Management. *J Oral Maxillofac Surg* 65: 2260-2268. [[Crossref](#)]
7. Wong TY, Fang JJ, Chung CH, Huang JS, Lee JW (2005) Comparison of 2 methods of making surgical models for correction of facial asymmetry. *J Oral Maxillofac Surg* 63: 200-208. [[Crossref](#)]
8. Lee H, Lee SJ, Seo BM (2019) Investigation of Postoperative Complications of Intrabony Cystic Lesions in the Oral and Maxillofacial Region. *J Oral Maxillofac Surg* 77: 1823-1831. [[Crossref](#)]
9. Gutierrez Ventura F, Robles Apac R (2013) Stereolithography in maxillofacial surgery. *Rev Estomatol Herediana* 23: 216-222.
10. Watson RA (2014) A Low-Cost Surgical Application of Additive Fabrication. *J Surg Educ* 71: 14-17. [[Crossref](#)]