

Available online at [www.sciencerepository.org](http://www.sciencerepository.org)

Science Repository



## Research Article

# The Utilization of a Nitric Oxide Generating Serum for Improving Vascularity in Wound Healing

Greg Chernoff<sup>1,2,3\*</sup>

<sup>1</sup>Ascension St. Vincent Hospital, USA

<sup>2</sup>Chernoff Cosmetic Surgeons, Indiana, USA

<sup>3</sup>Chernoff Cosmetic Surgeons, California, USA

### ARTICLE INFO

#### Article history:

Received: 18 August, 2020

Accepted: 24 September, 2020

Published: 28 September, 2020

#### Keywords:

Nitric oxide (NO)

wound healing

regenerative medicine

### ABSTRACT

**Introduction:** Poor vascularity in injured or operated tissue predisposes the patient to poor healing. Many disease states such as diabetes mellitus, atherosclerosis, and Raynaud's Disease exhibit delayed or compromised healing. Post-radiated tissue is another example of poor healing potential. Any surgical wound, local, regional, or free flap reconstruction, can see delayed healing or lack of healing with poor blood supply. Nitric oxide (NO) is an endothelial cell, endogenously produced, free radical gas. It is a potent vasodilator and inhibitor of platelet aggregation. A NO producing serum has recently been developed (Pneuma Nitric Oxide, Austin Texas). This is the first study to examine the potential efficacy of a NO generating serum in the wound healing population.

**Objective:** The objective of this study is to examine the potential efficacy of a Nitric oxide generating serum in the wound healing patient population

**Method:** Twenty-five patients were studied in two centers between December 2018 and June 2020. Prior to utilizing NO serum, a double-blind, placebo controlled (glycerin) safety study was performed on 10 patients. There were no allergic or irritation reactions to NO serum in this population. NO serum was applied to non-healing diabetic ulcers, vascular compromised non-healing wounds, surgical incisions, split thickness grafts, full thickness grafts, regional and free flaps. Patients were followed weekly and photographed regularly to monitor healing until total healing was reached.

**Results:** Without exception, the study population showed a more rapid and improved quality of healing in the wounds that were treated with Nitric oxide generating serum as compared to control sites. Rapid re-epithelialization, wound contraction, less bruising and edema were commonly seen. Neo-vascularization was more rapid in surgical flap cases. Burn wounds healed dramatically.

**Conclusion:** This study shows the benefits of a Nitric oxide- generating serum in the wound healing patient population. The vasodilatory and capillary recruitment capabilities of Nitric oxide are hypothesized as key factors leading to this improved healing. NO is also paramount in the differentiation and proliferation of fibroblasts, keratinocytes, monocytes, and macrophages. Topically, NO has also been shown in the literature to have strong anti-bacterial, anti-fungal, and anti-viral roles. NO serum is a valuable addition to the armamentarium of wound healing protocols.

© 2020 Greg Chernoff. Hosting by Science Repository.

\*Correspondence to: Greg Chernoff, B.Sc., M.D., F.R.C.S.(C), Ascension St. Vincent Hospital, Chernoff Cosmetic Surgeons, Private Practice, 9002 N Meridian Street, Suite 205, Indianapolis, Indiana 46260, Chernoff Cosmetic Surgeons, Private Practice, 3540 Mendocino Avenue, Suite 300, Santa Rosa, California 95403, USA; E-mail: [greg@drchernoff.com](mailto:greg@drchernoff.com)

**Introduction**

A lack of vascularity is detrimental to wound healing. Many disease states such as diabetes, renal failure, and atherosclerosis, predispose a patient to delayed or impeded healing. Diabetic ulcers remain a costly problem for medical insurance companies due to their prolonged and often unsuccessful courses. Surgical reconstructions, including skin grafts, local, regional, and free flaps, require an abundant recipient site blood supply for their success. Elective procedures such as rhytidectomy, mastopexy, breast reduction, and abdominoplasty are destined for failure if blood supply is compromised. Patients who continue to smoke, despite known surgical risks, often experience delayed healing, tissue breakdown, or tissue necrosis. With compromised vascularity, often expensive techniques such as hyperbaric oxygen treatments are implemented. While effective, numerous sessions at significant cost are typically required.

Much has been written on the benefits of nitric oxide. This free radical gas is produced endogenously in endothelial cells from arginine facilitated by the enzyme nitric oxide synthetase. Nitric oxide is a signaling molecule with importance in most enzymatic reactions in every organ of the body. It is a potent vasodilator and also inhibits platelet aggregation. The endogenous production of NO is reduced by over 50% when one reaches 40 years of age. As we lose the ability to generate NO with age, optimal bodily function declines. Oral NO supplementation has proven successful in aiding in the treatment of many conditions as well as improving general health.

A nitric oxide generating, dual-chamber serum, has recently been developed (Pneuma Nitric Oxide, Austin, TX). When equal amounts of each chamber are mixed, Nitric oxide is generated. The serum reached 15,000 ppb initially, exhibits a diffusion distance of 500 microns in human tissue, adequate for dermal penetration to the microcirculation of the upper horizontal plexus. Nitric oxide could still be detected 30 minutes after each application.

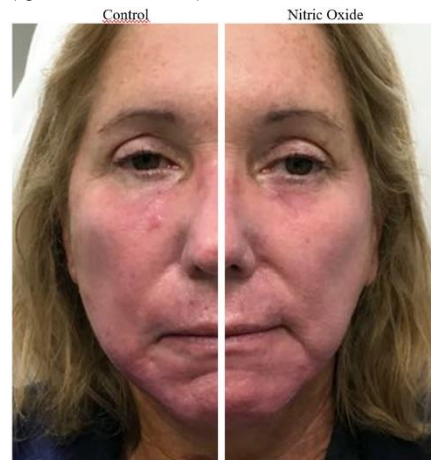**Methods**

Twenty-five patients with various wound healing scenarios were examined. Planned surgical incision sites were pre-treated and treated

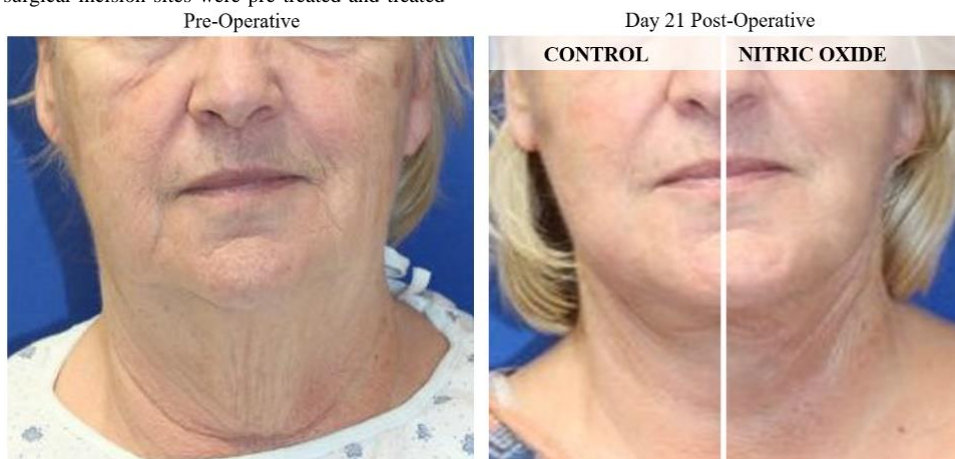daily after incision completion for 14 days. Healing surgical local, regional, and free flaps were treated topically for 14 days. Non-healing diabetic ulcers, burn wounds, and smoking- induced, vascular compromised wounds were examined. NO serum was applied 4 times daily. Photographs were taken daily for the surgical patients, and weekly for the remainder of the population to examine any benefit.

**Results**

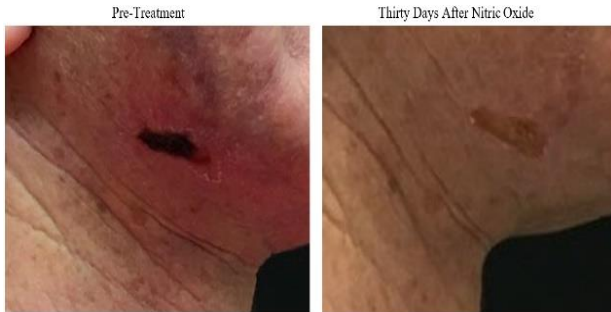The study population, without exception, showed excellent results. Rhytidectomy and blepharoplasty patients displayed less bruising, edema, and faster re-epithelialization on the treated side compared to the contralateral untreated control side (Figures 1 & 2). A full-thickness facial ulcer in a patient with compromised vascularity from smoking, re-epithelialized in 7 days (Figure 3). Local, regional, and free flaps showed improved vascularization and viability within 30 days (Figures 4 & 5). Previously non-healing burn wounds re-epithelialized by day 21 (Figure 6). Previously non-healing diabetic ulcers and pressure ulcers healed within 30-45 days (Figure 7). Figure 8 shows improved vascularity post NO generating serum application using the Quantificare Imaging System (QuantifiCare, France)



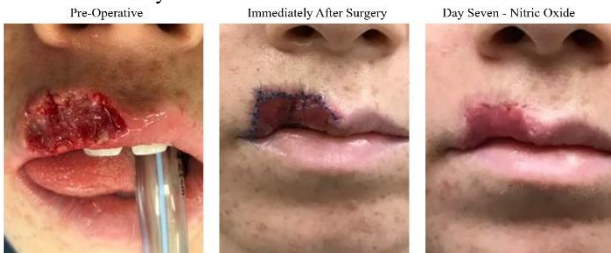**Figure 1:** 58-year-old female 14 days post-Browlift, Blepharoplasty, Rhytidectomy. NO serum side shows reduced edema, accelerated healing compared to placebo control.



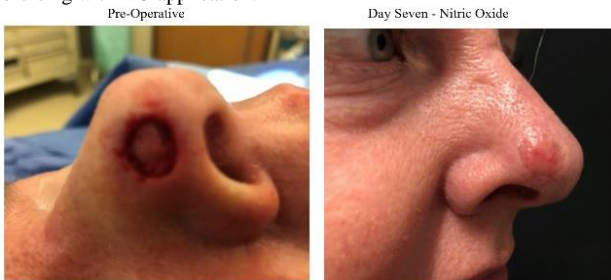**Figure 2:** 67-year-old female 21 days post Rhytidectomy shows reduced edema, accelerated healing on NO serum side compared to placebo control.



**Figure 3:** 66-year-old female, smoking-induced ulcer post-Rhytidectomy. Re-epithelialization at 7 days, ongoing healing and scar reduction at 30 days.



**Figure 4:** 28-year-old female status post dog bite reconstruction with local flaps. Marked improvement in vascularity, reduced edema, and bruising with NO application.

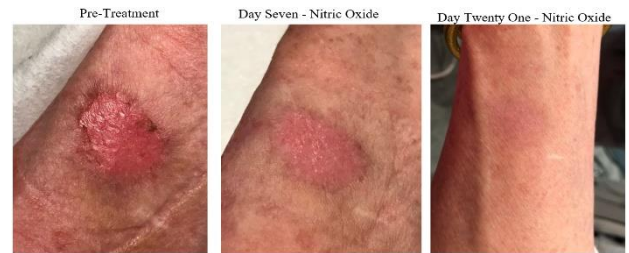

**Figure 5:** 36-year-old female, status post basal cell excision, full-thickness skin graft reconstruction. At 7 days post-op, neovascularization in healthy flap visualized.

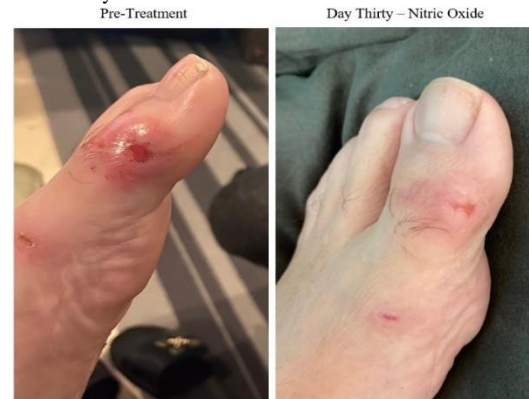**Discussion**

The fields of Cellular Medicine and Regenerative Therapy are growing rapidly [1]. There are tens of thousands of papers describing the health benefits of Nitric Oxide [2]. NO is an important biological messenger in human physiology. NO plays a role in vasodilation, capillary recruitment, and inhibition of platelet aggregation and adhesion to vascular endothelium [3-5]. Skin studies show that NO is involved in the proliferation and differentiation of epidermal cells, regulation of immune and inflammatory responses, control of allergic manifestations, antigen presentation, and microbicidal activity [6, 7]. NO is a key molecule in wound healing and tissue regeneration due to its gene regulatory properties and its influence on the proliferation and differentiation of fibroblasts, keratinocytes, monocytes, and macrophages [8-15].

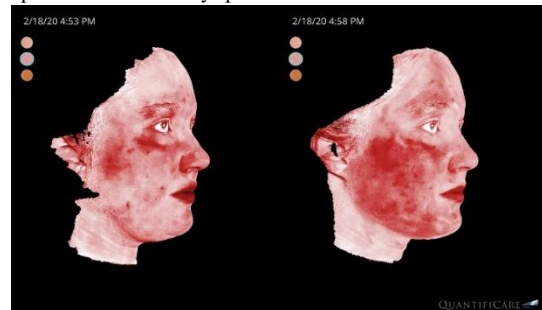
The anti-inflammatory and accelerated keratinization effects of the nitric oxide generating serum were demonstrated in the acne and acne-scarred patient population [16]. This study also demonstrated the safety of applying the NO serum on open wounds, yielding added anti-bacterial



**Figure 6:** 52-year-old female, status non-healing 2<sup>nd</sup>-degree burn for 2 months. Re-epithelialization after 7 days of NO serum. Marked healing after 21 days of NO serum.



**Figure 7:** 46-year-old diabetic male, non-healing foot ulcer. Re-epithelialization 30 days post NO serum.



**Figure 8:** Quantificare 3-D Image analysis demonstrating improved vascularity 30 minutes post NO serum application.

activity, which in turn maximized healing, restored the skin's barrier function, and minimized scar formation.

The ability of a topical NO generating serum to improve circulation and enhance the mobilization and proliferation of fibroblasts was demonstrated in a recent study on the aging skin population [17]. These results transcend into the wound healing patient population. By first decreasing inflammation, and concomitantly accelerating keratinocyte function, barrier restoration to tissue is facilitated. At the same time, neovascularization via capillary recruitment is also facilitated and accelerated.

This paves the way for implementing a topical NO generating serum to be utilized in a number of wound healing, multi-modality scar therapy and surgical scenarios, which were demonstrated in this study. Any condition that predisposes a patient to poor vascularity can be helped. Diabetic stasis wounds or pressure ulcers displayed improved vascularity and tissue repair. Raynaud's syndrome patients displayed improved vascularity in a number of cases (upcoming publication).

Smoking-induced post-surgical ulcers healed in dramatically reduced timeframes.

Pre-treating planned surgical incision sites for procedures such as skin grafts, regional flaps, free flaps, rhytidectomy, blepharoplasty, rhinoplasty, mastopexy, and abdominoplasty showed faster and improved healing when compared to control sites. Ongoing application for 30 days after suture removal improved scar quality in all regions of the body.

## Conclusion

This pilot study reveals that it is possible to apply a topical nitric oxide generating serum to significantly improve vascularity to improve the rate and quality of healing in surgical wounds, vascular compromised wounds, as well as local, regional, and free flaps.

## REFERENCES

1. Chernoff G, Bryan N, Andrea MP (2018) Mesothelial Stem Cells and Stromal Vascular Fraction Use in Functional Disorders, Wound Healing, Fat Transfer, and Other Conditions. *Facial Plast Surg Clin North Am* 26: 487-501. [[Crossref](#)]
2. Bryan NS, Bill Gottlieb B, Zand, J (2011) The Nitric Oxide Solution. *Neogenis Labs* 11: 1.
3. Furchgott RF, Vanhoutte PM (1989) Endothelium-derived relaxing and contracting factors. *FASEB J* 3: 2007-2018. [[Crossref](#)]
4. Radomski MW, Palmer RM, Moncada S (1987) Endogenous nitric oxide inhibits human platelet adhesion to vascular endothelium. *Lancet* 2: 1057-1058. [[Crossref](#)]
5. Moncada S (2000) Nitric oxide and cell respiration: physiology and pathology. *Verh K Acad Geneesk Belg* 62: 171-179. [[Crossref](#)]
6. Weller R (2003) Nitric oxide: a key mediator in cutaneous physiology. *Clin Exp Dermatol* 28: 511-514. [[Crossref](#)]
7. Grierson MMC, Ormerod AD (2004) Nitric oxide function in the skin. *Nitric Oxide* 10: 179-193. [[Crossref](#)]
8. Frank S, Kampfer H, Wetzler C, Pfeilschifter J (2002) Nitric oxide drives skin repair: novel functions of an established mediator. *Kidney Int* 61: 882-888. [[Crossref](#)]
9. Weller R, Price RJ, Ormerod AD, Benjamin N, Leifert C (2001) Antimicrobial effect of acidified nitrite on dermatophyte fungi, Candida and bacterial skin pathogens. *J Appl Microbiol* 90: 648-652. [[Crossref](#)]
10. Rizk M, Witte MB, Barbul A (2004) Nitric oxide and wound healing. *World J Surg* 28: 301-306. [[Crossref](#)]
11. Liew FY, Cox FE (1991) Nonspecific defence mechanism: the role of nitric oxide. *Immunol Today* 12: A17-A21. [[Crossref](#)]
12. Frank S, Kampfer H, Wetzler C, Pfeilschifter J (2002) Nitric oxide drives skin repair: novel functions of an established mediator. *Kidney Int* 61: 882-888. [[Crossref](#)]
13. Fang FC (1999) Nitric oxide and infection. Kluwer Academic/Plenum Publishers, New York.
14. Deliconstantinos G, Villiotou V, Fassitsas C (1992) Ultraviolet-irradiated human endothelial cells elaborate nitric oxide that may evoke vasodilatory response. *J Cardiovasc Pharmacol* 12: S63-S65. [[Crossref](#)]
15. Frank S, Stallmeyer B, Kampfer H, Kolb N, Pfeilschifter J (1999) Nitric oxide triggers enhanced induction of vascular endothelial growth factor expression in cultured keratinocytes (HaCaT) and during cutaneous wound repair. *FASEB J* 13: 2002-2014. [[Crossref](#)]
16. Chernoff G (2020) The utilization of a nitric oxide generation serum in the treatment of active acne and acne scarred patients. *Int J Pharma Anal Acta* 3: 010-014.
17. Chernoff G (2020) The utilization of a topical nitric oxide generating serum in the aging skin population: a pilot study. *Ann Plast Reconstr Surg* 492: 1053.