

Available online at www.sciencerepository.org

Science Repository



Case Report

One Stage Minimally Invasive Thoracoscopic Lung Resection and Transphrenic Adrenalectomy

Patrick Bagan*, Bassel Dakhil, Rym Zaimi and Mahine Kashi-Dakhil

Department of Thoracic and Vascular Surgery, Victor Dupouy Hospital, Argenteuil, France

ARTICLE INFO

Article history:

Received: 17 August, 2020

Accepted: 31 August, 2020

Published: 21 September, 2020

Keywords:

Non-small cell lung cancer (NSCLC)

adrenal metastasis

video-assisted thoracic surgery

ABSTRACT

Surgery may offer a long-term survival benefit to a small proportion of patients with operable non-small cell lung cancer (NSCLC) and solitary adrenal metastasis. Several approaches to lung resection with a separate open or laparoscopic adrenalectomy have been advocated. We present a technique that allows a single incision, single operation through a transdiaphragmatic approach to the ipsilateral adrenal gland following lung resection through a video assisted thoracic surgery (VATS) approach. By using this approach, along with an advanced bipolar device to aid adrenal dissection and clip-less vessel closure, both lobectomy and adrenalectomy can be carried out safely and effectively with minimal perioperative and postoperative morbidity.

© 2020 Patrick Bagan. Hosting by Science Repository.

Introduction

Metastasis from non-small cell lung cancer (NSCLC) is traditionally considered as a contraindication to surgery. Favorable long-term survival following staged lung resection and resection of synchronous isolated adrenal metastasis has been reported in N0 patients [1, 2]. Considering the retroperitoneal location of the adrenal gland, the transdiaphragmatic approach offers an attractive alternative to standard approaches to adrenal tumors [3, 4]. We describe a minimally invasive technique of curative lobectomy and adrenalectomy through the thoracic approach.

Case Report

We present the case of a 71-year-old male with a personal history of right upper lobectomy for T1aN0M0 NSCLC, chronic obstructive pulmonary disease, and malnutrition. During the follow-up, a nodule in the left upper lobe was detected 24 months after lobectomy. The nodule was associated with a synchronous isolated tumor of the left adrenal gland on the PET CT scan. The adrenal gland biopsy confirmed the diagnosis of

NSCLC metastasis. The multidisciplinary meeting decision was to operate both tumors after a pulmonary rehabilitation program.

Technique

VATS approach is performed through four thoracoports for optic (10 mm in diameter) and for endoscopic instruments (3, 5 and 10 mm in diameter) placed in the sixth intercostal space on the anterior axillary line, on the seventh intercostal space on the mid-axillary line and posteriorly to the scapula in the auscultatory triangle in the sixth intercostal space (Figure 1). Transdiaphragmatic approach is performed through the four ports with a low-pressure capnothorax. Phrenotomy is started from the mediastinum and then extended posteriorly with the advanced bipolar device. The peritoneum and retroperitoneal fat are exposed with 3 mm instrument (Figure 2). Meticulous division of the arteries and venous drainage ligation was performed with the bipolar device to avoid bleeding (Figure 3). The adrenal gland is extracted en-bloc through the 10 mm incision (Figure 4). Hemostasis is completed with instillation of hemostatic glue in the adrenalectomy bed and the diaphragm is closed using interrupted stitches.

*Correspondence to: Patrick Bagan, M.D., Service de Chirurgie Vasculaire et Thoracique, Hôpital Victor Dupouy, 95100 Argenteuil, France, E-mail: patrick.bagan@ch-argenteuil.fr

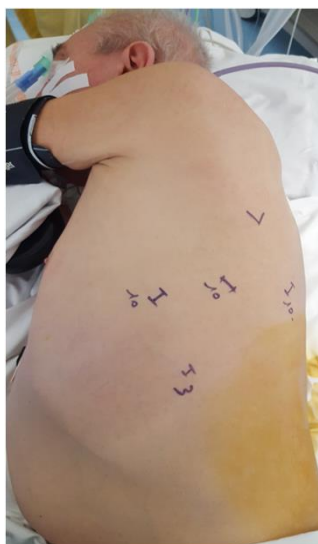

Figure 1: VATS approach for adrenalectomy and lobectomy.

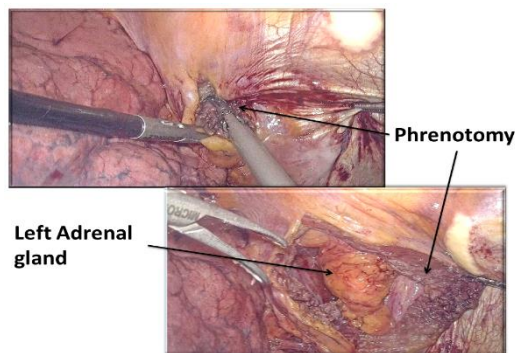


Figure 2: Left phrenotomy for the exposition of the adrenal gland.

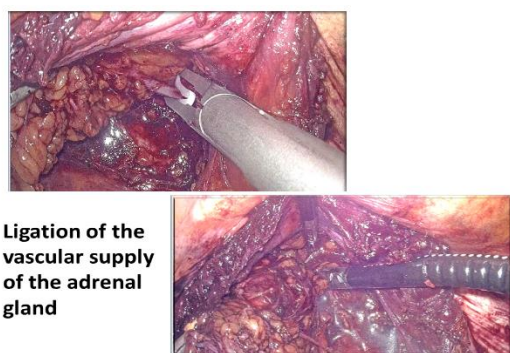


Figure 3: Vascular ligation of the adrenal gland.

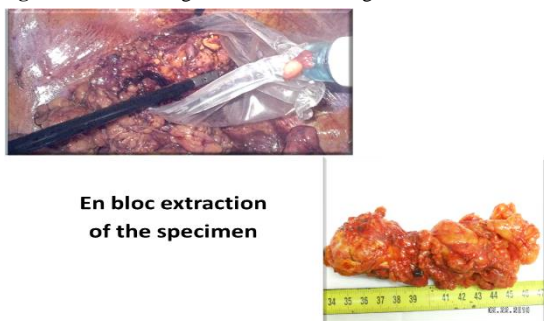

Figure 4: En bloc extraction of the adrenal gland.

A VATS lobectomy is then performed with hilar and mediastinal lymphadenectomy. The pain control was obtained with a paravertebral catheter inserted in the seventh intercostal-vertebral space. The catheter was removed at the same time of the chest tube removal. The patient was discharged at home with paracetamol and a nonsteroidal anti-inflammatory drug regimen, which is continued during physiotherapy. The postoperative course was uneventful, and the patient was discharged on the third postoperative day. After a 24 months follow up, the patient is still alive without cancer recurrence.

Discussion

The solitary adrenal metastases are often on the same side as the primary lung lesion. This suggests a physiological significance of diaphragmatic lymph vessel connections between the lung and the retroperitoneum and a relationship between ipsilateral adrenal metastases and limited metastatic spread [5]. A durable long-term survival is observed in approximately 25% of patients following adrenalectomy for synchronous and metachronous metastasis from NSCLC [6]. In oligometastatic NSCLC patients, meta-analyses suggest that aggressive therapies in primary lung cancer, the (y)pT-stage, the absence of nodal diseases and the adenocarcinoma histology have been clarified as positive prognosis [7]. For the subgroup of NSCLC patients with isolated adrenal metastasis undergoing surgical treatment for the primary tumor and adrenal metastasis could achieve a significant survival benefit, especially if they are negative for lymph node metastasis [8]. Patients with ipsilateral adrenal metastasis may derive the greatest survival benefit from adrenalectomy, since spread to the ipsilateral gland may occur via direct lymphatic channels in the retroperitoneum. The involvement of the contralateral adrenal may signify haematogenous spread and therefore, a more aggressive process [9].

The VATS approach is an alternative approach to the double thoracotomy technique and to the laparoscopic adrenalectomy [4]. This approach is a viable option for the treatment of this difficult problem with potentially less morbidity. The major issue of this approach for adrenalectomy is the vessel closure. The advance bipolar device is used because of its safety and efficacy for hemostasis during adrenalectomy [10].

In conclusion, adrenalectomy should be considered as a therapeutic option for patients with synchronous metastases from NSCLC. Adrenalectomy can be carried out during the same operation. The minimal invasive technique should be the preferred approach in this small subset of patients with resectable primary lung cancer.

Conflicts of Interest

None.

REFERENCES

1. Pierre Mordant, Alex Arame, Florence De Dominicis, Ciprian Pricopi, Christophe Foucault et al. (2012) Which metastasis management allows long-term survival of synchronous solitary M1b non-small cell lung cancer? *Eur J Cardiothorac Surg* 41: 617-622. [Crossref]

2. H Porte, J Siat, B Guibert, F Lepimpec Barthes, R Jancovici et al. (2001) Resection of adrenal metastases from non-small cell lung cancer: a multicenter study. *Ann Thorac Surg* 71: 981-985. [[Crossref](#)]
3. S Halachmi, L A Best, B Moskovitz, S Madjar, O Nativ (1996) Transthoracic approach for the removal of adrenal tumors. Early experience with 10 cases. *Eur Urol* 30: 480-483. [[Crossref](#)]
4. Ian Hunt, Sheila C Rankin, Loic Lang Lazdunski (2006) Combined lung resection and transdiaphragmatic adrenalectomy in patients with non-small cell lung cancer and homolateral solitary adrenal metastasis. *Eur J Cardiothoracic Surg* 30: 194-195. [[Crossref](#)]
5. P Károlyi (1990) Do adrenal metastases from lung cancer develop by lymphogenous or hematogenous route? *J Surg Oncol* 43:154-156. [[Crossref](#)]
6. Tawee Tanvetyanon, Lary A Robinson, Michael J Schell, Vivian E Strong, Rachna Kapoor (2008) Outcomes of adrenalectomy for isolated synchronous versus metachronous adrenal metastases in non-small-cell lung cancer: a systematic review and pooled analysis. *J Clin Oncol* 26: 1142-1147. [[Crossref](#)]
7. Shangbiao Li, Rui Zhu, Dianhe Li, Na Li, Xiaoxia Zhu (2018) Prognostic factors of oligometastatic non-small cell lung cancer: a meta-analysis. *J Thorac Dis* 10: 3701-3713. [[Crossref](#)]
8. Xin Liang Gao, Ke Wei Zhang, Ming Bo Tang, Ke Jian Zhang, Li Nan Fang et al. (2017) Pooled analysis for surgical treatment for isolated adrenal metastasis and non-small cell lung cancer. *Interact Cardiovasc Thorac Surg* 24: 1-7. [[Crossref](#)]
9. Priya Sastry, Adam Tocock, Aman S Coonar (2014) Adrenalectomy for isolated metastasis from operable non-small-cell lung cancer. *Interact Cardiovasc Thorac Surg* 18: 495-497. [[Crossref](#)]
10. Onder Surgit (2010) Clipless and sutureless laparoscopic adrenalectomy carried out with the LigaSure device in 32 patients. *Surg Laparosc Endosc Percutan Tech* 20: 109-113. [[Crossref](#)]