

Available online at www.sciencerepository.org

Science Repository



Case Report and Review of the Literature

Meconium Peritonitis: Report of Three Cases and Review of Literature

Biswanath Mukhopadhyay^{1}, Debasish Mitra¹ and Bikramjit Das²*

¹Department of Pediatric Surgery, Apollo Gleneagles Hospital, Kolkata, India

²Department of Pediatrics and Neonatology, Apollo Gleneagles Hospital, Kolkata, India

ARTICLE INFO

Article history:

Received: 25 July, 2020

Accepted: 5 August, 2020

Published: 21 August, 2020

Keywords:

Meconium

peritonitis

neonates

laparotomy

ABSTRACT

Meconium peritonitis carries a high risk of mortality in neonates. The etiology may be varied, and the perforation may occur either antenatally or in the immediate postnatal period. A strong clinical suspicion is required, and urgent management is crucial for survival without loss of functional gut. The underlying cause of intestinal obstruction must be carefully investigated. Postoperative management with parenteral nutrition, management of short gut and assessment of neurodevelopment are crucial for better quality of life. We present here three cases of complicated meconium peritonitis with perforation. We highlight the importance of high clinical suspicion and timely management resulting in good clinical outcomes.

© 2020 Biswanath Mukhopadhyay. Hosting by Science Repository.

Introduction

Meconium peritonitis carries a high risk of mortality in neonates, especially if identification is late and appropriate management is not provided. It may occur due to a variety of underlying causes like atresia, stenosis, volvulus, intussusception, peritoneal bands, Hirschsprung [1]. The perforation may occur either in utero or in the perinatal period. Neonate presents with features ranging from intestinal obstruction to collapse requiring emergency exploration after initial stabilization. Intra abdominal calcification indicates antenatal perforation [2]. High clinical suspicion should be kept on basis of antenatal ultrasound findings and postnatal abdominal findings. Prompt surgical correction and postnatal care has dramatically improved the survival of these babies [3]. We present here three cases of meconium peritonitis and the management in the postoperative period along with review of literature.

Case 1

Baby A, a 2.7 kg female was born to a primi mother with antenatal USG showing a cystic abdominal lesion (? Adnexal mass/? Enteric duplication cyst) without any evidence of hyperechogenicity, hydrups,

polyhydramnios. Born through elective cesarean section and cried at birth with normal APGAR's. On abdominal examination, a mass of size 3x3 cm could be palpated in the umbilical region, mass was non-tender and the remaining abdomen was soft without any distension. Baby was hemodynamically stable. Baby was started on intravenous fluids; continuous nasogastric aspiration and an abdominal x-ray was done which showed a cystic lesion with wall calcification and multiple air-fluid levels with air-fluid level within the cystic lesion (Figure 1A). A diagnosis of meconium pseudocyst was considered, baby was kept nil per mouth and prepared for surgery. However, baby had sudden deterioration by 12 hours of life in form of respiratory distress, abdominal distension and shock. Baby was resuscitated with ventilation, intravenous fluids and inotropes. An urgent x-ray showed pneumoperitoneum (Figure 1B) for which emergency laparotomy was done at 16 hours of life. Intra operatively there was meconium spillage in the peritoneum with multiple fibrous adhesions indicating old perforation, atresia of terminal ileum with huge dilatation and volvulus of proximal ileum, thick tarry meconium in terminal ileum and a collapsed large colon.

*Correspondence to: Professor Biswanath Mukhopadhyay M.S., M.Ch., FRCS, FAMS, Senior Consultant, Pediatric Surgery, Apollo Gleneagles Hospitals, 58 Canal Circular Road, Kolkata 700054, Former Professor and Head of the Department of Pediatric Surgery, N R S Medical College, Kolkata 700014, India; E-mail: mukhopadhyay_b@yahoo.in

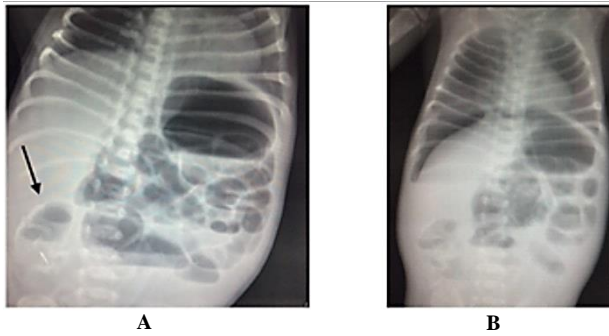


Figure 1: **A)** X-ray abdomen AP supine view showing multiple air fluid levels and a cystic calcified lesion in the right iliac fossa (arrow) suggestive of a meconium pseudocyst. **B)** X-ray abdomen erect view of the same baby showing air under diaphragm.

Thorough peritoneal lavage was done with warm normal saline, volvulus was corrected, and gut health assessed, the atretic segment was resected and the proximal and distal ileum were brought out as stoma using the double barrel technique. In the postoperative period, parenteral nutrition and antibiotics were continued. Baby received N-acetyl cysteine through nasogastric tube for clearing the thick meconium. Feeds were gradually introduced from post-operative day 10. Baby started having loose stools following feed introduction. Sepsis workup and stool cultures were sent which were sterile. Feeds were changed initially to lactose free formula and later even to elementary formula. As loose stools persisted and fluid requirement was high, an innovative method was used wherein the proximal stoma output was collected in a sterile bag and put back into the distal stoma under aseptic conditions (Figure 2).

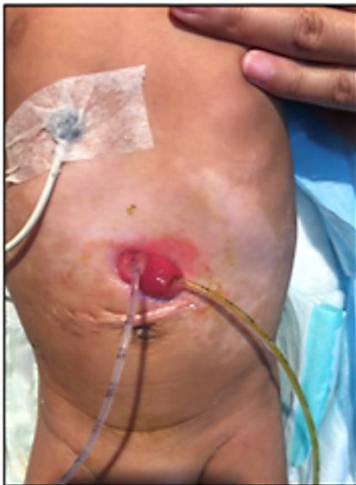

Figure 2: Picture shows proximal stoma on the right and distal stoma on the left of the figure. This technique was innovated for management of short gut. But the stomas have tubes inserted for collection. The proximal stoma output is continuously collected in sterile bag and is inserted under aseptic conditions into the distal stoma intermittently.

The purpose of this technique was to provide a greater absorptive surface and also to test the patency and peristalsis of distal gut. Gradually baby started passing formed stools, weight gain was achieved, stool output reduced, parenteral nutrition was tapered off. Baby was discharged on lactose free formula and mother continued the proximal to distal stoma output reinsertion at home under aseptic conditions. Baby remained

stable and continued to gain weight at a slow pace. A biopsy sent from the appendix at the time of surgery showed the presence of ganglion cells. The neonatal screen was sent for immunoreactive trypsinogen and was normal. Finally, after 3 months, the stoma was closed. Currently baby is 9 month old, well thriving, normal developmental milestones and no further respiratory or gastrointestinal complaints.

Case 2

Baby B, term 2.8 kg female was born to a primigravida mother at an outside hospital with no antenatal risk factor. Born through elective cesarean and cried at birth with normal APGAR's. Baby was started on feeds. There was progressive abdominal distension with bilious aspirates and respiratory distress. Baby was made nil per mouth and referred at 20 hours of life. At admission baby was in cardiorespiratory failure, was resuscitated with ventilation, intravenous fluids, antibiotics and nasogastric drainage. Abdomen was grossly distended, tense and tender and tympanic with positive transillumination. An urgent x-ray revealed a pneumoperitoneum and a cystic lesion in right iliac region with perilesional calcification suggestive of a meconium pseudocyst and antenatal perforation (Figure 3).

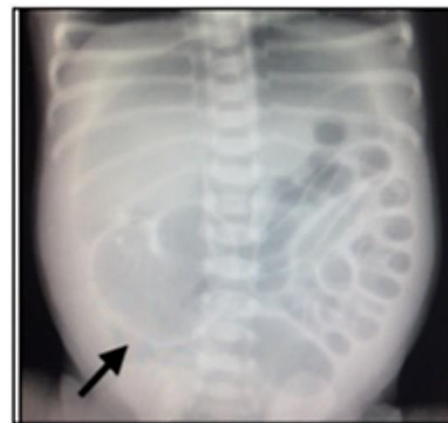

Figure 3: X-ray abdomen AP supine view showing dilated loops and a pneumoperitoneum suggested by football sign. Also, can be seen is a cystic calcified lesion in the right iliac fossa (arrow) suggestive of a meconium pseudocyst.

After initial stabilization emergency laparotomy was done which showed old meconium in the peritoneum with multiple fibrous adhesions, terminal 10 cm of ileum was atretic, huge dilatation with volvulus of proximal ileum and perforation. Thorough peritoneal lavage was done with warm normal saline, volvulus was corrected, and gut health assessed, the atretic segment was resected and the proximal ileum was brought out as stoma. In the postoperative period, parenteral nutrition and antibiotics were continued. Feeds were gradually started on postoperative day 7. Baby started having loose stools following feed introduction. Feeds were changed initially to lactose free formula and later to elementary formula. Loose stools gradually reduced in volume and weight remained stable. Mother was taught ileostomy care and feeding at home was continued with lactose free formula. Thereafter baby was discharged with planned follow-up after one week. However, baby was readmitted after 3 days with loose stools and dehydration. Sepsis workup revealed Klebsiella infection, antibiotics and parenteral

nutrition were started. After stabilization of fluid and electrolyte status, baby underwent stoma closure and anastomosis.

On postoperative day 5 there was evidence of wound dehiscence, however baby was passing stools and there was no abdominal distension or aspirates. As the wound dehiscence was contained to superficial skin and muscle layer, it was managed conservatively with dressings. In the meantime, baby was started on feeds which baby tolerated well. At discharge baby was passing 7-8 times semisolid stools per day and weight was stable. Baby was discharged and in follow up stool frequency and consistency improved. The neonatal screen was sent for immunoreactive trypsinogen and was normal. Currently baby is 6 month old, well thriving, normal developmental milestones and no further respiratory or gastrointestinal complaints.

Case 3

Baby C, term 2.5 kg, small for gestational age female was born to a primigravida mother at an outside hospital with no antenatal risk factor. Born through vaginal delivery and cried at birth with normal APGAR's. Baby was started on feeds. There was progressive abdominal distension with bilious aspirates and respiratory distress. Baby was made nil per mouth and abdominal x-ray showed pneumoperitoneum. Glove drain was inserted and managed conservatively. Baby was referred on day 8 of life. At admission vitals were stable, abdomen was grossly distended with visible loops, non-tender and bilious aspirates. X-ray at admission revealed grossly dilated loops without any air collection. Baby was kept nil by mouth, started on intravenous fluids and antibiotics. After initial stabilization laparotomy was done which showed old meconium in the peritoneum with multiple fibrous adhesions, huge dilatation with volvulus of proximal ileum. Perforation was identified in terminal ileum; appendix was removed and the appendix along with distal ileum piece was sent for calretinin stain and biopsy for identification of ganglion cells.

Thorough peritoneal lavage was done with warm normal saline, distal ileum was given saline wash to clear the meconium, volvulus was corrected, and gut health assessed, the proximal and distal ileum were brought out as stoma using the double barrel technique. In the postoperative period, parenteral nutrition and antibiotics were continued for culture positive sepsis. Baby received N-acetyl cysteine through nasogastric tube for clearing the thick meconium. Feeds were gradually started on postoperative day 7 and reached full feeds in next 2 days. Biopsies did not show the presence of any ganglion cells and a diagnosis of total colonic aganglionosis was made. Mother was taught ileostomy care and baby was discharged with plan to readmit after 2-3 months for corrective Duhamel's procedure. Subsequently Duhamel operation was done, and the patient is doing well.

Discussion

Meconium peritonitis is the outcome of intrauterine or perinatal bowel perforation, extrusion of sterile meconium in the peritoneum and the resulting chemical peritonitis [1]. The underlying etiology may be structural like atresia, stenosis, intussusception, volvulus, peritoneal bands, internal hernia wherein the patency of distal gut is reduced and presents a barrier to passage of meconium or functional like meconium

ileus, meconium plug syndrome, Hirschsprung's disease wherein the meconium does not achieve progressive movement despite a patent tract [1]. In the latter case, either the meconium is too viscous to be propelled forwards by intact intestinal peristalsis as in meconium ileus and plugs or the distal gut lacks a normal peristalsis mechanism as in Hirschsprung's disease. Other causes like intrauterine infection with cytomegalovirus, rubella and parvovirus can also lead to meconium peritonitis but the exact underlying mechanism is unclear [4]. Among these meconium ileus, atresia and volvulus are the most common causes for meconium peritonitis. An underlying diagnosis of cystic fibrosis is made in as many as 10-20 percent cases of meconium peritonitis due to non-structural causes [5].

The antenatal ultrasound often provides clues suggestive of an intestinal obstruction. Findings like hyperechogenic bowel, polyhydramnios, ascites, scrotal swelling, cystic lesions, intrabdominal or scrotal calcification are useful to alert the team towards a possible intestinal involvement [6]. However individually they are not specific and lack a predictive capacity and hence clinical decisions based on isolated findings are not recommended. An approach involving serial follow up ultrasounds and combination of features gives a better predictive value [2]. Intraabdominal cysts in the fetus may be ovarian, enteric duplication, renal cysts or meconium pseudocyst [2]. The increased wall thickness and associated calcification usually points towards a meconium pseudocyst. Around 85 percent of fetuses with meconium peritonitis have intra abdominal calcification [2, 6]. A diffuse abdominal calcification point towards the generalized form of meconium peritonitis. There are cases wherein the perforation has not yet occurred, and they are usually picked up in the immediate postnatal period with progressively increasing abdominal distension following feeds.

Postnatal approach depends on whether any antenatal clues towards a possible intestinal obstruction exist or not. In suspected cases, the baby should be kept nil by mouth and an erect abdominal X-ray should be done on urgent basis. At the same time the abdomen of the baby should be monitored for any distension and passage of meconium. This also implicates for those cases where antenatal clues are absent, and feeds are started at birth. A repeat x-ray can be considered around 6 hours of life to look at pattern and progression of intestinal gas. If the x-ray does not show any feature of antenatal perforation, normal abdomen examination with progression of intestinal gas along with passage of meconium, feeds can be gradually introduced keeping close watch on abdomen and gradually hiked. If there are no features of perforation but the baby has not passed meconium and there are features of obstruction, a gastrografin enema should be undertaken with a full backup for emergency laparotomy in case perforation occurs during or after the procedure. A dilated colon usually points towards a large gut pathology of which Hirschsprung is an important cause. The presence of microcolon indicates an unused distal gut. If filling defects are demonstrated in the terminal ileum, a presumptive diagnosis of uncomplicated meconium ileus or plugs can be considered. In that case, the baby may need several bowel washes which may include repeat enemas, mucolytic solutions like N-acetyl cysteine or T-tube enterostomy [7, 8].

Thereafter feeds can be gradually introduced while abdomen is being monitored. If the workup reveals evidence of perforation or there is recurrence of distension on introducing feeds despite washes, a

laparotomy should be undertaken. The purpose of laparotomy includes finding any evidence of perforation by the presence of meconium in peritoneum or adhesions and to locate the site of perforation in that case, rule out any structural causes of intestinal obstruction, take biopsies from multiple sites to rule out Hirschsprung disease and to create diversion stoma in case primary repair is not being done. Only our first case which was a booked case had antenatal clue of an intrabdominal cyst but was considered to be of ovarian origin. All the three cases had perforation, two of which were referred to us with perforation. One of our cases showed absence of ganglion cells on biopsy and a diagnosis of total colonic aganglionosis was made.

The surgical approach in a case of meconium peritonitis varies from center to center. It can be either single stage (primary anastomosis), two stage (temporary enterostomy followed by corrective reconstruction) or three stage (abdominal drain, temporary enterostomy followed by corrective reconstruction) [9, 10]. We usually perform the two-stage procedure as there may be higher chance of re-laparotomy due to adhesions and it gives us time to rule out Hirschsprung's on biopsy. We also get cases referred from other centers where the facility of pediatric surgery is not readily available and such cases usually come to us with an abdominal drain. The possibilities of longer duration of parenteral nutrition, hospital stay, cost of stay, risk of sepsis are associated with two or three staged procedures.

Prognosis mainly depends on associated organ dysfunction, duration of parenteral nutrition, associated sepsis, length of functioning gut, cholestasis from parenteral nutrition, presence of associated conditions like cystic fibrosis. Total colonic aganglionosis is associated with loss of large absorptive surface and features of short gut. In other causes of meconium peritonitis, although the physical gut loss is limited but since the gut stays under prolonged obstruction, the ensuing venous congestion and mucosal hyperemia lead to features of short gut [3]. Such cases may persist for long durations and need to be managed with parenteral nutrition, trying different types of feed like lactose free, hydrolyzed and elemental formula. Despite these babies may continue to have extensive losses. Our first case had such features and to win that scenario we devised a unique technique of collecting the proximal stoma output and reinserting into the distal stoma. Theoretically it gives longer transit time and larger absorptive surface.

In addition, it also tests the peristalsis of distal gut and helps to rule out Hirschsprung clinically. This procedure however has to be done under aseptic conditions which we were able to even teach to mother which she continued at home. This helped us to wean the parenteral nutrition and discharge the baby. Besides gut related complications these babies also are at risk of developing neurodevelopmental impairment [3]. Cystic fibrosis should be ruled out in cases of meconium disorders. A screening with immunoreactive trypsinogen is quite sensitive. However,

if the suspicion is high a sweat chloride test is the gold standard and mutation analysis is also required. Hence these babies need long term follow-up for growth and development. All our three cases are having a normal neurodevelopment as for their respective ages.

Conclusion

The spectrum of meconium disorders is wide, and clinician must keep strong suspicion and investigate any case suggestive of intestinal obstruction in the neonate. An urgent and systematic approach helps in diagnosis and prevents unwanted complications. Postoperatively these babies need to be monitored for gut functions, growth and development.

REFERENCES

1. Chan KL, Tang MH, Tse HY, Tang RY, Tam PK (2005) Meconium peritonitis: Prenatal diagnosis, postnatal management and outcome. *Prenat Diagn* 25: 676-682. [[Crossref](#)]
2. Zangheri G, Andreani M, Ciriello E, Urban G, Incerti M et al. (2007) Fetal intra- abdominal calcifications from meconium peritonitis: sonographic predictors of postnatal surgery. *Prenat Diagn* 27: 960-963. [[Crossref](#)]
3. Sato M, Hamada Y, Kohno M, Ise K, Uchida K et al. (2017) Neonatal gastrointestinal perforation in Japan: a nationwide survey. *Pediatr Surg Int* 33: 33-41. [[Crossref](#)]
4. Radner M, Vergesslich KA, Weninger M, Eilenberger M, Ponhold W et al. (1993) Meconium peritonitis: a new finding in rubella syndrome. *J Clin Ultrasound* 21: 346-349. [[Crossref](#)]
5. Casaccia G, Trucchi A, Nahom A, Aite L, Lucidi V et al. (2003) The impact of cystic fibrosis on neonatal intestinal obstruction: the need for prenatal/ neonatal screening. *Pediatr Surg Int* 19: 75-78. [[Crossref](#)]
6. Wang C, Chang S, Chao A, Wang T, Tseng L et al. (2008) Meconiumperitonitis in utero---the value of prenatal diagnosis in determining neonatal outcome. *Taiwan J Obstet Gynecol* 47: 391-396. [[Crossref](#)]
7. Karimi A, Gorter RR, Sleeboom C, Kneepkens CMF, Heij HA (2011) Issues in the management of simple and complex meconium ileus. *Pediatr Surg Int* 27: 963-968. [[Crossref](#)]
8. Barthel ER, Speer AL, Levin DE, Naik Mathuria BJ, Grikscheit TC (2012) Giant cystic meconium peritonitis presenting in a neonate with classic radiographic eggshell calcifications and treated with an elective surgical approach: a case report. *J Med Case Rep* 6: 229. [[Crossref](#)]
9. Miyake H, Urushihara N, Fukumoto K, Sugiyama A, Fukuzawa H et al. (2011) Primary anastomosis for meconium peritonitis: first choice of treatment. *J Pediatr Surg* 46: 2327-2331. [[Crossref](#)]
10. Saxena P, Dabral A, Arora R, Minocha B (2009) Meconium Peritonitis- Two case reports. *J Obstet Gynaecol India* 59: 475-476.