

Available online at www.sciencerepository.org

Science Repository



Case Report

Successful Management of COVID-19 Pneumonia Following Live-Related Kidney Transplant in a 74-Year-Old Recipient

Sameh Mayaleh*, John Black, Islam Eldiasty, Baher Elshikh, Krishna Thayagaraj, Anna Rizello, Taher Doughman, Mohamed Morsy and Atul Bagul

University Hospitals of Leicester NHS Trust, United Kingdom

ARTICLE INFO

Article history:

Received: 20 July, 2020

Accepted: 30 July, 2020

Published: 14 August, 2020

Keywords:

COVID-19

corona virus

kidney transplantation

live-related kidney transplantation

ESKD

ABSTRACT

Background: COVID-19 infection is the most recent worrying viral pandemic worldwide. Little is understood regarding the course of illness and subsequent immediate and long-term complications. Despite numerous ongoing trials, there is still no agreed mode of treatment for this viral illness. Live-donor renal transplantation is the gold standard treatment for end-stage renal disease. Those patients undergoing renal transplantation are deemed particularly high risk for contracting COVID-19 secondary to the effects of immunosuppression. This case report discusses management of COVID-19 infection in a 74-year-old male, who underwent a live-related kidney transplant.

Case Presentation: A 74-year-old Caucasian male patient, developed renal failure due to diabetic nephropathy since 2012. The patient was transplanted in 2013 with a graft from a deceased donor, but unfortunately this kidney failed in 2014, aetiology unknown. Haemodialysis was recommenced until he received a second kidney transplant from a live-related donor in March 2020. Unfortunately, postoperative recovery was complicated with COVID-19 infection. The clinical signs and symptoms, along with details surrounding presentation are discussed. This includes the rationale behind the management of such high-risk immunosuppressed patients with COVID-19 infection.

Conclusion: There is still no consensus about the best modality for treating COVID-19 infection in recipients of solid organ transplantation. From our experience, temporarily stopping the anti-proliferative immunosuppressant (e.g. Mycophenolate mofetil) during the acute illness seemed to enhance recovery of the acute phase of the disease.

© 2020 Sameh Mayaleh. Hosting by Science Repository

Background

Live-donor renal transplantation remains the UK gold-standard therapy for ESRF, with live donors having the best outcomes in relation to longevity of graft function and survival. However, recipients of grafts from live donors are subject to similar immunosuppressive risks such as opportunistic infections and viral-induced malignancies. SARS-CoV-2 (COVID-19) is a novel coronavirus, first reported in Wuhan, China in December 2019. As of 9th June 2020, there had been 7.02 million reported cases of COVID-19 worldwide, leading to 403,845 reported deaths. The initial outbreak was reported at a Seafood Wholesale Market, in Wuhan, Hubei, China in December 2019. The market was shut down

on January 1, 2020, after the announcement of an epidemiologic alert [1]. During the following weeks, an increasing number of cases were reported in surrounding countries. Lockdowns that seemed draconian when instigated in Wuhan only 2 months ago became commonplace across the globe.

Solid organ transplant recipients have displayed a spectrum of clinical manifestations similar to their non-transplant counterparts. Immunosuppressive treatment, hypothetically, leads to more severe complications when compared to their non-immunocompromised counterparts. Despite a wide-range of symptoms reported, COVID-19 classically starts with dry cough, fever, fatigue and occasional gastrointestinal symptoms. In severe cases, this can progress into a

*Correspondence to: Sameh Mayaleh, University Hospitals of Leicester NHS Trust, United Kingdom; E-mail: sameh.mayaleh@uhl-tr.nhs.uk

pneumonic inflammation, cytokine release and pneumonia with ensuing respiratory failure, multi-organ failure and eventual death.

Case Presentation

A 74-year-old Caucasian male, known to have ESRD due to diabetic nephropathy since 2012 received a renal transplant from a deceased donor in 2013. Unfortunately for reasons unknown, the graft started to fail and the patient recommenced haemodialysis in 2014. In March 2020, a second kidney transplant from a related living donor was performed, with complete ABOi compatibility and mismatch grade of 1-1-1. The transplant was considered standard risk. Induction Immunosuppression included Basiliximab 20 mg IV on day 0 and day 4, and methylprednisolone 500 mg on day 0 in line with local trust policy. Maintenance immunosuppression was Tacrolimus (0.05 mg per KG) twice daily with aim of Tacrolimus trough levels of 6-8 ng/ml for the first 3-6 months, and Mycophenolate 500 mg twice daily, and prednisolone 20 mg once daily (to be tapered down fortnightly to 5 mg once daily). Intraoperative and postoperative recovery was uneventful. The recipient was discharged home on day 6. Serum creatinine was 207 $\mu\text{mol/L}$ (down from 700 $\mu\text{mol/L}$ pre-transplant) (Table 1). Ultrasound

scanning in the postoperative period demonstrated global graft perfusion with no concerning features.

Following renal transplant, the patient was reviewed in the outpatient setting three times a week as per protocol. On clinical review, the recipient complained of mild SOB, particularly on exertion. Examination demonstrated bilateral air entry with no significant findings on auscultation. The patient reported no fever, cough or other symptoms consistent with COVID-19. Fluid retention in the form of bilateral leg swelling was noted. He was commenced on 40 mg Furosemide OD to address this issue and returned home. The recipient attended for further outpatient clinic review on 3rd of April 2020. During this consultation, worsening dyspnoea was reported, even at rest. A persistent dry cough was noted. The patient remained afebrile with a documented temperature of 37.1 °C. Re-examination of the chest demonstrated bilateral basal crackles. Routine bloods revealed a serum creatinine of 124 $\mu\text{mol/L}$ with an EGFR of 49 ml/Minute, WBC count was $10.4 \times 10^9/\text{L}$, Neutrophils were $9.32 \times 10^9/\text{L}$ and lymphocytes were $0.6 \times 10^9/\text{L}$ (Table 1). He was admitted for further investigations which included a nasopharyngeal swab test for SARS-CoV-2 RNA PCR, a chest X-ray and a full septic screen including bloods for virology (CMV, EBV, PCP, and BK) along with routine cultures.

Table 1: Combined lab biochemistry results.

	Pretransplant	D1 post-transplant	D7	Second admission	D1	D2	D10	1 st clinic post discharge	2 months post discharge
Creatinine $\mu\text{mol/L}$	700	387	144	124	124	117	93	94	87
EGFR ML/Min	6	12	41	49	49	53	70	69	76
WBC $\times 10^9/\text{L}$	7.8	15.8	13.7	10.4	9.2	8.5	4.1	8.9	6.5
Lymphocyte $\times 10^9/\text{L}$	1.3	0.8	0.8	0.6	0.5	0.5	0.5	0.8	1.1
Neutrophils $\times 10^9/\text{L}$	5.5	10.57	12.94	9.32	8.44	7.58	3.38	7.54	4.61
Tac Level ng/ml	-		7.5	8.1	-	7.1	9.2	-	6.3
CRP Mg/L	<5	<5	-	42	34	32	32	-	-

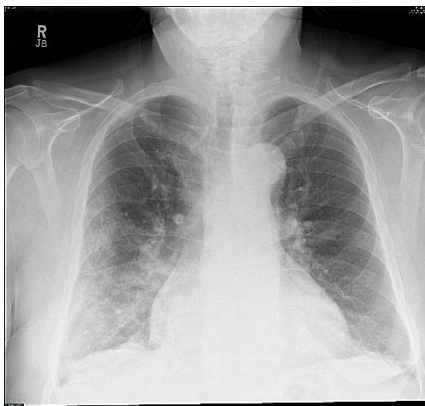


Figure 1: Chest X-ray on admission.

SARS-CoV-2 RNA PCR testing was positive. The CXR showed diffused ground glass appearances consistent with radiological findings of COVID-19 infection (Figure 1). The patient was admitted and isolated on a ward designated for COVID-19 cases. In the absence of any robust clinical guidelines for such scenarios, the decision was made to discontinue mycophenolate, whilst continuing the remaining immunosuppression (Adoport with trough level of 6-8 ng/ml and prednisolone 20 mg once daily). He was commenced on oxygen therapy via nasal specs, with target saturations above 97% respectively. In

addition, meropenem 1G TDS was also initiated. Tacrolimus level was closely monitored, aiming for a range of 6-8 ng/ml.

On day-2 of admission, the patient became pyrexial (38.1-39.3 degrees Celsius), with an associated tachypnoea of 20 respirations per minute. Oxygen saturation remained around 97% on 2L O₂ nasal cannula. Progressively, the patient developed a productive cough with persistent SOB but remained haemodynamically stable. A further CXR showed worsening ground-glass appearances. Following consent, the patient was placed into a clinical trial testing the efficacy of hydroxychloroquine on COVID-19 positive patients. In this case, the recipient was allocated to the placebo group.

On day-4 of admission the patient reported improving dyspnoea, and he was able to maintain target oxygen saturation on 1L O₂ therapy. Graft function remained stable (creatinine 113 $\mu\text{mol/L}$, EGFR 55 ml/minute). Pyrexia was persistent, with intermittent spikes of over 38 degrees Celsius. After 10 days of continued management, the patient showed dramatic improvement. Oxygen saturations were maintained independently on room air. Pyrexia had settled and the recipient had been afebrile for 72 hours. The cough initially reported remained persistent. Mycophenolate was recommenced twice daily at a dose of 250mg, with an aim to increase the dose to 500 mg BD after a week following review in outpatient clinic. He was discharged on day 11 post admission with a

serum creatinine of 93 $\mu\text{mol/l}$ (EGFR 70 ml/minute). WBC was $4.1 \times 10^9/l$ (neutrophils $3.38 \times 10^9/l$, lymphocytes $0.5 \times 10^9/l$) (Table 1). The cough had improved significantly. Based on the clinical improvements, the patient was advised to self-isolate at home for a further 7 days. Chest X-Ray on discharge showed improvement in radiological findings (Figure 2).

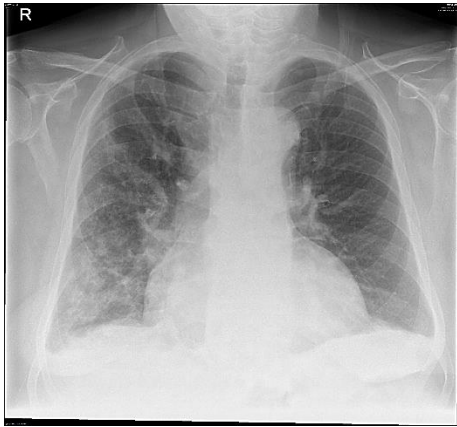


Figure 2: Chest X-ray on discharge.

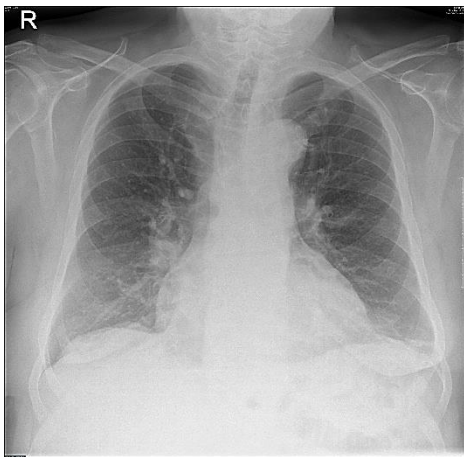


Figure 3: Chest X-ray on 2 months follow up.

The patient showed continuous improvement on subsequent clinic review, with no reported SOB or fever. MMF was increased to 500 mg twice daily, and his Tacrolimus level was maintained within the window of 6-8 ng/ml. His CXR after 2 months from discharge showed significant clearance of the COVID-19 pneumonia (Figure 3).

Discussion

COVID-19 infection has become the most important medical concern since the beginning of 2020. Almost every country has faced a progressive increase in the numbers of reported daily infections. The disease is caused by the novel corona virus, which is one of the RNA coronavirus families, which includes the common cold, severe acute respiratory syndrome (SARS), and Middle East respiratory syndrome (MERS) [2]. Coronavirus is an enveloped, positive single-strand RNA virus. It belongs to the orthocoronavirinae subfamily, as the name, with the characteristic “crown-like” spikes on their surfaces [1]. The exact origin, location, and natural reservoir of the COVID-19 remain unclear,

although it is believed that the virus is zoonotic and bats may be the culprit, because of sequence identity to the bat-CoV [1].

The infection is acute and symptoms usually begin with nonspecific syndromes, including fever, dry cough, and fatigue. Multiple systems may be involved, including respiratory (cough, shortness of breath, sore throat, rhinorrhoea, haemoptysis, and chest pain), gastrointestinal (diarrhoea, nausea, and vomiting), musculoskeletal (muscle ache), and neurologic (headache or confusion). More common signs and symptoms are fever (83%-98%), cough (76%-82%), and short of breath (31%-55%). There were about 15% with fever, cough, and short of breath [3].

The COVID-19 virus may enter the host through respiratory tract or mucosal surfaces (such as conjunctiva). Oral-faecal transmission has not been confirmed. The virus has a preferential tropism to human airway epithelial cells and the cellular receptor, like SARS, is ACE2. However, the pathological changes of the disease and its pathogenesis in human is not clearly elucidated. Theoretically lungs are the predominantly involved organ. Whether the virus replicates in other part of the body remains undetermined [3].

Patients undergoing solid organ transplantation are at increased risk of Coronavirus due to their immunosuppressed status. Still there is no agreed mode of therapy for the virus infection apart from supportive measures. Given the assumed high virulence of the virus in immunosuppressed patients, many countries took different measures to protect such patients, for example asking them to self-isolate, or by decreasing the frequency of these patients attending hospitals or clinics. There were many reported cases of kidney transplant recipients who tested positive for COVID-19. Various management strategies were considered, with reduction in immunosuppression as a common theme. Some of the reported cases were treated additionally by adding some other unlicensed treatments, such as tocilizumab, hydroxychloroquine, convalescent plasma or IVIG [2].

In this case, the patient was a recent recipient of a kidney transplant 2 weeks before exposure and infected by the virus. It is likely those receiving a solid organ transplant will have the highest immunosuppression levels. In addition to this, his age (74) already puts him in the ‘at risk’ category, with a mortality rate of (7.2 to 8.9%) [4]. In the absence of any agreed guidelines, the patient was discussed locally between the multidisciplinary team. The agreed approach was to exclude any other cause for his symptoms, such as pneumocystis carinii pneumonia (PCP), CMV and EBV. Urine and blood cultures were negative for infection. Following on from this, the patient was commenced on Meropenem empirically. The decision was made to discontinue his anti-proliferative immunosuppressant (Mycophenolate) but continue his adopt and prednisolone. As this was a recent live-related transplant, the difficulties were in modifying immunosuppression in such a manner as to allow the patient to be supported throughout the illness, whilst allowing immune response to the infection. Minimizing rejection and graft loss was also a priority.

Following further discussion, our patient was enrolled in the ongoing hydroxychloroquine clinical trial. Patients were segregated into 2 groups: One receiving hydroxychloroquine and the other received a placebo. Our patient was allocated to the placebo group, so no further

therapies were initiated other than those previously discussed. After 10 days of admission, the patient's condition improved significantly. Oxygen saturations were maintained above 97% on room air, and supplemental therapy was no longer required. Based on further clinical improvement, he was discharged home on day 11.

Conclusion

In summary, we report a case of COVID-19 Pneumonia in a 74-year-old male live-related transplant recipient, who was successfully treated by omitting his anti-proliferative immunosuppressant. This measure omitted the need for any unlicensed medications, avoiding mechanical ventilation. As the natural course of COVID-19 in renal transplant patients remains unclear, we acknowledge that outcomes obtained from a single case report are difficult to generalize with limitations. However, given the rapid growth of the COVID-19 pandemic, we believe it is of great importance to report management of such cases in a high-risk cohort.

In the lack of a consensus about the best approach to treat patients with COVID-19, especially the population of kidney transplant recipients, we believe that stopping the Anti-proliferative immunosuppressant during the acute phase of COVID-19 infection, while maintaining the other immunosuppressant, will help in both survival of the patient while maintaining good graft function.

Conflicts of Interest

None.

Funding

None.

REFERENCES

1. Yi Chi Wu, Ching Sung Chen, Yu Jiun Chan (2020) The outbreak of COVID-19: An overview. *J Chin Med Assoc* 83: 217-220. [[Crossref](#)]
2. Francesco Fontana, Gaetano Alfano, Giacomo Mori, Alessio Amurri, Lorenzo Tei et al. (2020) COVID-19 pneumonia in a kidney transplant recipient successfully treated with tocilizumab and hydroxychloroquine. *Am J Transplant* 20: 1902-1906. [[Crossref](#)]
3. Nanshan Chen, Min Zhou, Xuan Dong, Jieming Qu, Fengyun Gong et al. (2020) Epidemiological and clinical characteristics of 99 cases of 2019 novel coronavirus pneumonia in Wuhan, China: a descriptive study. *Lancet* 395: 507-513. [[Crossref](#)]
4. Jason Oke, Carl Heneghan (2020) Global Covid-19 case fatality rate. CEBM, Centre of Evidence Based Medicine.