

Available online at [www.sciencerepository.org](http://www.sciencerepository.org)

Science Repository



## Case Report

# Repair with Gonadal Vein Patch in the Unexpected Left Renal Vein Injury During Donor Nephrectomy

M. Fatih Yuzbasioglu<sup>1\*</sup>, Sezgin Topuz<sup>1</sup>, Alper Boz<sup>2</sup>, Onur Peker<sup>3</sup>, Nazmi Özer<sup>4</sup> and Ali İşler<sup>1</sup>

<sup>1</sup>Department of General Surgery, Sütçü İmam University School of Medicine, Kahramanmaraş, Turkey

<sup>2</sup>Department of General Surgery, Ortaca Yücelen Hastanesi, Muğla, Turkey

<sup>3</sup>Department of General Surgery, Çine Devlet Hastanesi, Aydın, Turkey

<sup>4</sup>Department of General Surgery, Sağlık Bilimleri University, Adana Şehir Hastanesi, Adana, Turkey

### ARTICLE INFO

#### Article history:

Received: 22 April, 2020

Accepted: 5 May, 2020

Published: 29 June, 2020

#### Keywords:

Left renal vein

gonadal vein

renal transplantation

### ABSTRACT

**Objective:** The objective of this presentation is to share our experiences with an unusual repair of a defective graft renal vein using an own gonadal vein, which occurred iatrogenically during a laparoscopic donor nephrectomy.

**Case Report:** A 35-year-old man with situs inversus totalis was referred to our clinic for a living-related renal transplant with a diagnosis of end-stage renal disease. The donor was 66-year-old mother of the patient. Laparoscopic left donor nephrectomy was planned for his mother. At the end of laparoscopic dissection renal vein tear occurred during the renal extraction. Without any intervention renal extraction was performed to maintain the patency of renal allograft and to stabilize the donor. Partial hemorrhage from renal vein was brought under control. Donor nephrectomy was completed with a defective remaining segment of renal vein. We decided to repair with gonadal vein patch in the unexpected renal vein injury. Patch from tearing part of renal vein with short gonadal vein repairment was performed. After repairment of graft renal vein, anastomosis to external iliac vein was performed. The trans-plant procedure was completed successfully. The kidney functioned immediately. Doppler ultrasound revealed that perfusion of the kidney was normal. The postoperative creatinine levels of recipient were in the normal ranges. Daily urine output was normal.

**Conclusion:** Repairment of a defective graft renal vein by using own gonadal vein seems to be a simple, safe, and reliable method. This technique provides an alternative approach for the reconstruction of vessels in living-donor kidney transplants.

© 2020 Mehmet Fatih Yuzbasioglu. Hosting by Science Repository.

## Introduction

Renal transplant is the most effective treatment in end-stage renal disease. Living-donor transplants are being widely used, as organ need is increasing daily, whereas there are not enough deceased donors. Also, as minimally invasive interventions are being widely used and are becoming more popular because of quick recovery time, low postoperative pain, low complication rates, and low missed time from work, laparoscopic donor nephrectomy has become more preferred in renal transplants. This procedure has some drawbacks (eg, unexpected bleeding in major bleedings during surgery, risk of graft ischemia, injury

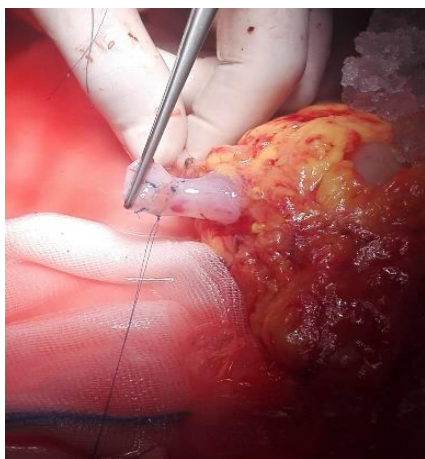
or laceration of donor kidney artery, vein, or ureter). Surgical trauma to the vessels may cause a functional obstruction because of adherence of the vessel anastomosis. The objective of this case report is to share our experiences with an unusual repair of a defective left graft renal vein using a own gonadal vein, which occurred iatrogenically during a laparoscopic donor nephrectomy.

## Case Report

A 35-year-old man with situs inversus totalis was referred to our clinic for living-related renal transplant. He had a diagnosis of end-stage renal

\*Correspondence to: Mehmet Fatih Yuzbasioglu, Department of General Surgery, Sütçü İmam University School of Medicine, Kahramanmaraş, Turkey; E-mail: [f\\_yuzbasioglu@hotmail.com](mailto:f_yuzbasioglu@hotmail.com)

disease for 14 months and had been undergoing hemodialysis for 9 months. The donor was with his mother, she had a complete ABO match, 3 mismatches, and she was cross negative. Laparoscopic left donor nephrectomy was planned for his mother. All procedures have been done in its classical routine. At the end of laparoscopic dissection renal vein tear occurred during the renal extraction. Without any intervention renal extraction was performed to maintain the patency of renal allograft and to stabilize the donor. Partial hemorrhage from renal vein was brought under control. Donor nephrectomy was completed with a defective remaining segment of renal vein and graft kidney was removed to back table, with a defective remaining segment of renal vein (Figure 1). The right external iliac vein segment of recipient was also not released enough, limiting a successful transplant.



**Figure 1:** Renal vein with a gonadal vein patch.

If we sacrificed the defective part of renal vein, anastomosis of the renal vein was under risk of fail. Repairment of graft renal vein using a small part of gonadal vein of the same side which standing on renal vein as a part of teared segment. We decided to repair with gonadal vein patch in the unexpected renal vein injury. After repairment of graft renal vein, anastomosis to external iliac vein End-to-side anastomosis was performed using 6/0 polypropylene. The transplant procedure was completed successfully, and the patient was transferred to transplant unit. The transplant procedure was completed successfully. The kidney functioned immediately. Doppler ultrasound revealed that the perfusion of the kidney was normal. The postoperative creatinine levels of recipient were within normal ranges, and there was no need for dialysis. Daily urine output was normal. There were no additional surgical problems, and the patient was discharged. There were no problems in graft functions during routine follow-ups for 2 years.

## Discussion

There are numerous reports about elongation of a short right graft renal vein by a gonadal vein, and it seems to be a safe and efficient method; however, there is a paucity of data about repairment of teared part of renal vein using a gonadal vein [1-3]. In a previous study, the gonadal vein was used for anastomosis of parallel 3 polar arteries to external iliac artery by union on gonadal vein patch, and this method has brought a new perspective for approaching to multiple renal arteries [4]. It is useful, especially in right laparoscopic donor nephrectomy, to elongate

short right renal veins [5]. The gonadal vein is preferred because it is accessible during the donor nephrectomy and can be ligated safely without additional morbidity to the donor. It can be reconstructed in a circular or spiral lengthening method. Also, recipients in whom the gonadal vein is not preserved have been found to have similar urologic complication rates compared with other patients; for that reason, transplant surgeons should not hesitate to use a gonadal vein for the elongation of a renal artery or vein [6]. The gonadal vein is essentially useless and is easily accessed during the donor nephrectomy.

In another study, the gonadal vein graft was used successfully to implant the polar renal artery during a living-donor renal transplant [7]. According to technical problems because of vascular pathologies, sometimes prosthetic vascular implants can be used in renal allograft transplants. It is known that these grafts do not influence the renal functions on short-term and long-term follow-ups, but technical difficulties during implantation are stated [8]. We emphasized that nonprosthetic vascular grafts (e.g., the gonadal vein should be used instead of prosthetic ones because their biological nature and ease of handling). To repair a defective renal vein, use of a gonadal vein patch should be a good choice. Repairment of a defective graft renal vein by using gonadal vein seems to be a simple, safe, and reliable method. This technique provides an alter-native approach for the reconstruction of defective part of vessels in living-donor kidney transplants.

## REFERENCES

1. El-Hinnawi A, Sageshima J, Uchida K, Chen L, Burke GW et al. (2012) New technique in using the gonadal vein in lengthening the right renal vein in living donor kidney transplant. *Transplantation* 94: e40-e41. [[Crossref](#)]
2. Scott D (2012) Renal vein lengthening using gonadal vein reduces surgical difficulty in living-donor kidney transplantation. *World J Surg* 36: 473-474. [[Crossref](#)]
3. Mikhalski D, Hoang AD, Bollens R, Laureys M, Loi P et al. (2007) Gonadal vein reconstruction for extension of the renal vein in living renal transplantation: Two case reports. *Transplant Proc* 39: 2681-2684. [[Crossref](#)]
4. He B, Mitchell A (2012) A novel technique for reconstruction of multiple renal arteries in live donor kidney transplantation: a case report and literature review. *Transplant Proc* 44: 3055-3058. [[Crossref](#)]
5. Feng JY, Huang CB, Fan MQ, Wang PX, Xiao Y et al. (2012) Renal vein lengthening using gonadal vein reduces surgical difficulty in living-donor kidney transplantation. *World J Surg* 36: 468-472. [[Crossref](#)]
6. Aliasgari M, Shakhssalim N, Dadkhah F, Ghadian A, Moghaddam SM (2008) Donor nephrectomy with and without preservation of gonadal vein while dissecting the ureter. *Urol J* 5: 168-172. [[Crossref](#)]
7. Chatzizacharias NA, Muthusami AS, Sullivan M, Sinha S, Brockmann J (2010) Use of gonadal vein interposition graft for implantation of polar artery in live donor renal transplantation. *Transplantation* 90: 1131-1132. [[Crossref](#)]
8. Patrono D, Verhelst R, Buemi A, Goffette P, De Pauw L et al. (2013) Renal allograft implantation on prosthetic vascular grafts: short- and long-term results. *World J Surg* 37: 1727-1734. [[Crossref](#)]