

Available online at [www.sciencerepository.org](http://www.sciencerepository.org)

Science Repository



## Case Report

# Giving Nature a Second Chance: Minimally Invasive Management of a Maxillary Central Incisor with a Severe Traumatic Lesion

Mohammad Hossein Dashti<sup>1\*</sup>, Roxana Hashemian<sup>2</sup>, Nahal Panah<sup>3</sup> and Deyar Dashti<sup>4</sup>

<sup>1</sup>Clinical Associate Professor, Division of Postdoctoral Prosthodontics, Department of Restorative Sciences and Biomaterials, Boston University Henry M. Goldman School of Dental Medicine, Boston, Massachusetts, USA

<sup>2</sup>Clinical Instructor, Department of General Dentistry, Boston University Henry M. Goldman School of Dental Medicine, Boston, Massachusetts, USA

<sup>3</sup>Private practice, Melrose, Massachusetts, USA

<sup>4</sup>Department of Graduate Medical Sciences, Boston University School of Medicine, Boston, Massachusetts, USA

### ARTICLE INFO

#### Article history:

Received: 20 June, 2020

Accepted: 3 July, 2020

Published: 9 July, 2020

#### Keywords:

Endodontics

natural teeth

minimally invasive

dental implants

### ABSTRACT

The decision to save or extract a natural tooth which has been compromised is one of the dilemmas of dental practitioners, as well as the patients. Although there was a considerable effort to save the natural teeth in the past, with the introduction of osseointegrated implants, there is a tendency to extract the compromised teeth and replace them with implant-supported prosthesis. In this article, this important clinical decision is investigated, and a successful restoration of a traumatized anterior tooth is presented.

© 2020 Mohammad Hossein Dashti. Hosting by Science Repository.

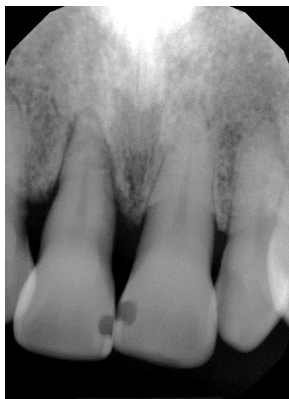## Introduction

Trauma to the dental pulp and periodontal tissues is different from other etiologic factors which cause their pathologic changes. Instead of following the progression from coronal to radicular sites, the injury with trauma can occur directly at any level of the dental or periradicular tissues. The injury can occur directly to the pulp, root apex, cementum, periodontal ligament or surrounding bone individually or in combination. This renders the pulp and periodontal tissues less resistant to bacterial invasion that accompanies the trauma [1]. The majority of dental trauma in both the primary and permanent dentition involves the anterior teeth. The maxillary central and lateral incisors were the most common teeth injured [2]. Traumatic dental injuries and their consequences may exceed the burden of caries and periodontal disease in the young population [3, 4]. The purpose of this case report is to exemplify a minimally invasive approach in management of traumatic lesion of an anterior tooth, which would have been deemed hopeless otherwise.

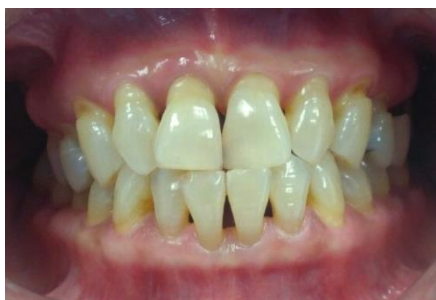## Case Presentation

Patient was a 50-year-old female with no contributory medical history and no known allergies. She presented with an acute periapical abscess and a mobile right maxillary central incisor, which started after a 'slip and fall' accident two days prior to her emergency visit to the dental office. She had a history of generalized chronic mild to moderate periodontitis with localized severe periodontitis in the maxillary central teeth (Figure 1). Her periodontal condition had been managed with surgical treatments and she was on a routine recall and maintenance program, with stable and maintainable oral health. Her oral hygiene had improved significantly ever since (Figure 2). A periapical digital radiograph showed a large periradicular radiolucency, measuring about 8x5 mm, on the distal aspect of the root of right maxillary central incisor (Figure 3). Tooth demonstrated a mobility of 2, according to Miller's classification of tooth mobility and a purulent sinus tract on the corresponding labial oral mucosa [5].

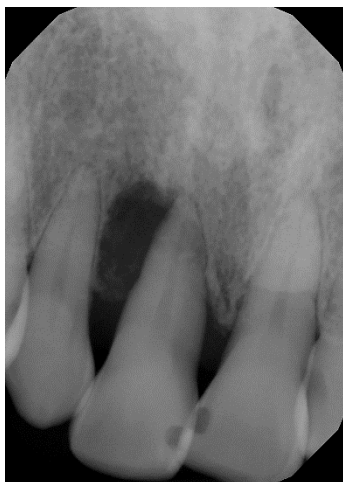\*Correspondence to: Mohammad Hossein Dashti, D.M.D., F.A.C.P., Diplomate American College of Prosthodontics, Clinical Associate Professor, Division of Postdoctoral Prosthodontics, Department of Restorative Sciences and Biomaterials, Boston University Henry M. Goldman School of Dental Medicine, Boston, Massachusetts, USA; E-mail: [mhdashti@bu.edu](mailto:mhdashti@bu.edu)



**Figure 1:** Periapical radiograph, 6 months prior to trauma.



**Figure 2:** Intraoral photograph.

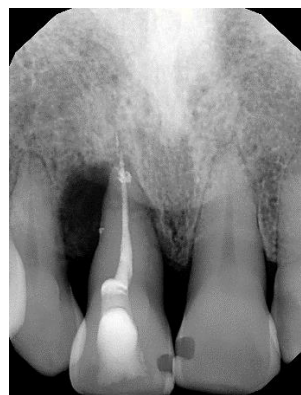

**Figure 3:** Periapical radiograph, after trauma.

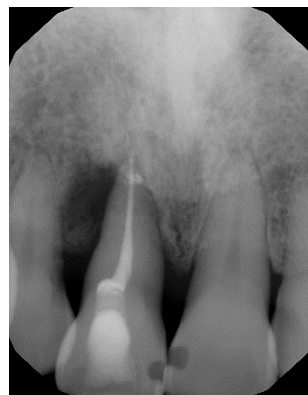
Based on the clinical and radiographic findings, drainage was achieved by preparing an endodontic access on the cingulum area and piercing the pulp with an endodontic file (K-File, Premier). Gentle compression of the labial mucosal tissue enhanced the drainage of infection and continued until there was no purulent exudate visible and normal bleeding was initiated. The canal was irrigated with 5% sodium hypochlorite solution and was left open for continued drainage, until the next appointment [6]. A prescription for antibiotic was given (Amoxicillin 500 mg, every 8 hours and Metronidazole 500 mg, every 6 hours, for one week) [7]. Over-the-counter analgesic (Ibuprofen 200 mg) was recommended for pain control. Patient was seen for a follow up two days later. The swelling was considerably subsided and there was no complaint of pain. The canal was inspected and closed with a cotton

pellet and zinc oxide/calcium sulfate temporary filling material (Cavit G, 3M-ESPE) [6].

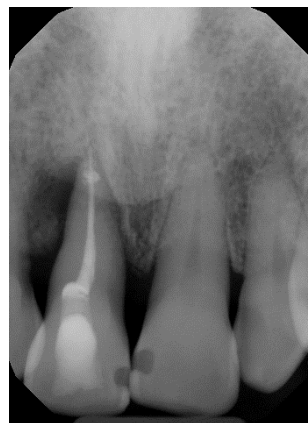After one week from the initial appointment, the canal was cleaned and shaped and the endodontic treatment was completed, following the standard protocol (Figure 4) [8]. The access cavity was subsequently restored with composite resin material (Tetric Evoceram, Ivoclar Vivodent). Periapical radiographs taken after 2 weeks, one month, 2 months, 3 months and 6 months show gradual resolution of the lesion (Figures 5-9). Concomitant with healing of the lesion, the mobility of the tooth had been improved significantly and was comparable to the adjacent teeth. To further protect her dentition from occlusal trauma, a night guard was fabricated, and the patient was put on a 4-month recall for oral hygiene and examination (Figure 10).



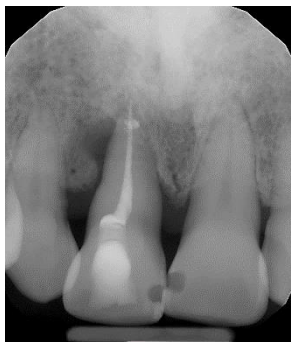**Figure 4:** Periapical radiograph, after root canal therapy.



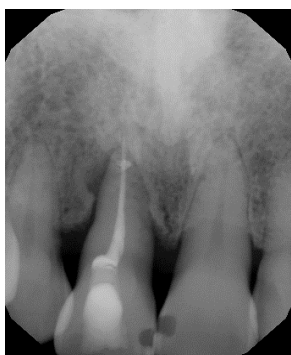
**Figure 5:** Periapical radiograph, 2 weeks post-operative.



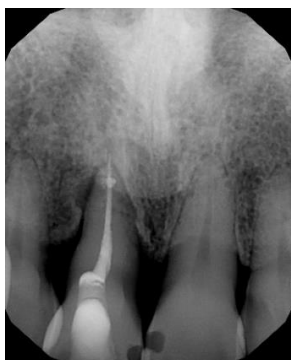**Figure 6:** Periapical radiograph, 1 month postoperative.



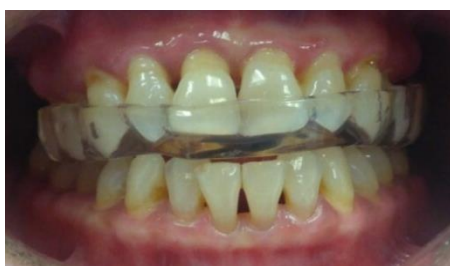**Figure 7:** Periapical radiograph, 2 months postoperative.



**Figure 8:** Periapical radiograph, 3 months postoperative.



**Figure 9:** Periapical radiograph, 6 months postoperative.



**Figure 10:** Intraoral photograph, night guard in place.

### Discussion and Conclusion

With the introduction of osseointegrated dental implants, dental profession has experienced an unprecedented autonomy in oral rehabilitation. Dentists can offer much more conservative and predictable treatment options to their patients, than ever before. Remaining sound natural teeth don't need to be aggressively prepared to

be used as abutments for fixed partial dentures or patients don't have to suffer from loose dentures. Together with these great benefits however, dentists now face a new dilemma: Is the natural tooth worth saving when the outcome of conventional treatment modalities are not predictable? This is a challenging decision for both the dentist and the patient. In the presented case, there was no need for a post and a crown since the remaining tooth structure was sound. However, in many situations the traumatized teeth sustain chippings or fractures which may require indirect restorations. This would further complicate the decision-making process, mainly due to additional cost which may be comparable to an implant restoration.

However, as it was shown in this report, a natural tooth can be saved and maintained, provided that the patient is informed about the possible risks and a proper treatment is rendered. Finally, the risks involved do not only pertain to the natural teeth; implants can fail too. But when a tooth is extracted, there is no other choice but to place an implant. The high survival rates of compromised teeth that were properly treated and maintained, were shown to surpass the survival rates of dental implants in a long-term follow up [9].

In the above case, the adjacent teeth were periodontally compromised and could not be used as abutments for a fixed partial denture. A removable partial denture was not indicated for the same reason, as well as the patient's objection to wear a removable appliance for her anterior tooth. With proper maintenance, the treated tooth may serve for several years, at which point, she will have an option of extraction of any compromised adjacent teeth and receive an implant supported fixed prosthesis.

### REFERENCES

1. Fouad A (2019) Microbiological aspects of traumatic injuries. *Dent Traumatol* 35: 324-332. [[Crossref](#)]
2. Glendor U (2009) Aetiology and risk factors related to traumatic dental injuries—a review of the literature. *Dent Traumatol* 25: 19-31. [[Crossref](#)]
3. Lam R (2016) Epidemiology and outcomes of traumatic dental injuries: A review of the literature. *Aust Dent J* 61: 4-20. [[Crossref](#)]
4. Flores MT, Andersson L, Andreassen JO, Bakland LK, Malmgren B et al. (2007) Guidelines for the management of traumatic dental injuries. I. Fractures and luxations of permanent teeth. *Dent Traumatol* 23: 66-71. [[Crossref](#)]
5. Wu C, Tu Y, Lu S, Chang J, Lu H (2018) Quantitative analysis of Miller mobility index for the diagnosis of moderate to severe periodontitis - A cross-sectional study. *J Dental Sci* 13: 43-47. [[Crossref](#)]
6. Jafine B (2013) Management of a Necrotic Tooth with Unstoppable Drainage. *J Can Dent Assoc* 79: d118. [[Crossref](#)]
7. Segura Egea JJ, Gould K, Hakan Sen B, Jonasson P, Cotti E et al. (2017) Antibiotics in endodontics: A review. *Int Endod J* 50: 1169-1184. [[Crossref](#)]
8. Torabinejad M, Fouad A, Shabahang S (2020) Endodontics: Principles and Practice. 6<sup>th</sup> Edition. Elsevier.
9. Clark D, Levin L (2019) In the Dental Implant Era, Why Do We Still Bother Saving Teeth? *Dent Traumatol* 35: 368-375. [[Crossref](#)]