

Available online at www.sciencerepository.org

Science Repository



Case Report

Illustration by Two Cases of the Treatment of Axillary Verneuil Disease with a TDAP Flap

M. Raboune*, S. El Harrak, I. Moqfi, J. Hafidi, S. El Mazouz, N. Gharib and A. Abbassi

Department of Plastic Surgery and Burns, Ibn Sina Hospital, Rabat, Morocco

ARTICLE INFO

Article history:

Received: 15 June, 2020

Accepted: 25 June, 2020

Published: 4 July, 2020

Keywords:

Verneuil's disease

hidrosadenite suppurativa

TDAP flap

perforator flap

ABSTRACT

In this article, we have described two cases of Verneuil's disease (H.S) which benefited from radical surgical excision, and followed by reconstruction of the axillary region with a TDAP perforator flap, and we carried out a literature review to highlight the interest of this technique and compare it with other therapeutic options in terms of complications, and also the functional and aesthetic outcome.

© 2020 Mohamed Raboune. Hosting by Science Repository.

Introduction

Described in 1854 by Verneuil, the disease is a chronic, suppurative, fistulating and scarring condition of the pilo-sebaceous follicles of the skin regions where apocrine glands are present: axillary hollows, groin region, anogenital region, areolas, submammary folds, neck and post auricular space.

The diagnosis of Verneuil's disease is clinical. It begins in adolescents and young adults, more frequently in women, with sub-skinned, mobile and painless nodules isolated from each other, polyporous comedons, microcysts and papulo-pustules.

Some forms remain moderate, compatible with a completely normal life and require only medical treatment which include both topic and systemic therapies. But sometimes the disease leads, in severe forms to recurrent inflammatory follicular nodules, papules, pustules and painful abscesses with malodorous discharge and the formation of a fibrous tissue with retractable straps leading to considerable physical and psychological effects; in this case: radical surgical excision with free margins appears to be the gold standard.

The challenge then is to cover the defect. Skin graft, local, regional flaps such as the V-Y flap, the IC flap, Limberg and musculocutaneous flap, have been used for the reconstruction of the soft tissue defect following excision of severe extensive axillary HS. Perforator flaps such as the thoracodorsal artery perforator flap, have been used widely for several anatomical areas, and its versatility makes it a workhorse flap for most reconstructions requiring soft tissue cover. The aim of this article is to demonstrate the interest of this flap in covering of the axillary defects comparing to other techniques.

Case Report I

A 34 years old male patient with no medical history, was presented to our department with a Hurley stage III. The patient had recurrent and severe chronic axillary lesions: abscesses, draining sinuses, and bridged scars. Due to medical treatment failure, physical discomfort and significant psychological impact, it was agreed to undergo surgery (Figure 1). Radical excision with safe margins was performed followed by defect reconstruction of a 25x10cm TDAP flap. Postoperative course were uneventful and was discharged from hospital on the 2nd day.

*Correspondence to: Mohamed Raboune, Department of Plastic Surgery and Burns, Ibn Sina Hospital, Rabat, Morocco; E-mail: mraboune@gmail.com

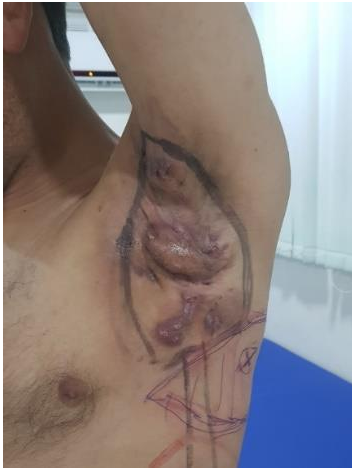

Figure 1: Pre operative markings.

Case Report II

A 25 years old, male smoker with no pre-existing pathological history was presented to our department with Hurley stage III. Radical excision was done followed by a 20x10cm TDAP flap to cover the defect. The patient remained in hospital under medical observation because of flap congestion, which was managed by scarifying the flap, and the patient was released 5 days later (Figures 2).

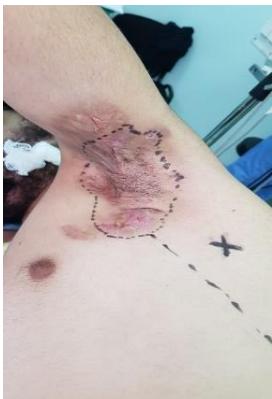

Figure 2: Pre operative markings.

Discussion

HS is a chronic disease. Its treatment include both medical and surgical interventions. Yet, radical surgical excision is the only procedure that has been shown to be effective in advanced stages [1-3]. A doppler color was used to localise perforators 6 to 16cm below the apex of axilla, and 1 to 2cm inside of the later border of the latissimus dorsi muscle (Figure 3), as described by angrigiani in his statistical anatomical localization [4]. The design of the flap is elliptical, and the orientation is perpendicular to the midline in a transverse and oblique direction; along the axis of the linking vessels. Flaps of 15-20 cm can be safely harvested on a single reliable perforator [5].

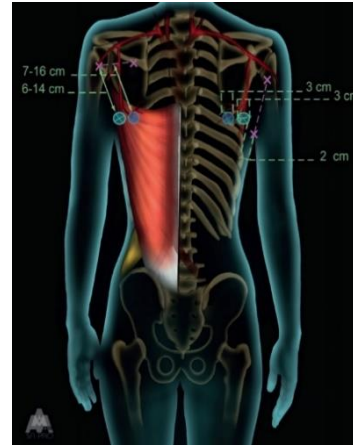


Figure 3: Grouping of thoraco-dorsal artery perforators (Atlas of the perforating arteries of the skin, trunk and limbs. Fabien Boucher *et al.* i Mojallal).

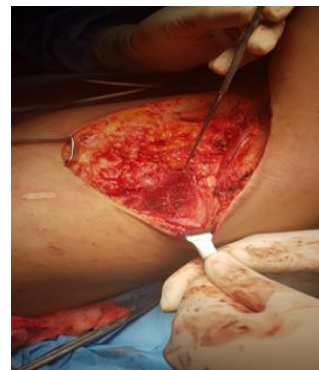

Figure 4: Musculo cutaneous perforator.

Hwang *et al.* described that longer flaps can be raised by using the various modifications to ensure perfusion either by including more than one perforator from the same branch of thoracodorsal vessel or perforators from different branches of thoracodorsal artery and also by including the intercostal artery perforator at the distal end of the flap (12) article thoracodorsal artery flap indeed a versatile flap [6]. The patient is placed in lateral decubitus, arm in abduction and elbow at 90 degree. The flap is raised from posterior to anterior above the muscle, care has to be taken not to injure the perforators with a very gentle dissection. In the first patient, a musculocutaneous perforator was found, and dissection was carried out until the emergence of the pedicle (Figure 4).

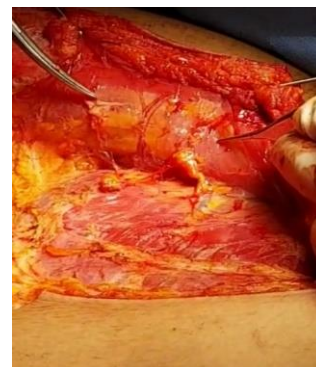

Figure 5: Septo-cutaneous perforator.

The perforator may not be skeletonized by keeping a 2cm muscle collar around it, in order to reduce the operating time and increase the venous drainage [7]. While in the second case, we encountered a very thin septocutaneous perforator (Figure 5), we noticed at the end of dissection that the perforator spasmed and the vascularization of the flap was precarious and we inset the latter as a propeller fashion. The nerve was spared, and the donor side was primarily closed in two layers with drain in both cases (Figures 6 & 7).

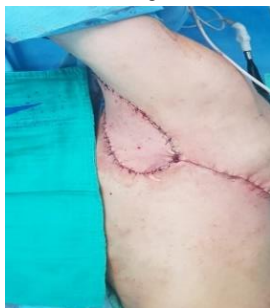

Figure 6: Immediate post-operative aspect and primary closure.

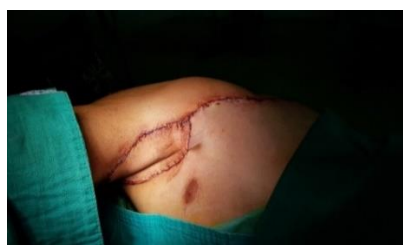

Figure 7: Immediate post-operative aspect.

Skin grafts can be associated with a dermal matrix, but these have the disadvantage of realizing a patch effect without bringing significant volume. A study conducted in 2018 compared between the perforator flaps and dermal matrix in terms of quality of life, healing time, length of care giving, resumption of professional activity and long term coverage quality; demonstrated the superiority of the perforator flaps versus dermal matrix in addition to reducing the risk of recurrence [8].

Similar study in 2014 worlmand *et al.* highlighted the superiority of perforator flaps over thin skin graft in terms of postoperative course and quality of life on 27 patients [9]. Directed healing is still a therapeutic alternative, but the major shortcomings are healing time, pain and postoperative skin contractures. They have been followed up to one year and both of patients were very satisfied and resumed very soon their activities and none of them complained about the functional outcome.

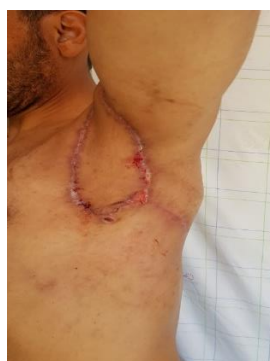

Figure 8: 1-month post-operative aspect.

A study conducted between November 2013 and June 2015 including 17 patients treated by local perforator flaps showed that the axillary reconstruction with TDAP flaps has a complete healing period of twenty days and improved quality of life with preserved mobility and very good functional outcome. The same study shows that the recurrence rate was 0% over a period of 279 days [10]. Another study conducted by Aharbi *et al.* compared the TDAP flap with other surgical techniques in term of recurrence, and the rate was very high in the case of direct suture or skin graft (41 evaluation of the mobility of the shoulder and the quality of life) They have not complained about the scar that has fade overtime (Figures 8 & 9) [11].

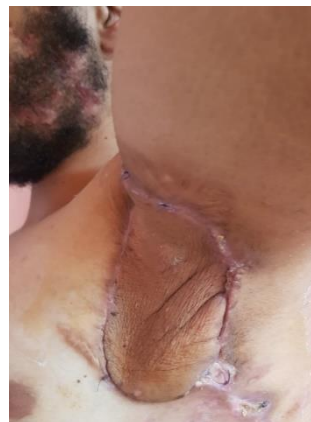

Figure 9: 1-month post-operative aspect.

Conclusion

After radical surgical excision of Verneuil's disease, the reconstruction of axillary defects by TDAP flap remains an interesting therapeutic option. TDAP flap is able to be adapted to many different situations, easy to harvest, preserves fully the function of the latissimus dorsi muscle, and in case the perforator is injured there are a range of lifeboat flaps in the surgical field. In comparison with other techniques, TDAP flap seems to have less complications and better functional results.

REFERENCES

1. Lixia Z Ellis (2012) Hidradenitis suppurativa: surgical and other management techniques. *Dermatol Surg* 38: 517-536. [[Crossref](#)]
2. Cen Hung Lin, Kao Ping Chang, Shu Hung Huang (2016) Deroofing: an effective method for treating chronic diffuse hidradenitis suppurativa. *Dermatol Surg* 42: 273-275. [[Crossref](#)]
3. Oktay Büyükaşık, Ahmet Oğuz Hasdemir, Nurettin Kahramansoy, Cavit Çöl, Hayri Erkol (2011) Surgical approach to extensive hidradenitis suppurativa. *Dermatol Surg* 37: 835-842. [[Crossref](#)]
4. C Angrigiani, D Grilli, J Siebert (1995) Latissimus dorsi musculocutaneous flap without muscle. *Plast Reconstr Surg* 96: 1608-1614. [[Crossref](#)]
5. Leena Jain, Samir M Kumta, Shrirang K Purohit, Rashmi Raut (2015) Thoracodorsal artery perforator flap: indeed a versatile flap. *Indian J Plast Surg* 48: 153-158. [[Crossref](#)]
6. Jin Hee Hwang, So Young Lim, Jai Kyong Pyon, Sa Ik Bang, Kap Sung Oh *et al.* (2011) Reliable harvesting of a large thoracodorsal artery

- perforator flap with emphasis on perforator number and spacing. *Plast Reconstr Surg* 128: 140 e-150e. [[Crossref](#)]
7. R Vaucher, S Dast, A Bout Roumazeilles, C Herlin, F Bekara et al. (2019) Harvesting method of thoracodorsal perforator flap: adaptation. *Ann Chir Plast Esthet* 64: 266-270. [[Crossref](#)]
 8. J Gibrila, B Chaput, F Boissière, M Atlan, S Fluieraru et al. (2019) Radical treatment of hidradenitis suppurativa: comparison of the use of the artificial dermis and pedicled perforator flaps. *Ann Chir Plast Esthet* 64: 224-236. [[Crossref](#)]
 9. Justin C R Wormald, Antonella Balzano, Jonothan J Clibbon, Andrea Figus (2014) Surgical treatment of severe hidradenitis suppurativa of the axilla: thoracodorsal artery perforator flap TDAP versus split skin graft. *Plast Reconstr Aesthet Surg* 67: 1118-1124. [[Crossref](#)]
 10. R Nail-Barthelemy, N Stroumza, Q Qassemyar, M Delage, A Nassif et al. (2019) Evaluation of the mobility of life after perforator flaps for recalcitrant axillary hidradenitis. *Ann Chir Plast Esthet* 64: 68-77. [[Crossref](#)]
 11. Ziyad Alharbi, Jens Kauczok, Norbert Pallua (2012) A review of wide surgical excision of hidradenitis suppurativa. *BMC Dermatol* 12: 9. [[Crossref](#)]