

Available online at www.sciencerepository.org

Science Repository



Case Report

Pulmonary Artery Migration of a Peripheral Endovascular Stent Discovered Prior to Renal Transplantation: A Case Report

Angela Lee*, David Perrault, Peter A. Than, Aleah L. Brubaker and Marc L. Melcher

Stanford University School of Medicine, Pasteur Drive, Stanford, California, USA

ARTICLE INFO

Article history:

Received: 8 June, 2020

Accepted: 18 June, 2020

Published: 26 June, 2020

Keywords:

Hemodialysis

endovascular stent

stent migration

renal transplantation

ABSTRACT

Background: Arteriovenous fistulas and grafts are preferred access for hemodialysis. Outflow stenosis is a common complication that can be managed with angioplasty and stenting. Stent placement can be complicated by thrombosis, limited area of cannulation, fracture, and migration.

Objective: This case reports a rare complication of endovascular stents, namely stent migration to the pulmonary artery in the setting of renal transplantation.

Methods: A 55-year-old woman with end stage renal disease secondary to diabetes mellitus on hemodialysis via a left arm basilic vein transposition. She subsequently developed outflow stenosis that was treated with a stent placement. She was admitted for deceased donor kidney transplantation and preoperative x-ray showed migration of the stent into a segmental pulmonary artery. After a pre-operative, multidisciplinary discussion between interventional radiology, cardiothoracic surgery, transplant nephrology and transplant surgery, the decision was made to proceed with renal transplantation followed by stent removal. Interventional radiology removed the stent on postoperative day two without complication. She has not experienced any complications in the year following her transplantation.

Conclusion: Postoperative stent removal by interventional radiology is a feasible management option in lieu of lifelong anticoagulation.

© 2020 Angela Lee. Hosting by Science Repository.

Introduction

Hemodialysis is a mainstay of renal replacement therapy, necessitating placement of either a central venous catheter (CVC), arteriovenous fistula (AVF), or arteriovenous graft (AVG). While CVCs still account for 72% of initial hemodialysis access, almost 80% of patients on the national kidney registry utilize an AVF or AVG for hemodialysis [1, 2]. Up to 50% of AVF can develop juxta-anastomotic stenosis within the first 4-6 weeks following creation, with primary patency of 51% at one year [3, 4]. The principal intervention for stenosis is percutaneous angioplasty; should this fail, endovascular stent placement and surgery are subsequent options. Complications of stent placement include in-stent thrombosis, limited area of cannulation, stent fracture, and stent migration. The first case of stent migration in an end-stage renal disease (ESRD) patient was reported in 1994 [5]. Since then, endovascular stent

migration has been reported in up to 4% of patients [6]. The right atrium, right ventricle, and pulmonary arteries are the most lethal destinations of stent migration due to the possibility of complete vascular obstruction [7]. Post-kidney transplant patients are especially vulnerable to negative sequelae of stent migration given their increased chronic hypercoagulability and the subsequent risk of pulmonary embolism [8].

Here, we report a case of vascular stent migration from a left basilic vein-brachial artery fistula to the right interlobar pulmonary artery that was found incidentally during the preoperative evaluation of a kidney transplant recipient. As stated in institutional policy, case studies do not require IRB review. Per our review of the literature, this is the first report of vascular stent migration and successful retrieval in a kidney transplant recipient.

*Correspondence to: Angela Lee, A.B., Stanford University School of Medicine, 300 Pasteur Drive, 94305, Stanford, California, USA; Tel: 5126275221; ORCID: 0000-0002-5577-1078; E-mail: Angelal4@stanford.edu

Case Presentation

A 55-year-old woman with end-stage renal disease secondary to type II diabetes mellitus (DM) presented for pre-operative evaluation prior to renal transplantation. She was started on hemodialysis via an indwelling CVC and subsequently underwent creation of a left arm basilic vein transposition. A suitable deceased donor kidney became available and the patient was brought to the hospital for pre-operative evaluation in anticipation of transplantation. On routine preoperative chest X-ray, a three cm stent was incidentally found in a right interlobar pulmonary artery (Figure 1). In a review of the patient's history, she had developed outflow stenosis of her AVF five months prior and underwent placement of an endovascular stent at an outside facility.

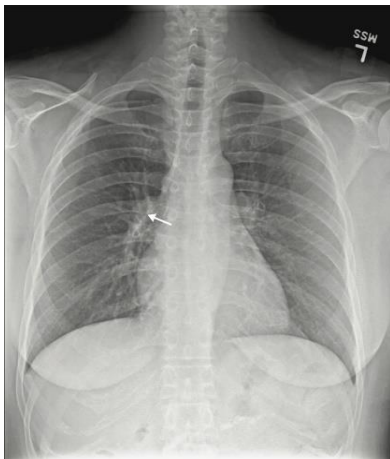


Figure 1: Pre-operative chest radiograph with an incidental pulmonary artery stent (marked by arrow).

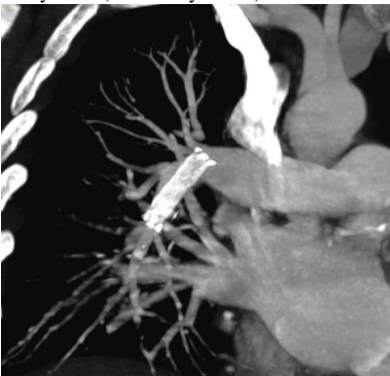


Figure 2: Computed tomography of the chest with migration of the stent in the right interlobar pulmonary artery.

CT angiography of the chest was performed and confirmed stent migration to the right interlobar pulmonary artery with extension into the lower lobe pulmonary artery (Figure 2). There was no evidence of thrombosis. Given the location of the stent, there was concern for the potential development of in-stent thrombosis and propagation within the pulmonary artery, erosion of the stent into the pulmonary artery, and increased right heart pressure. Echocardiography demonstrated a normal ejection fraction with a normal right ventricle function and normal right atrial pressures. Cardiothoracic surgery and interventional radiology were consulted. After a multidisciplinary discussion, the peri-operative risk of the newly discovered pulmonary artery stent was deemed acceptable as there was no appreciable right heart strain on

echocardiogram and the vasculature appeared patent. The consensus was to proceed with renal transplantation with either subsequent lifelong anticoagulation or post-operative stent retrieval.

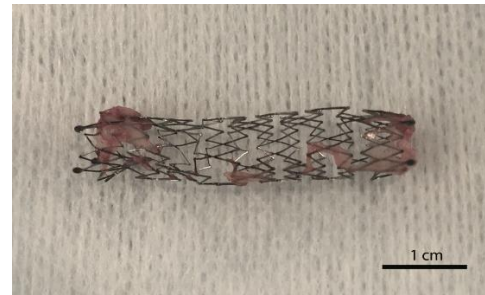


Figure 3: Nitinol stent after endovascular removal from the right interlobar pulmonary artery.

She underwent a successful deceased donor renal transplant with a left kidney notable for four arteries and complicated venous anatomy placed into her right pelvis. Her postoperative course was uncomplicated without delayed graft function. On postoperative day 2, she underwent angiography with successful stent retrieval by interventional radiology. Access was gained via the right common femoral artery and after several attempts utilizing a balloon and gooseneck snare, a secondary access point was placed in the right internal jugular vein. This allowed for successful removal of the stent without any evidence of fragmentation. No foreign objects were visualized on postoperative chest radiograph. The stent lumen was noted to have intimal in-growth (Figure 3), suggestive of intimal disruption of the right pulmonary intralobar artery. Given this, the patient was discharged on a three-month course of prophylactic enoxaparin. At one-year post-transplant, she continues to have excellent allograft function and no postoperative complications.

Discussion

There are few reports that describe stent migration to the pulmonary artery (Table 1). Like our case study, the majority of migrated stents are found incidentally on imaging and are not symptomatic at the time of diagnosis. However, five of the twenty-five reported cases presented with symptoms including dyspnea, pleuritic pain, and upper extremity edema. Two patients died secondary to complications of stent migration. One patient presented with pulmonary infarction secondary to stent migration and superior vena cava (SVC) occlusion secondary to a lung malignancy, with resultant respiratory failure that was unable to be reversed after successful SVC catheterization and stent removal [9]. The second patient presented with dyspnea and hemoptysis from a broncho-arterial fistula and died during a pneumonectomy due to uncontrollable bleeding [10].

Endovascular stent migration is a rare complication and there are not well-established guidelines for management. However, there are two general approaches to the management of stents that have migrated to the pulmonary vasculature: either conservative management with prophylactic anticoagulation or procedural intervention. The longest reported follow-up for a patient managed conservatively with prophylactic anticoagulation was four years in a patient treated with long-term Plavix. At four years the patient was asymptomatic, and a CT scan of the chest showed that the stent was stable in location and without

signs of surrounding infection [11]. Two reports have utilized long-term warfarin. At six months and nine months follow-ups neither patient experienced symptoms of pulmonary emboli, however, one patient died

of metastatic breast cancer [12, 13]. There were no bleeding complications associated with the use of either antiplatelet or anticoagulation therapy.

Table 1: Reports of vascular stent migration to the pulmonary circulation.

Surgical or Percutaneous Management						
Author	Age/Sex	Medical Hx	Original stent location	Embolization site	Management	Outcome
Saeed <i>et al.</i> [17]	54F	Budd-Chiari syndrome	IVC	Left PA	Percutaneous removal	Further follow-up and complications not specified
Grosso <i>et al.</i> [18]	66F	Diabetes mellitus	R hepatic vein and R branch of the portal vein	Left PA	Percutaneous removal	3 month follow-up, expired due to chronic renal insufficiency
Slonim <i>et al.</i> [6]	46M		SVC	Left PA	Repositioned with balloon to EIV	Further follow-up and complications not specified
<i>patient 2</i>	25M		Unspecified upper extremity	Right PA	Repositioned with balloon to EIV	
Rumi <i>et al.</i> [15]	52M	ESRD, Cirrhosis	Hepatic vein	Left PA	Percutaneous removal	7 month follow-up, no complications
Ashar <i>et al.</i> [19]	32M	Trauma, h/o repeated leg swelling	R iliac vein	Right PA and RV	Percutaneous removal	Further follow-up and complications not specified
Chiu <i>et al.</i> [14]	82F	ESRD	SVC	Right PA	Attempted percutaneous removal	1 year follow-up, no complications
Ho <i>et al.</i> [20]	61M	ESRD	L brachial-to-basilic AV loop	Left main PA	Median sternotomy, left pulmonary artery incision	Discharged on post-operative day 2, no complications
Dashkoff <i>et al.</i> [13]	33M	ESRD 2/2 IgA nephropathy	Right basilic vein	Right LL PA	Percutaneous removal	Further follow-up and complications not specified
<i>patient 2</i>	46F	ESRD 2/2 HUS	Right femoral vein	Right LL PA	Warfarin, dose/duration not specified	Further follow-up and complications not specified
Anand <i>et al.</i> [9]	56M	NSCLC	SVC	Left LL PA	Attempted percutaneous removal; ½ remained in R common femoral vein	Expired 3 days after procedure due to respiratory failure

Cabestrero <i>et al.</i> [21]	24M	Left pulmonary ostial stenosis	L pulmonary artery branch	Lobar branch distal right PA	Arteriotomy	Further follow-up and complications not specified
Plones <i>et al.</i> [10]	64F	Lung cancer, type unspecified	L bronchial branch	Left PA	Palliative pneumonectomy	Expired intraoperatively due to uncontrollable bleeding
Balasubramaniam <i>et al.</i> [22]	44F	ESRD	RLE	Right atrium, Left PA	Initial conservative management, dose/duration not specified; later not specified elective surgical removal	Further follow-up and complications not specified
Dwivedi <i>et al.</i> [23]	53F	ESRD	LUE AV Graft	Left PA	Percutaneous removal	2-year follow-up, no complications
Conservative Management						
Marcy <i>et al.</i> [12]	61F	Stage IV breast cancer	L innominate vein	Right PA	“Long-term anti-vitamin K therapy,” dose/duration not specified	9-month follow-up, expired due to metastatic breast cancer
Sharma <i>et al.</i> [24]	70M	ESRD	R subclavian vein	Right PA	No intervention	7-year follow-up, expired due to UTI-related septicemia
Linda <i>et al.</i> [25]	47F	SCLC	SVC	Left PA	No intervention	3-month follow-up, expired due to respiratory failure
Kakisis <i>et al.</i> [11]	83M	ESRD	L brachiocephalic vein	Right LL PA	Clopidogrel, dose/duration not specified	4-year follow-up, expired due to old age
Fernandez-Juarez <i>et al.</i> [26]	57M	Adult Polycystic Kidney Disease	Left radiocephalic AVF	Right Lung	No intervention	Further follow-up and complications not specified
Gabelmann <i>et al.</i> [27]						
<i>patient 1</i>	57M	Liver disease	TIPS	Right LL PA	Not specified	42 month mean follow-up among these 3 patients, no complications
<i>patient 2</i>	44M	Liver disease	TIPS	Left LL PA	Not specified	
<i>patient 3</i>	52F	Liver disease	TIPS	Right LL PA	Not specified	
Sy [28]	54F	ESRD	Unspecified peripheral AVF	Right LL PA	No intervention	4 month follow-up, symptomatic improvement

Goelitz <i>et al.</i> [16]	48M	Hepatocellular carcinoma	IVC	Right PA	No intervention	Further follow-up and complications not specified
----------------------------	-----	--------------------------	-----	----------	-----------------	---

IVC: Inferior Vena Cava; PA: Pulmonary Artery; LL: Lower Lobe; AVF: Arteriovenous Fistula; TIPS: Transjugular Intrahepatic Portosystemic Shunt; ESRD: End Stage Renal Disease; RV: Right Ventricle.

Open surgical approaches to stent retrieval exist, but percutaneous intervention is more common and less morbid in the modern era of interventional radiology. There are several reported retrieval techniques, including using a combination of balloon catheters, gooseneck snares, and nitinol snares. Two of the reported percutaneous attempts were unsuccessful, resulting in retained stent fragments in the right pulmonary artery and common femoral vein [9, 14]. There are reports of repositioning stents using balloon catheters to lower risk locations, such as the external iliac vein, without complication [6]. The appropriate timing of stent retrieval can be debated. In our case, the kidney transplant was performed prior to stent retrieval. Evaluation and retrieval require intravenous contrast and can place the renal allograft at increased risk of contrast nephropathy. Given this, it could be argued that transplantation should be postponed until percutaneous stent retrieval is performed. Alternatively, prolonged cold ischaemia time impairs graft function and should be taken into account when deciding timing of stent retrieval.

Of the twenty-five reported cases of stent migration, two are within the transplant literature, specifically in the context of an orthotopic liver transplant. In the first case, a stent that had been placed during a TIPS revision three weeks prior to transplant was found in the left pulmonary artery on routine postoperative chest x-ray [15]. The stent most likely migrated during the transplant procedure, when the native liver was mobilized and there was a dramatic rise in central venous pressure, pulmonary artery pressure, and systemic blood pressure. Intraoperatively, the patient responded to IV nitroglycerin, and on postoperative day 1, his stent was percutaneously repositioned to the right common iliac vein via a nitinol snare. Removal would have required a laparotomy because of the proximal location. Repositioning the stent was pursued as the lower risk alternative to open surgical removal. No complications were reported at seven months follow-up. In the second case report, a hepatic vein stent placed two years after liver transplant for stenosis of the suprahepatic vena cava anastomosis was incidentally found to have fragmented and migrated to the right interlobar pulmonary artery [16]. It was visualized on chest radiograph two years after stent placement when the patient was hospitalized for recurrent ascites and liver failure. Retrieval was not attempted, given the patient was asymptomatic and the risk of the fragmented stent damaging the pulmonary artery or tricuspid valve on removal. No further management or complications were specified.

While stent migration is uncommon, patients with end-stage organ failure frequently require endovascular procedures with stent placement, making them more vulnerable to this complication and its sequelae. From our review of the literature, the “watch and wait” approach and procedural intervention are both viable options for managing this rare complication. However, it is our view that this patient population is at heightened risk of hematologic complications and that if a stent can be retrieved safely, doing so will spare these patients life-long anticoagulation, reduce the risk of subsequent thromboembolic events, and eliminate yet another reason for surveillance.

Highlights

- i. Hemodialysis fistulas can stenose which can be treated with angioplasty or stenting.
- ii. Endovascular stent migration to the pulmonary artery (PA) is a rare complication.
- iii. Stent removal can be completed after transplant without injury to the graft.

Acknowledgements

None.

Conflicts of Interest

None.

Funding

None.

REFERENCES

1. Drew DA, Lok CE, Cohen JT, Wagner M, Tangri N et al. (2015) Vascular access choice in incident hemodialysis patients: a decision analysis. *J Am Soc Nephrol* 26: 183-191. [[Crossref](#)]
2. Vassalotti JA, Jennings WC, Beathard GA, Neumann M, Caponi S et al. (2012) Fistula First Breakthrough Initiative: Targeting Catheter Last in Fistula First. *Semin Dial* 25: 303-310. [[Crossref](#)]
3. Allon M, Robbin ML, Young CJ, Deierhoi MH, Goodman J et al. (2013) Preoperative Venous Intimal Hyperplasia, Postoperative Arteriovenous Fistula Stenosis, and Clinical Fistula Outcomes. *Clin J Am Soc Nephrol* 8: 1750-1755. [[Crossref](#)]
4. MacRae JM, Dipchand C, Oliver M, Moist L, Lok C et al. (2016) Arteriovenous Access Failure, Stenosis, and Thrombosis. *Can J Kidney Health Dis* 3: 2054358116669126. [[Crossref](#)]
5. Gray RJ, Dolmatch BL, Horton KM, Romolo JL, Zarate AR (1994) Migration of Palmaz Stents Following Deployment for Venous Stenoses Related to Hemodialysis Access. *J Vasc Interv Radiol* 5: 117-120.
6. Slonim SM, Dake MD, Razavi MK, Kee ST, Samuels SL et al. (1999) Management of misplaced or migrated endovascular stents. *J Vasc Interv Radiol* 10: 851-859. [[Crossref](#)]
7. Sequeira A (2016) Stent migration and bail-out strategies. *J Vasc Access* 17: 380-385. [[Crossref](#)]
8. Kupeli E, Ulubay G, Dogrul I, Birben O, Seyfettin P et al. (2015) Long-term risk of pulmonary embolism in solid-organ transplant recipients. *Exp Clin Transplant* 13: 223-227. [[Crossref](#)]
9. Anand G, Lewanski CR, Cowman SA, Jackson JE (2011) Superior vena cava stent migration into the pulmonary artery causing fatal

- pulmonary infarction. *Cardiovasc Intervent Radiol* 34: S198-S201. [[Crossref](#)]
10. Plones T, Koryllos A, Beckers F, Stoelben E (2013) Fatal migration of an endobronchial stent into the pulmonary artery. *BMJ Case Rep* 2013: bcr2013009650. [[Crossref](#)]
 11. Kakisis JD, Vassilas K, Antonopoulos C, Sfyroeras G, Moulakakis K et al. (2014) Wandering stent within the pulmonary circulation. *Ann Vasc Surg* 28: 1932.e9-1932.e12. [[Crossref](#)]
 12. Marcy PY, Magne N, Bruneton JN (2011) Strecker stent migration to the pulmonary artery: long-term result of a "wait-and-see attitude". *Eur Radiol* 11: 767-770. [[Crossref](#)]
 13. Dashkoff N, Blessios GA, Cox MR (2010) Migration of covered stents from hemodialysis A-V access to the pulmonary artery: percutaneous stent retrieval and procedural trends. *Catheter Cardiovasc Interv* 76: 595-601. [[Crossref](#)]
 14. Chiu KM, Chu SH, Chan CY (2007) Dislodged caval stent in right pulmonary artery. *Catheter Cardiovasc Interv* 70: 799-800. [[Crossref](#)]
 15. Rumi MN, Schumann R, Freeman RB, Rohrer RJ, Fairchild RB (1999) Acute transjugular intrahepatic portosystemic shunt migration into pulmonary artery during liver transplantation. *Transplantation* 67: 1492-1494. [[Crossref](#)]
 16. Goelitz BW, Darcy M (2007) Longitudinal stent fracture and migration of a stent fragment complicating treatment of hepatic vein stenosis after orthotopic liver transplantation. *Semin Intervent Radiol* 24: 333-336. [[Crossref](#)]
 17. Saeed M, Knowles HJ Jr, Brems JJ, Takiff H (1993) Percutaneous retrieval of a large Palmaz stent from the pulmonary artery. *J Vasc Interv Radiol* 4: 811-814. [[Crossref](#)]
 18. Grosso M, Spalluto F, Muratore P, Cristoferi M, Veltri A (1995) Palmaz stent dislodgement into the left pulmonary artery complicating TIPS: percutaneous retrieval and extraction after venotomy. *Cardiovasc Intervent Radiol* 18: 106-108. [[Crossref](#)]
 19. Ashar RM, Huettl EA, Halligan R (2002) Percutaneous retrieval of a Wallstent from the pulmonary artery following stent migration from the iliac vein. *J Interv Cardiol* 15: 101-106. [[Crossref](#)]
 20. Ho JM, Kahan J, Supariwala A, Silberzweig J, Kornberg R et al. (2013) Vascular stent fracture and migration to pulmonary artery during arteriovenous shunt thrombectomy. *J Vasc Access* 14: 175-179. [[Crossref](#)]
 21. Cabestrero D, Polo L, Aroca A, Sanchez Recalde A, Sartor L et al. (2011) Right pulmonary branch stent migration. *Asian Cardiovasc Thoracic Ann* 19: 177.
 22. Balasubramaniam N, Garg J, Rawat N, Chugh S, Mittal V et al. (2014) Dual stent migration to the heart and pulmonary artery. *Am J Ther* 21: e199-e203. [[Crossref](#)]
 23. Dwivedi AJ, Sharma D, Parks K (2015) Management of a misplaced endovascular stent in pulmonary artery. *Am Surg* 81: E151-E153. [[Crossref](#)]
 24. Sharma AK, Sinha S, Bakran A (2002) Migration of intra-vascular metallic stent into pulmonary artery. *Nephrol Dial Transplant* 17: 511. [[Crossref](#)]
 25. Linda S, Augustin P, Anne Claire T, Frederic T, Denis MS (2013) Unusual migration of a vena cava stent into the pulmonary artery because of tumor reduction after chemotherapy. *J Thorac Oncol* 8: 1585-1586. [[Crossref](#)]
 26. Fernandez Juarez G, Letosa RM, Mirete JO (1999) Pulmonary migration of a vascular stent. *Nephrol Dial Transplant* 14: 250-251. [[Crossref](#)]
 27. Gabelmann A, Kramer SC, Tomczak R, Gorich J (2001) Percutaneous techniques for managing maldeployed or migrated stents. *J Endovasc Ther* 8: 291-302. [[Crossref](#)]
 28. Sy A (2006) Pulmonary infarction due to vascular stent migration. *South Med J* 99: 1003-1004. [[Crossref](#)]