

Available online at www.sciencerepository.org

Science Repository



Case Report

Guidelines for the Discovery of an Intracardiac Foreign Body Through a Case of Metal Tip Migration to the Right Ventricle after Tibia Osteosynthesis

Yoon DJY¹, Odri GA², Bisson A³, Rosset Ph¹, Le Nail LR¹, Legras A^{4*} and Berhouet J¹

¹Department of Orthopedic Surgery, Centre hospitalier régional universitaire de Tours, Hôpital Trousseau, Chambray-lès-Tours, France

²Department of Orthopedic Surgery, Centre hospitalier régional universitaire Lariboisière, Paris, France

³Department of Cardiology, Centre hospitalier régional universitaire de Tours, Hôpital Trousseau, Chambray-lès-Tours, France

⁴Department of Thoracic and Cardio-vascular Surgery, Centre hospitalier régional universitaire de Tours, Tours, France

ARTICLE INFO

Article history:

Received: 17 April, 2020

Accepted: 4 May, 2020

Published: 12 May, 2020

Keywords:

Metallic foreign body

intracardiac migration

tibia osteosynthesis

lower limb fracture

metal tip in right ventricle

ABSTRACT

Case: We report a case of a metallic foreign body migration from the lower limb to the right ventricle. A metal tip of 5x3mm was discovered during a cardiac investigation for a ventricular extrasystole. A few months earlier, the patient had a tibia osteosynthesis for fracture.

Conclusion: We propose guidelines in case of a cardiac foreign body detection. A conservative treatment or surgical removal can be discussed depending on the clinical features, the anatomical situation and the shape of the foreign body.

© 2020 Association Thorax à Tours. Hosting by Science Repository.

Introduction

The use of metallic materials is essential in orthopedic surgery, as most of implants and tools are metallic. In traumatic situation, osteosynthesis requires metallic foreign bodies for internal or external fixation such as screws, nails, Kirschner wires, etc. One of the complications of Kirschner wires is the migration, described over one hundred times since 1943 [1, 2]. Usually, when an orthopedic material migrate, it stays near its anatomical site, such as shoulder materials moving to the chest [1, 3, 4]. In this article, we reported a case of a metal tip migration from the lower limb to the right ventricle, after a traumatic tibial fracture. The patient was informed that data concerning this case would be submitted for publication and fully agreed. By reporting similar cases described in the literature, we proposed guidelines in such situations.

Case Report

A 70-year-old man came for a consultation in our hospital at day 14 after a lower limb surgery. He had no previous history of surgery, coronary

angiography, venous or arterial catheter, or ballistic trauma, and he didn't report any accidental impact of a metallic foreign body. Fourteen days earlier, he had a tibial pilon fracture while skiing, and was operated in the nearest hospital. His fracture was fixed with a pilon locking compression plate and screws (Figures 1A & 1B). A cutaneous non-union was observed, and at day 21, the hardware was exposed. All the hardware was removed and an appropriate antibiotherapy was introduced. His lower limb was then immobilized in a posterior short leg splint for 2 months and no secondary displacement was observed. Six months later, his leg had normal function and he went back to sports (Figures 1C & 1D).

A few months later, during a regular cardiac check-up, a ventricular extrasystole was discovered and the patient underwent an exercise stress test, a coronary angiography and a heart MRI. These tests revealed a 5x3 mm metallic foreign body, at the inferoapical wall of the right ventricle. The cardiac outcome was nevertheless positive (Figure 2). After two years of follow-up, the metal tip is still firmly fixed to the right ventricle, without any migration. His cardiac function is stable.

*Correspondence to: Antoine Legras, M.D., Ph.D., Department of Thoracic and Cardio-vascular Surgery, Centre hospitalier régional universitaire de Tours, Tours, France; Fax: 33247474686; Tel: 33247474636; E-mail: antoine.legras@chu-tours.fr

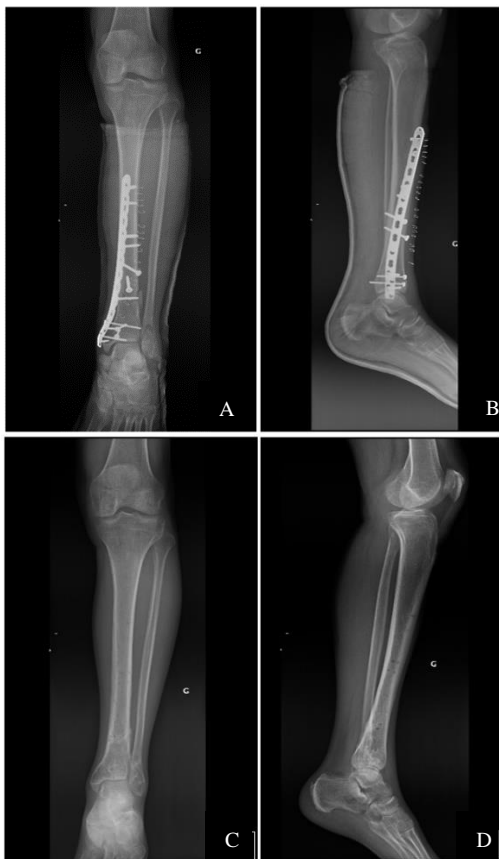

Figure 1: A, B) Leg X-rays at day 21 of the leg fracture with osteosynthesis material; and C, D) X-rays at 8 months after material removal.

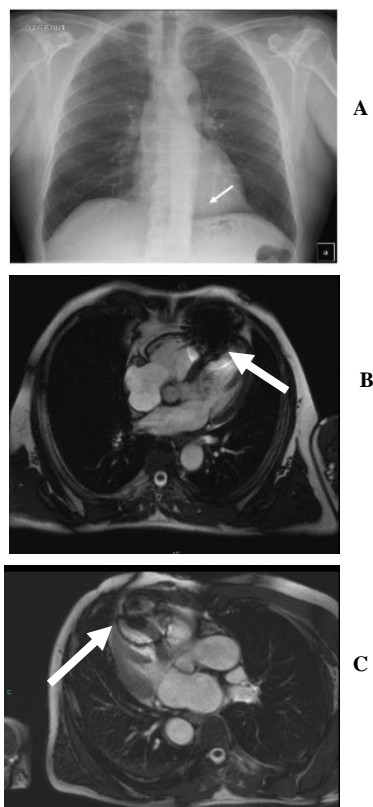


Figure 2: A) Thoracic x-ray, B, C) MRI and D, E) CT-scan images at 5 months after material removal: the metal tip was found in the right ventricle (white arrow).

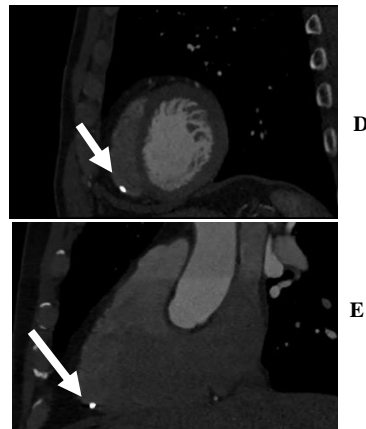


Figure 2: A) Thoracic x-ray, B, C) MRI and D, E) CT-scan images at 5 months after material removal: the metal tip was found in the right ventricle (white arrow).

Discussion

The cardiac migration of foreign bodies is a rare but dangerous complication. In orthopedics, it has been described in many circumstances. The most frequent situations are shoulder or sternoclavicular surgeries in which many Kirschner’s wires cardiac migrations have been reported [2, 3, 5-10]. Some migrations from other anatomical sites have been reported after orthopedic surgery: hip, patella, hand and wrist [11-18]. Our case might be the first to report a migration from a leg. Our patient had no previous medical and surgical history. He didn’t have any accident involving metallic splinters. Besides, he had no scar on his entire body that could have suggested an inlet of a foreign body. Two cases of metal tips cardiac migration from traumatic transcuteaneous entry have been described; these tips were found in the heart a few days later [19, 20].

Migration of foreign bodies directly introduced in the vascular system have been described [21]. In such cases, it can easily be brought to the heart by venous blood circulation. For orthopedic hardware, after osteosynthesis, the mechanism remains unclear. The foreign bodies were found in the right heart in most cases; this arrival site may suggest the implication of venous circulation in the migration mechanism. Some of them were found in the pulmonary artery, the aorta or the lungs [21-23]. The delay of the migration is variable, from one day to 24 years. The diagnosis was based on the successive X-rays of the operated site and a thoracic image such as an X-ray, CT-scan or MRI. In order to prevent such migration, it is recommended to realize a reliable osteosynthesis. If Kirschner wires or cables are used, its ends should be bent. If a fragment falls from the hardware or from a tool, it must be removed immediately. Once the fracture is strong enough, temporary materials should be removed, especially from shoulders.

On the follow up X-rays, if a migration from the initial surgery site is observed, a chest X-ray can be realized, as migrations to the thoracic sites can be fatal. The most frequent complications were tamponade, arrhythmia and even death [2, 3, 5, 6, 8-10, 13, 14]. Some patients complained about pain, but most of them had no symptom [18, 20]. In the case of a foreign body migration to the heart, several treatments have been proposed. If the patient had no physical complain, a clinical and

radiological follow-up was proposed [5, 6, 9, 19, 20]. However, if symptoms were observed or if the foreign body was directly threatening the cardiovascular integrity, a surgical removal was performed. Surgical removals consisted of a thoracotomy or sternotomy, with or without cardiopulmonary bypass [2, 3, 10, 12-14, 17]. Thus, we think that a

frequent follow-up should be done if the foreign body is small, not mobile, not threatening cardiovascular structures and asymptomatic. Any other situation must consider a surgical removal. Each case must be discussed with a cardiothoracic surgeon (Figure 3).

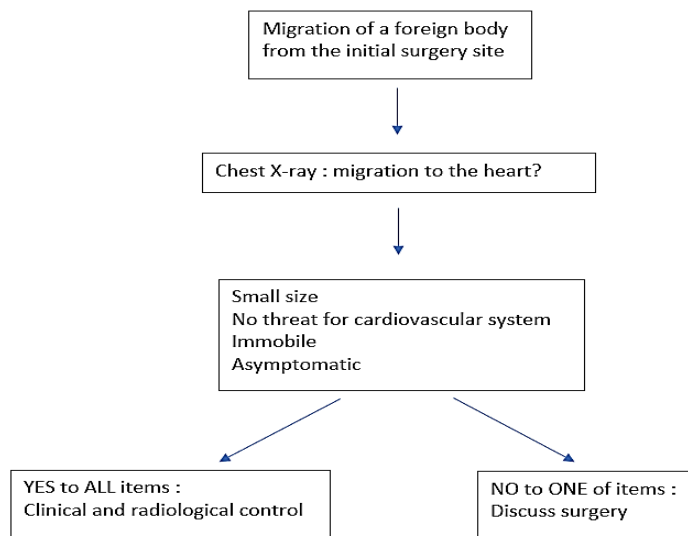


Figure 3: Decision tree in case of a foreign body migration to the heart.

Conclusion

We reported a rare case of a metal tip migration after a traumatic orthopedic surgery for a leg fracture. When this rare complication is observed, a clinical and radiological follow-up can be proposed only if the foreign body is small, immobile, far from important structures and asymptomatic. If any threatening situation is suspected, a surgical removal must be discussed with cardiothoracic surgeons.

Conflicts of Interest

None.

Ethical Approval

All procedures performed in this case report were in accordance with the ethical standards of the institutional and national research committee and with the 1964 Helsinki declaration and its later amendments or comparable ethical standards.

Consent

Informed consent was obtained from the patient of the reported case.

REFERENCES

- Mazet RJ (1943) Migration Of a Kirschner Wire from the Shoulder Region into the Lung : Report of Two Cases. *J Bone Joint Surg* 25: 477-483.
- Tan L, Sun DH, Yu T, Wang L, Zhu D et al. (2016) Death Due to Intra-aortic Migration of Kirschner Wire From the Clavicle: A Case Report

- and Review of the Literature. *Medicine (Baltimore)* 95: e3741. [Crossref]
- Medved I, Simic O, Bralic M, Stemberga V, Kovacevic M et al. (2006) Chronic heart perforation with 13.5 cm long Kirschner wire without pericardial tamponade: an unusual sequelae after shoulder fracture. *Ann Thorac Surg* 81: 1895-1897. [Crossref]
- Lyons FA, Rockwood CA Jr (1990) Migration of pins used in operations on the shoulder. *J Bone Joint Surg Am* 72: 1262-1267. [Crossref]
- Nettles JL, Linscheid RL (1968) Sternoclavicular dislocations. *J Trauma* 8: 158-164. [Crossref]
- Salvatore JE (1968) Sternoclavicular joint dislocation. *Clin Ortho Related Res* 58: 51-55. [Crossref]
- Fowler AW (1981) Migration of a wire from the sternoclavicular joint to the pericardial cavity. *Injury* 13: 261-262. [Crossref]
- Tubtax H, Hendzel P, Sergeant P (1989) Cardiac perforation after Kirschner wire migration. *Acta Chir Belg* 89: 309-311. [Crossref]
- Freund E, Nachman R, Gips H, Hiss J (2007) Migration of a Kirschner wire used in the fixation of a subcapital humeral fracture, causing cardiac tamponade: case report and review of literature. *Am J Forensic Med Pathol* 28: 155-156. [Crossref]
- Hedon C, Khoueiry Z, Verges M, Pasquié JL (2015) Late intracardiac orthopedic wire migration presenting as tamponade and stroke. *Eur Heart J* 36: 1546. [Crossref]
- McCardel BR, Dahners LE, Renner JB (1989) Kirschner wire migration from the pelvis to the heart and a new method of fixation of articular fracture fragments, acetabular reconstruction. *J Orthop Trauma* 3: 257-259. [Crossref]
- Anic D, Brida V, Jelic I, Orlic D (1997) The cardiac migration of a Kirschner wire. A case report. *Tex Heart Inst J* 24: 359-361. [Crossref]

13. Haapaniemi TA, Hermansson US (1997) Cardiac arrhythmia caused by a Kirschner wire inside the heart. An unusual complication of finger osteosynthesis. *J Hand Surg Br* 22: 402-404. [[Crossref](#)]
14. Goodsett JR, Pahl AC, Glaspy JN, Schapira MM (1999) Kirschner wire embolization to the heart: an unusual cause of pericardial tamponade. *Chest* 115: 291-293. [[Crossref](#)]
15. Seipel RC, Schmeling GJ, Daley RA (2001) Migration of a K-wire from the distal radius to the heart. *Am J Orthop (Belle Mead NJ)* 30: 147-151. [[Crossref](#)]
16. Biddau F, Fioriti M, Benelli G (2006) Migration of a broken cerclage wire from the patella into the heart. A case report. *J Bone Joint Surg Am* 88: 2057-2059. [[Crossref](#)]
17. Park SY, Kang JW, Yang DH, Lim TH (2011) Intracardiac migration of a Kirschner wire: case report and literature review. *Int J Cardiovasc Imaging* 27: 85-88. [[Crossref](#)]
18. Leonardi F, Rivera F (2014) Intravascular migration of a broken cerclage wire into the left heart. *Orthopedics* 37: e932-e935. [[Crossref](#)]
19. Gschwind CR (2002) The intravenous foreign body: a report of 2 cases. *J Hand Surg Am* 27: 350-354. [[Crossref](#)]
20. Marcello P, Garcia-Bordes L, Mendez Lopez JM (2009) Peripheral venous embolized intracardiac foreign body. *Interact Cardiovasc Thorac Surg* 9: 1043-1044. [[Crossref](#)]
21. Actis Dato GM, Arslanian A, Di Marzio P, Filosso PL, Ruffini E (2003) Posttraumatic and iatrogenic foreign bodies in the heart: report of fourteen cases and review of the literature. *J Thorac Cardiovasc Surg* 126: 408-414. [[Crossref](#)]
22. Combalia-Aleu A, Garcia S (1994) Pulmonary artery perforation after Kirschner wire migration: case report and review of literature. *J Trauma* 37: 514-515. [[Crossref](#)]
23. Reghine EL, Cirino CCI, Neto AA, Varallo FR, Évora PRB (2018) Clavicle Kirschner Wire Migration into Left Lung: A Case Report. *Am J Case Rep* 19: 325-328. [[Crossref](#)]