

Available online at www.sciencerepository.org

Science Repository



Case Report

3D Printing Aided Elbow Deformity Correction

Abhishek Vaish^{1*}, Raju Vaishya², Lalit Maini³ and Aamir Johar⁴

¹Consultant, Indraprastha Apollo Hospital, New Delhi, India

²Senior Consultant, Indraprastha Apollo Hospital, New Delhi, India

³Senior Consultant, Orthopaedics, Maulana Azad Medical College, New Delhi, India

⁴Clinical Fellow, Orthopaedics, Indraprastha Apollo Hospital, New Delhi, India

ARTICLE INFO

Article history:

Received: 23 April, 2020

Accepted: 5 May, 2020

Published: 12 May, 2020

Keywords:

Elbow

cubitus valgus

3D printing

deformity

non union

ABSTRACT

Introduction: Fracture of lateral condyle of humerus is known for nonunion, if not treated properly in children, often leads to a cubitus valgus deformity. For the late presenting cases with deformity and restricted range of motion, surgical management is often challenging, and an appropriate preoperative planning is required.

Case Report: We report a case of an un-united fracture of the lateral condyle of the humerus in an adult with a cubitus valgus deformity with early tardy ulnar nerve palsy. He was treated by corrective osteotomy with bone grafting of the nonunion and internal fixation with contoured plates. A virtual preoperative surgical planning was done using 3D printing to define the exact location and direction of the osteotomy, plate contouring and likely place of screw placement to achieve full correction of the elbow deformity.

Results: There was good correction of deformity, with union of the nonunion and osteotomy, at three months follows-up. At one year, there was complete recovery of ulnar nerve palsy with excellent function of the elbow and hand.

Conclusion: 3D printing is effective in treating complex orthopedic cases and deformity correction. Virtual preoperative surgical planning on the computer and on a 3D model help to study the exact site of osteotomy, plate contouring and screw placement to achieve accurate correction of the deformity. Virtual preoperative planning and 3D printing help in reducing the surgical time and help to achieve desired correction of the deformity.

© 2020 Abhishek Vaish. Hosting by Science Repository.

Introduction

Fracture of lateral condyle of humerus is known for non-union, if not treated properly in children, often leads to a cubitus valgus deformity [1]. For the late presenting cases, with deformity and restricted range of motion, surgical management is often challenging, and an appropriate preoperative planning is required. Various methods of treatment have been described from open reduction and internal fixation with bone grafting, several types of osteotomy of the distal humerus (varus osteotomy, dome osteotomy or Milch's open wedge displacement osteotomy), with or without ulnar nerve transposition depending on ulnar nerve involvement. A careful planning of osteotomy is required for

the correction of deformity with regards to its site, type of osteotomy and fixation method.

We report a case of an un-united fracture of the lateral condyle of the humerus in an adult with a cubitus valgus deformity with early tardy ulnar nerve palsy. He was treated by corrective osteotomy with bone grafting of the nonunion and internal fixation with contoured plates. A virtual preoperative surgical planning was done using 3D printing to define the exact location and direction of the osteotomy, plate contouring and likely place of screw placement to achieve full correction of the elbow deformity.

*Correspondence to: Dr. Abhishek Vaish, Consultant, Department of Orthopaedics and Joint Replacement Surgery, Indraprastha Apollo Hospitals, Sarita Vihar, Mathura Road, Delhi 110076, New Delhi, India; Tel: 919717590242; E-mail: drabhishekvaish@gmail.com

Case Report

A 25 years old male presented with severe cubitus valgus (20 degrees) and flexion deformity (30 degrees) of the left elbow with the features of progressive ulnar neuropraxia. This deformity was associated with mild pain. There was decreased range of motion of 30 -90 degrees for the past six years. He had history of childhood trauma to the left elbow where which was treated conservatively by posterior slab and immobilization for four weeks; later he developed deformity of the elbow which was progressive till the age of 20 years. Subsequently, he developed pain with decreased range of motion. On examination, the patient had increased carrying angle of 20 degrees (compared to the right elbow) with valgus deformity and a prominent medial epicondyle (Figure 1). The three-point bony relationship was disturbed with proximal migration of lateral epicondyle. Mild wasting of arm and forearm muscles was noted. There were early signs of ulnar neuropathy.

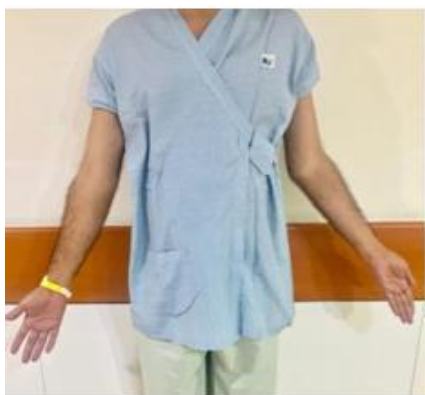

Figure 1: Preoperative photograph showing cubitus valgus deformity of the left elbow.

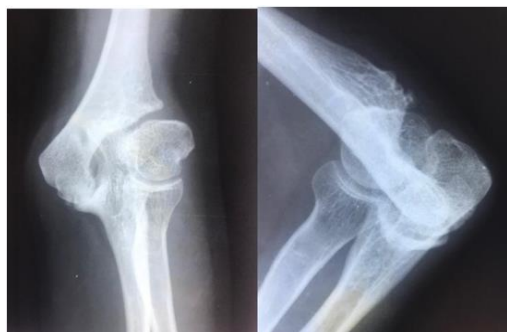

Figure 2: Preoperative radiograph (AP and Lateral views), revealing nonunion of the lateral condyle of humerus with deformity of the distal humerus.

Plain radiographs of the left elbow confirmed the presence of valgus deformity with a non-union of lateral condyle of the humerus (Figure 2). A computed Tomography (CT) scan was performed for better assessment of the anatomy and also to obtain DICOM (Digital Imaging and Communications in Medicine) images for virtual pre-operative planning and making a plastic mode (Figure 3), using 3-D printing technology. The DICOM images of the CT scan were converted into STL (stereolithography) files using the Mimics™ (Materialise, Germany) software. A virtual 3D image of the elbow joint was then reconstructed. Deformity correction was done on this virtual elbow model on a computer, by using Blender software (Dutch). Various

degrees bone wedges and several types of osteotomy were performed, until a reasonably good correction was achieved. The decision of performing Milch's oblique osteotomy was taken, to correct the deformity. The choice of corrective osteotomy and angle of osteotomy was determined by keeping the opposite side as reference. Further, the positioning of the plate for optimal placement and adequate placement of the screw was planned by performing the osteotomy on the 3D printed model and applying the plate and screw on the model (Figure 4) beforehand to determine its stability and the amount of correction achieved.

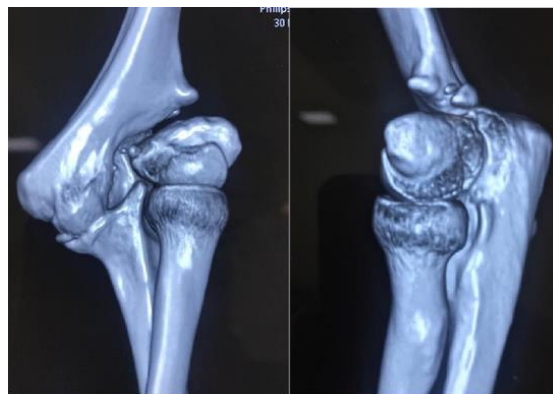


Figure 3: 3D reconstructed images of computed tomography (CT) scan confirming the presence of nonunion of the lateral humeral condyle and deformity of the distal humerus.

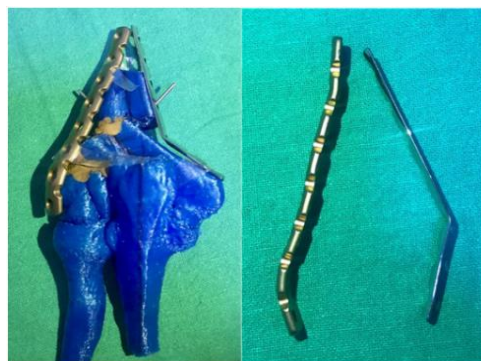

Figure 4: Preoperative planning done on a 3D printed model of the elbow. The osteotomy done to correct the deformity and contouring of the plates done to fix the osteotomy.

The surgery of open reduction and bone grafting of the non-union, corrective distal humeral osteotomy and fixation using precontoured plates was done through the posterior approach, under pneumatic tourniquet. The total tourniquet time taken was 45 minutes. No change from the preoperative surgical planning in the surgical execution of the osteotomy and fixation of the precontoured plates was required. We need not to do anterior transposition of the ulnar nerve as after the deformity correction the stretch on the nerve was relieved fully.

Results and Follow Up

There was good correction of deformity (Figure 5) with union of the nonunion and osteotomy, at three months follow-up (Figure 6). At one year, there was complete recovery of ulnar nerve palsy with excellent function of the elbow and hand.



Figure 5: Postoperative photograph showing good correction of the deformity of the left elbow.

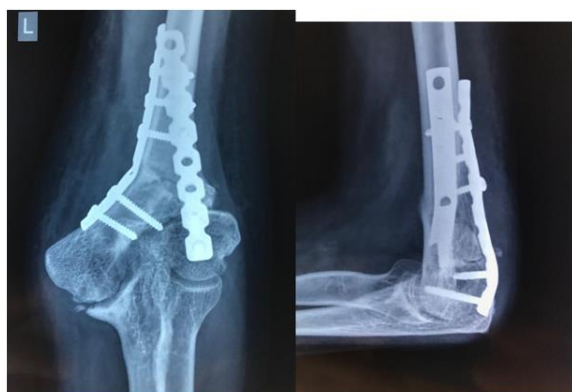

Figure 6: Postoperative follow up radiographs confirming the union of the ununited lateral humeral condyle and the osteotomy.

Discussion

The significance of lateral condyle fractures in children was realized by Milch, as these fractures are associated with several complications, if not treated well. In lateral condyle fractures, the displacement is usually greater than is perceived or appreciated, and often an incongruity of the articular surface is present [1]. The management of late presenting fractures is challenging, and fraught with complications. For these reasons, an accurate reduction of these fractures should be performed within the first 48 hours after the fracture. Various difficulties related to the treatment of these fracture include lateral spur formation with pseudo or true cubitus varus, nonunion, malunion, valgus angulation, avascular necrosis (AVN), or a combination of these conditions [2]. There is no surgical gold standard for the correction of elbow deformities.

Many types of osteotomies have been proposed but these have limitations like incomplete deformity correction, poor internal fixation, residual protrusion of the epicondyle, intraoperative technical difficulties, long term immobilization, risk of neurovascular injuries. Masad *et al.* concluded that for patients with cubitus valgus with ulnar neuropathy, treatment in the form of osteosynthesis, osteotomy, and ulnar nerve transposition was helpful [3]. Many authors have described the ideal approaches in such cases, for instance Tien *et al.* (2005) concluded that with better exposure of the lateral condylar nonunion through a posterior approach, they could effectively stabilize the lateral

condylar nonunion and avoid postoperative loss of motion and osteonecrosis of the condyle. With a dome-shaped supracondylar osteotomy, they could correct the cubitus valgus deformity and avoid the development of a medial epicondylar prominence [4]. Kim *et al.* showed that step-cut translation osteotomy, with a wedge-shaped osteotomized surface, fixed with a Y-shaped humeral plate is a relatively simple procedure resulting in very firm fixation that allows early movement of the joint with good clinical results [5].

Another study by Bub *et al.* concluded that supracondylar closed wedge osteotomy stabilized by a locking plate had far superior results than other techniques and was less invasive [6]. The type of osteotomy may vary from case to case and needs to patient specific. It can be easily decided by the preoperative virtual planning using 3D printing [7]. The 3D printing technology offered several advantages in our case viz., exact location and direction of osteotomy was known which allowed us to correct the deformity fully, the precontoured plates fitted accurately and provided a stable fixation, the surgical time was less, intraoperative ease of doing such a complex case and the desired outcome of the surgery mimicking the preoperative planning [8, 9].

3D printing has proved to be beneficial in preoperative planning, patient education, case-specific custom manufacturing (casts, braces, implants, prosthetics) and its emerging potential for bio-printing of real tissue which can be directly used instead of artificial implants [8]. A major advantage of 3D printing is its ease of access, customization according to need, ability to create complex shapes both solid and porous or a combined structure as per requirement and low cost. It also reduces the operative time and chances of complications in such complex deformity correction. The use of 3D printing, for deformity correction has not been fully explored until now and there are only few publications available on it in the literature [8].

Conclusion

3D printing is effective in treating complex Orthopaedic cases and deformity correction. Virtual preoperative surgical planning on the computer and on a 3D model help to study the exact site of osteotomy, plate contouring and screw placement to achieve accurate correction of the deformity. It also reduced the operative time and provided desired correction of the deformity. The patient in this case report showed excellent functional outcomes at one year.

Acknowledgment

We are extremely thankful to Dr. Sonu Singh of Salubris Publishers, who has given us the permission to use the some of the figures of our book entitled "An update on Medical 3D printing".

Conflicts of Interest

None.

Funding

None.

Ethical Approval

This article does not contain any studies with human participants or animals performed by any of the authors.

Informed Consent

Informed consent was obtained from all individual participants included in the study.

REFERENCES

1. Milch H (1964) Fractures and fracture dislocations of the humeral condyles. *J Trauma* 4: 592-607. [[Crossref](#)]
2. Ranjan R, Sinha A, Asif N, Ifithekar S, Kumar A et al. (2018) Management of Neglected Lateral Condyle Fracture of Humerus: A Comparison between Two Modalities of Fixation. *Indian J Orthop* 52: 423-429. [[Crossref](#)]
3. Masad K, Kawai H, Kawabata H, Masatomi T, Tsuyuguchi Y et al. (1990) Osteosynthesis for old, established non-union of the lateral condyle of the humerus. *J Bone Joint Surg Am* 72: 32-40. [[Crossref](#)]
4. Tien YC, Chen JC, Fu YC, Chih TT, Hunag PJ et al. (2005) Supracondylar dome osteotomy for cubitus valgus deformity associated with a lateral condylar nonunion in children. *J Bone Joint Surg Am* 87: 1456-1463. [[Crossref](#)]
5. Kim HT, Lee JS, Yoo CI (2005) Management of cubitus varus and valgus. *J Bone Joint Surg Am* 87: 771-780. [[Crossref](#)]
6. Buß FR, Schulz AP, Lill H, Voigt C (2011) Supracondylar osteotomies of posttraumatic distal humeral deformities in young adults - technique and results. *Open Orthop J* 5: 389-394. [[Crossref](#)]
7. Mishra A, Verma T, Vaish A, Vaish R, Vaishya R et al. (2019) Virtual preoperative planning and 3D printing are valuable for the management of complex orthopaedic trauma. *Chin J Traumatol* 22: 350-355. [[Crossref](#)]
8. Vaish A, Rabari Y, Vaish R, Vaishya R (2020) Correction of a severe flexion knee deformity using 3D printing. *Ind J Orthop* 54(2): 228-229.
9. Vaish A, Vaish R (2018) 3D printing and its applications in Orthopedics. *J Clin Orthop Trauma* 9: S74-S75. [[Crossref](#)]