

Available online at www.sciencerepository.org

Science Repository



Case Report

Sarcomatoid Carcinoma of the Urinary Bladder: A Case Report

Qiliang Yin¹, Yanping Zhong², Yan Wang³, Shijie Lan¹, Di Wu^{1*} and Haofan Jin^{1*}

¹Tumor Center of JiLin University No.1 Hospital, Changchun, China

²Pathology Department of JiLin University No.1 Hospital, Changchun, China

³Urinary Surgery Department of JiLin University No.1 Hospital, Changchun, China

ARTICLE INFO

Article history:

Received: 27 March, 2020

Accepted: 15 April, 2020

Published: 8 May, 2020

Keywords:

Sarcomatoid carcinoma

bladder carcinoma

immunohistochemistry

radical cystectomy

chemotherapy

ABSTRACT

Introduction: Sarcomatoid carcinoma describes a biphasic malignancy with features of epithelial and mesenchymal differentiation. It rarely occurs at the urinary bladder but is usually aggressive and associated with poor prognosis.

Case Presentation: We here report a case of sarcomatoid carcinoma of the urinary bladder of a 48 years old man with intermittent painless haematuria over an 18-month period. Imaging examination showed intraluminal protrusion of a tumour on the right posterior wall of the bladder.

Diagnosis: The patient was initially diagnosed as a right bladder mass.

Interventions: The patient underwent two rounds of transurethral resection of bladder tumour (TURBT) and pathological analysis suggested the tumours were invasive urothelial carcinomas. Radical cystectomy was later performed, and pathological analysis suggested a stage T4 sarcomatoid carcinoma. The patient received 5 cycles of gemcitabine and cisplatin.

Outcome: The patient died of multiple organ dysfunction syndrome 8.5 months after the diagnosis of sarcomatoid carcinoma.

Conclusion: Sarcomatoid carcinoma of the urinary bladder is a highly malignant disease, and the histopathological characteristics are distinct. The diagnosis, surgical management, and chemotherapy of this patient are discussed together with previous cases reported in the literature.

© 2020 Di Wu, Haofan Jin. Hosting by Science Repository.

Introduction

Sarcomatoid carcinoma represents an aggressive histotype of malignancies that occur at many anatomic sites such as upper respiratory and digestive tracts, kidney, and lung. It rarely occurs in the urinary bladder, accounting for 0.31% of the bladder cancer, and less than 100 cases have been reported in the literature until now [1, 2]. Sarcomatoid carcinoma of the urinary bladder (SCUB) usually occurs in elderly patients aging around 70. The patients usually present with painless visible haematuria, sometimes with frequent urination, and acute urinary retention [1, 3, 4]. Diagnosis of SCUB relies on postsurgical pathological analysis, particularly the morphological and immunohistochemical evidence of epithelial and mesenchymal differentiation [1, 5]. Patients

are often treated by radical cystectomy followed by adjuvant chemotherapy or radiotherapy. The prognosis is generally poor, with an overall median survival of 14 months [3].

Case History

A 48-year-old man presented in September 2013 with intermittent painless haematuria over an 18-month period. Pelvic computed tomography (CT) confirmed a 2.6 × 1.6 intraluminal soft tissue protrusion on the right posterior wall of the bladder. Transurethral resection of bladder tumour (TURBT) was performed and pathological analysis of the tumour demonstrated features of invasive urothelial carcinoma with extensive necrosis. Haematuria recurred in December

*Correspondence to: Di Wu, Tumor Centre of the First Affiliated Hospital of Jilin University, 1 Xin-Min Street, Changchun, 130021, China; E-mail: wudi888991@163.com

Haofan Jin, Tumor Centre of the First Affiliated Hospital of Jilin University, 1 Xin-Min Street, Changchun, 130021, China; E-mail: kinhf1968@126.com

© 2020 Di Wu, Haofan Jin. This is an open-access article distributed under the terms of the Creative Commons Attribution License, which permits unrestricted use, distribution, and reproduction in any medium, provided the original author and source are credited. Hosting by Science Repository.

<http://dx.doi.org/10.31487/j.JSO.2020.02.05>

2013, and CT suggested poor bladder filling, thickening of the right posterior wall with irregular soft tissue density and rough outer wall. A cystectomy was performed, and post-surgery pathological analysis suggested a T4-stage SCUB with extensive necrosis. The tumour was positive for CKs, CK7, and vimentin, but weakly positive for 34 β E12. Metastases to lung (Figure 1A), pleura (Figure 1B), and peritoneum

(Figure 1C) were observed 1 month after the cystectomy. The patient received 5 cycles of gemcitabine (1,000 mg/m², D1, D8) and cisplatin (70 mg/m², D1-D3) from January to May 2014, and disease stabilized. Re-examination in June 2014 suggested disease progression but the patient refused further treatment and died of multiple organ failure in August 2014.

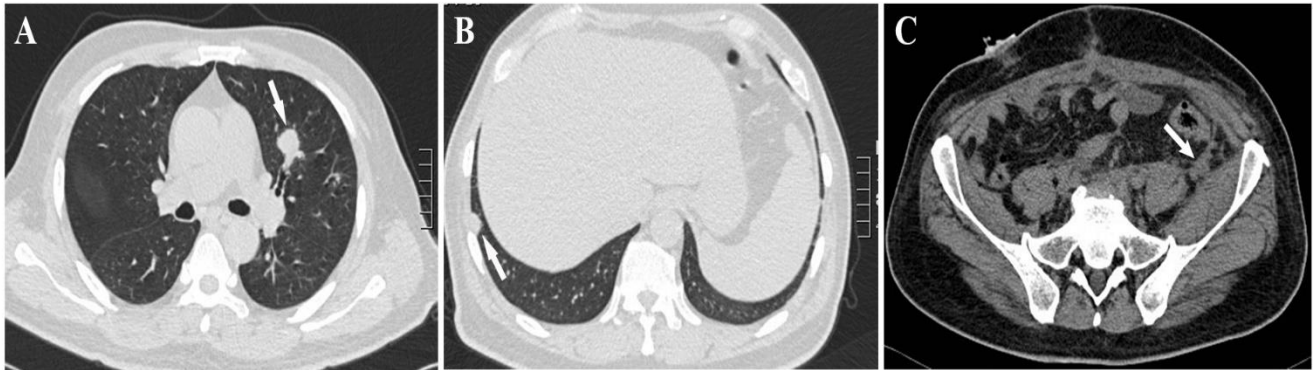


Figure 1: A lung CT showed metastases of SCUB to **A)** lung and **B)** pleura, and **C)** a whole abdominal CT detected metastasis to the peritoneum.

Discussion

SCUBs often occur on the bladder wall as papilloma, polypoid tumours, or nodules with intraluminal protrusion [1, 4, 5]. Surface ulceration and bleeding are common, and invasion can be as deep as into bladder muscle and surrounding soft tissue [1, 4]. Like typical SCUBs, it had both carcinomatous and, predominantly, sarcomatous elements (Figures 2A & 2B), consistent with the previously described >50% ratio of

sarcomatous tissues in SCUB [4]. The sarcomatous cells arranged into a solid sheet structure, consisting mainly of polygonal epithelial-like fat spindle cells (Figure 2A), with abundant eosinophilic cytoplasm. The tumour was mitotically active, showing >10 mitoses per 10 high power fields, and apparently necrotic. Tumour invasions into the nerves and the adipose tissue around the bladder were found (Figure 2B), and cancer embolus observed in the vessels.

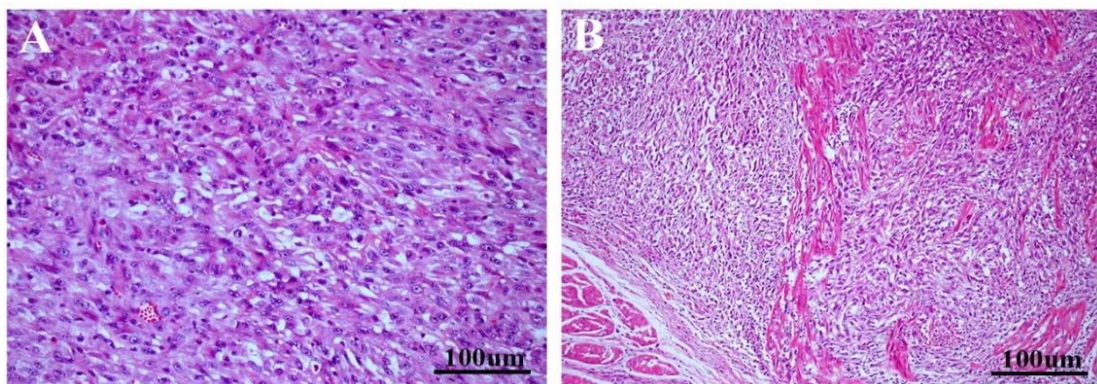


Figure 2: Hematoxylin and eosin staining of the tumour showed **A)** solid-sheet arrangement of the malignant cells and **B)** myometrial invasion.

Immunohistochemistry (IHC) is highly valuable for the diagnosis of SCUB, particularly when the representativeness of biopsies is questionable, or the tumours are dominated by sarcomatous elements like the current case, although no specific IHC marker for SCUBs has been identified. Both sarcomatous and carcinomatous elements are usually positive for keratins, epithelial membrane antigen (EMA), and mesenchymal marker vimentin, although the staining pattern may vary [5]. Consistent with the above IHC characteristics, the tumour in the current case expressed CKs (Figure 3A) and CK7 (Figure 3B) and was strongly positive for vimentin (Figure 3C) but partially positive for 34 β E12 (Figure 3D).

These features, together with the histological evidence, led to the diagnosis of SCUB of this case. Advanced staging is the major independent risk factor associated with the prognosis; therefore, early diagnosis is critical for the clinical outcome [1, 3, 5]. Previous reports suggested misdiagnosis of SCUB as transitional cell carcinoma after TURBT; likewise, this case was diagnosed as urothelial carcinoma [6]. Therefore, comprehensive histological analysis, by multiple biopsies of the tumour tissue and separate biopsies of suspicious mucosa at the tumour bases and margins, is required to improve the accuracy of diagnosis. Differentiation of SCUBs from other types of cancer relies on histopathological and IHC analysis. Carcinosarcoma lacks IHC evidence of epithelial differentiation, although it has both carcinomatous and sarcomatous components [4, 5].

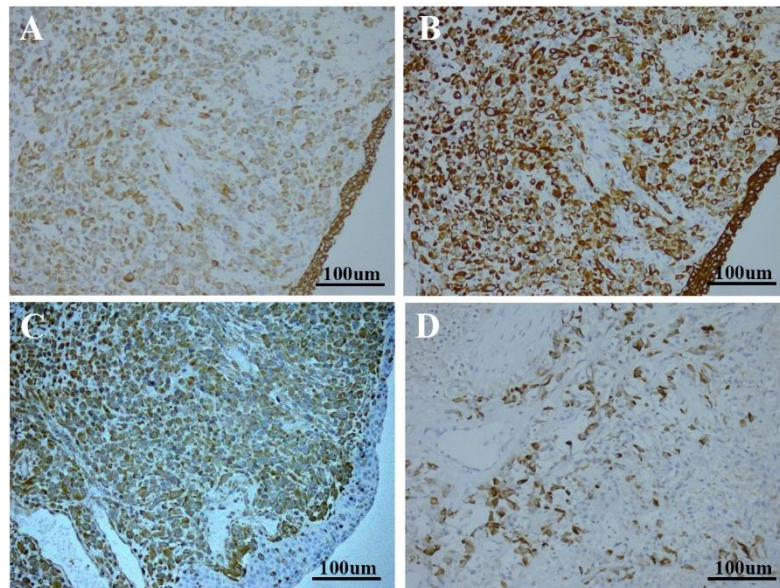


Figure 3: The tumour cells were immunoreactive for **A)** CKs, **B)** CK7, **C)** vimentin, and **D)** weakly positive for 34βE12.

However, due to the aggressive nature, risk factors, clinical features, and poor prognosis it shares with SCUB, World Health Organization has grouped them together as SCUBs [2, 5]. Sarcoma usually does not express epithelial markers and exhibits no intercellular bridges and tonofilaments under the electron microscope, which were observed for SCUBs [1]. Strong expressions of p63, high molecular weight CKs 34βE12 and CK5/6, or CK20 support diagnosis of SCUBs, and help exclude inflammatory myofibroblastic tumors and other soft tissue tumours, which may focally and weakly express CKs [7].

Currently, there is no commonly accepted approach to treat SCUBs. A review of 221 cases found no significant difference in the patient outcomes between different approaches, and other studies using smaller cohorts of patients led to similar conclusions [1, 3-6, 8]. However, TURBT followed by chemotherapies may prolong the long-term survival of the early-stage SCUB patients. Radical cystectomy may not be appropriate for the advanced-stage patients with tumour invasion into the bladder muscle due to potentially more risk than benefits [5].

Both chemotherapy and radiotherapy have been postsurgical adjuvant choices for SCUBs. Chemotherapy may inhibit tumour progression, but with no obvious benefits in regard to the long-term survival [6]. This is consistent with what we observed in the current case in which the disease was stabilized by chemotherapy but promptly recurred thereafter [7]. The combination of gemcitabine and cisplatin used in this case proved to be effective and tolerable for high-grade epithelial tumours, but its application to SCUBs was limited to a very small cohort of patients [8, 9]. SCUBs may respond to radiotherapies such as three-dimensional conformal radiotherapy (3DCRT) and intensity modulated radiation therapy. High doses of 3DCRT may help the local control of the tumours and improve the overall survival [10].

In summary, we presented a case of SCUB in a 48-year-old patient, raising the awareness of this malignancy in the young population. Early diagnosis remains the key to improve the prognosis. Total cystectomy followed by chemotherapy is the current choice of treatment. Future

multicentre studies on a large cohort of patients with adequate evidence-based medical resources are required to develop ideal approaches to manage this aggressive malignancy.

Consent

The patient has provided informed consent for publication of the case.

Abbreviations

- TURBT:** transurethral resection of bladder tumour
SCUB: sarcomatoid carcinoma of the urinary bladder
CT: computed tomography
CK: cytokeratin
EMA: epithelial membrane antigen
IHC: Immunohistochemistry
SMA: α-smooth muscle actin
3DCRT: three-dimensional conformal radiotherapy

REFERENCES

1. Torenbeek R, Blomjous CE, de Bruin PC, Newling DW, Meijer CJ (1994) sarcomatoid carcinoma of the urinary bladder clinicopathologic analysis of 18 cases with immunohistochemical and electron microscopic findings. *Am J Surg Pathol* 18: 241-249. [[Crossref](#)]
2. Wang G, McKenney JK (2019) Urinary Bladder Pathology: World Health Organization Classification and American Joint Committee on Cancer Staging Update. *Arch Pathol Lab Med* 143: 571-577. [[Crossref](#)]
3. Wang J, Wang FW, Lagrange CA, Hemstreet Iii GP, Kessinger A (2010) Clinical features of sarcomatoid carcinoma (carcinosarcoma) of the urinary bladder: analysis of 221 cases. *Sarcoma* 2010: 454792. [[Crossref](#)]
4. Ikegami H, Iwasaki H, Ohjimi Y, Takeuchi T, Ariyoshi A et al. (2000) Sarcomatoid carcinoma of the urinary bladder: a clinicopathologic and

- immunohistochemical analysis of 14 patients. *Hum Pathol* 31: 332-340. [[Crossref](#)]
5. Lopez Beltran A, Pacelli A, Rothenberg HJ, Wollan PC, Zincke H et al. (1998) Carcinosarcoma and sarcomatoid carcinoma of the bladder: clinicopathological study of 41 cases. *J Urol* 159: 1497-1503. [[Crossref](#)]
 6. Cheng L, Zhang S, Alexander R, MacLennan GT, Hodges KB et al. (2011) Sarcomatoid carcinoma of the urinary bladder: the final common pathway of urothelial carcinoma dedifferentiation. *Am J Surg Pathol* 35: e34-e46. [[Crossref](#)]
 7. Lott S, Lopez Beltran A, Montironi R, MacLennan GT, Cheng L (2007) Soft tissue tumors of the urinary bladder Part II: malignant neoplasms. *Hum Pathol* 38: 963-977. [[Crossref](#)]
 8. Stamatou K, Galariotis N, Michailidis I, Petrakopoulou N, Moustou H et al. (2010) Sarcomatoid carcinoma of the urinary bladder: a clinicopathological study of 4 cases and a review of the literature. *Korean J Urol* 51: 724-728. [[Crossref](#)]
 9. Baseskioglu B, Duman BB, Kara IO, Can C, Yildirim M et al. (2012) Early Detection and Gemcitabine/Cisplatin Combination Positively Effect Survival in Sarcomatoid Carcinoma of the Urinary Bladder. *Asian Pac J Cancer Prev* 13: 5729-5733. [[Crossref](#)]
 10. Onal C, Pehlivan B, Bal N, Topkan E, Kilinc F et al. (2009) Sarcomatoid carcinoma of the urinary bladder treated with adjuvant radiotherapy: a case report. *Clin Med Case Rep* 2: 39-42. [[Crossref](#)]