

Available online at www.sciencerepository.org

Science Repository



Case Report and Review of The Literature

Asymptomatic Unilateral Primary Adrenal Lymphoma Mimicking a Non-Functioning Adenoma in Adult Male with a Good Outcome

Fatima Alsaad¹, Sara Alsaad², Ayman Raees³ and Abdulla Darwish^{4}*

¹Resident, Department of Urology, Bahrain Defense Force Hospital, West Riffa, Kingdom of Bahrain

²Resident, Department of Pathology, Bahrain Defense Force Hospital, West Riffa, Kingdom of Bahrain

³Consultant Urologist, Department of Urology, Bahrain Defense Force Hospital, West Riffa, Kingdom of Bahrain

⁴Consultant Histopathologist, Department of Pathology, Bahrain Defense Force Hospital, West Riffa, Kingdom of Bahrain

ARTICLE INFO

Article history:

Received: 5 March, 2020

Accepted: 24 March, 2020

Published: 31 March, 2020

Keywords:

Extranodal

unilateral

lymphoma

histopathology

ABSTRACT

Primary adrenal lymphoma (PAL) is a type of extranodal lymphoma that is rarely encountered in clinical settings. It is regarded as a high-grade malignancy with a very poor prognosis. Most PALs are bilateral and hardly unilateral. Nevertheless, a rise in the number of cases of bilateral and unilateral PALs has been noted in the past few years, with a wide range of presenting symptoms from fatigue to adrenal insufficiency. Many were found incidentally via radiology imaging or on postmortem examinations. This paper aims to report an unusual case of a unilateral primary adrenal non-Hodgkin's lymphoma in a previously healthy 53-year-old Bahraini male, who presented with vague yet persistent right flank pain of a few months' duration. Imaging modalities revealed a large right adrenal mass measuring 11x10x9 cm which was initially thought to be an adenoma on CT scan, but post laparoscopic surgical excision was diagnosed histologically as Diffuse Large B Cell Lymphoma (DLBCL). Cycles of Rituximab-CHOP chemotherapy was given, and on regular follow up for two and a half years, the patient remains disease-free with no signs of recurrence.

© 2020 Abdulla Darwish. Hosting by Science Repository.

Introduction

Primary extranodal non-Hodgkin's lymphomas (PE-NHL) are defined primarily as the appearance of lymphoma at an extranodal site, where the bulk of the malignancy is at that extranodal site, with no or minor involvement of node [1]. One of the rarest extranodal sites is the adrenal gland. PAL is extremely uncommon; accounting for only 3% of primary extranodal lymphomas, and less than 1% of all non-Hodgkin's lymphomas (NHL) [1-4]. The aetiology of PAL is unclear; however, possible but inconclusive theories include pre-existing autoimmune adrenalitis with lymphocytic infiltration or hematopoietic rest tissue in the adrenal glands [3, 4]. Furthermore, Epstein-Barr viral infection or mutations in p53 and other genes may also play a role in the tumor pathogenesis [4, 5].

PAL is primarily bilateral; however, unilateral involvement of the adrenal gland is scarcely reported and is usually secondary to

malignancies elsewhere that disseminated [4, 6]. Studies suggest a predominance in the male population [4, 6]. Though, most cases seen are usually asymptomatic and are found incidentally on radiology scans or on post-mortem examination [4, 5, 7]. It has been noticed that elderly male patients are mostly affected by PAL, presenting with fatigue, abdominal pain and frequent association with symptoms of adrenal insufficiency or failure [2].

When an adrenal mass is detected, a number of differential diagnoses must be considered and ruled out. An adrenal mass could be of a benign entity such as a simple cyst, an adenoma, lipoma, myelolipoma, and infectious like tuberculosis. The differential diagnoses also include malignancy such as neuroblastoma, adrenocortical adenocarcinoma, lymphoma, some adrenal pheochromocytomas, or metastasis to the adrenal glands (mainly from lung or breast) [8, 9].

When PAL is suspected, an ultrasound abdomen, CT scan or MRI can be done. CT scan is the preferred imaging modality after the initial

*Correspondence to: Dr. Abdulla Darwish, FRCPATH, Consultant Histopathologist, Department of Pathology, Bahrain Defense Force Hospital, West Riffa, Kingdom of Bahrain; Tel: 97339666023; E-mail: abdulla.darwish660@gmail.com

screening using the ultrasound (US) abdomen [7, 10]. Histologically, the most common type of PAL encountered is the diffuse large B-cell lymphoma (DLCL), with a non-germinal centre B-cell phenotype [2, 5, 7]. Mixed large and small cell, small noncleaved cell, and the undifferentiated type are other types of PAL that are less encountered [10].

Rituximab-CHOP chemotherapy regimen is the commonly recommended first line treatment, with laparoscopic adrenalectomy as adjuvant to chemotherapy for the larger adrenal masses [4, 7]. Despite various treatment modalities, PAL is generally known for its poor prognosis, which could be attributed to advanced age with symptoms of adrenal insufficiency at presentation, larger tumors and bilateral adrenal gland involvement [7]. The aim of this paper is to report our experience with this rare disease along with literature review.

Table 1: The patient's hormone level details with reference ranges.

Hormone	Level	Reference Range
Noreadrenaline	1348 pmol/L (228 ng/dL)	<3000 pmol/L (<507 ng/dL)
Adrenaline	<300 pmol/L (<55 ng/dL)	<900 pmol/L (<164 ng/dL)
Dopamine	<500 pmol/L (<77 ng/dL)	<1500 pmol/L (<164 ng/dL)
ACTH- Corticotrophine		
-Morning	69.1 ng/dL	5-60 ng/dL - 1.1-13.2 pmol/L
-Afternoon & Evening	15.2 pmol/L	<30 ng/dL - <6.6 pmol/L
Total urine volume	1600 ml	
Free catecholamines (Urine)		
-Noradrenaline	126 nmol/24 hours	90-500 nmol/24 hours
-Adrenaline	<27 nmol/24 hours	10-120 nmol/24 hours
-Dopamine	1744 nmol/24 hours	300-3000 nmol/24 hours
Renin	10.1 ng/dL	2.6-28.0 ng/dL
Aldosterone	10.4 ng/dL	2.2-35 ng/dL
Aldosterone/Renin ratio	10.3 ng/dL	<19.0 ng/dL

Thorough laboratory investigations were done. His cortisol level was 609.6 nmol/L (N: 83-833 nmol/L). His adrenocorticotrophic hormone (ACTH), renin, aldosterone, 24-hour urinary catecholamines and metanephrines were all within normal range (Table 1). His electrolytes (sodium, potassium and chloride) were all within normal limits. Renal and liver function tests revealed no abnormality. Right adrenalectomy was then scheduled to excise the unilateral mass and an endocrinologist was consulted prior to that. The patient was cleared for surgery. The CT scan showed an 11x10x9 cm mass originating from the right adrenal gland. The large mass was externally compressing the posterior aspect of the infra hepatic inferior vena cava (IVC). It extended medially to the right lateral side of the abdominal aorta and extended above the inferior tip of the right liver lobe. The upper pole of the right kidney was displaced inferiorly, however no compression was noted on the right renal vein and artery. The adrenal mass was of homogenous attenuation, isointense to soft tissue on pre-contrast imaging, enhancing slightly on post-contrast imaging (Figure 1). The impression was that of an adenoma, and in view of his negative catecholamines levels, it was most likely a non-functioning tumor. The left adrenal gland was unremarkable. The liver, spleen and pancreas were within normal limits.

Case Presentation

A 53-year-old male, not previously known to have any medical illness, presented with a long-standing history of constant, dull abdominal pain. He underwent a number of investigations, one of which was a CT scan which incidentally picked up a large adrenal mass. His past medical history was unremarkable and on further questioning there were no other symptoms, no past history of hypertension, diabetes mellitus or any malignancies. On physical examination, the patient generally looked well, stable and no physical signs of Cushing's syndrome or pheochromocytoma were evident. Palpation revealed the abdominal tenderness to be mostly one-sided, at the right flank quadrant, but no mass was felt.

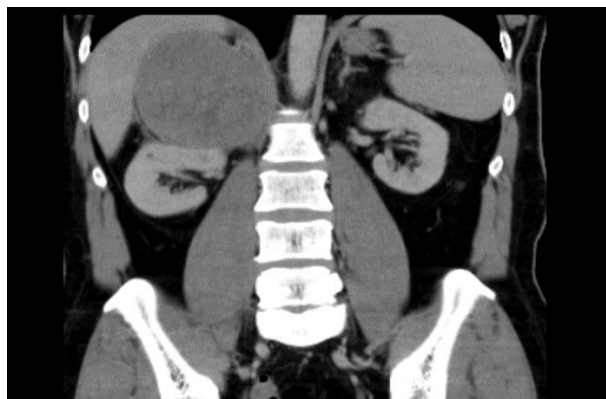


Figure 1: Pre-surgery CT scan showing a large adrenal mass above the right kidney.

The patient underwent a laparoscopic right adrenalectomy which was converted to open surgery as the mass was very close to the IVC. The specimen was sent for histopathological examination for further analysis as multiple fragments of friable greyish-white and haemorrhagic tissue

measuring altogether 28x17x5 cm (Figure 2). The specimen weighed 524.3 grams. On microscopic examination, a diffusely infiltrating tumor composed of sheets of medium sized polygonal cells having eosinophilic cytoplasm with a high mitotic rate were seen (Figures 3 & 4). The tumor focally extended to the adjacent fatty tissue. Large areas of haemorrhage and necrosis were seen (Figure 5). Residual small fragment of adrenal gland was present. The completeness of the excision was not commented on due to the fragmented nature of the specimen. Immunohistochemistry was done and the tumor cells showed a positive reaction to vimentin, LCA and CD20 (Figure 6). On the other hand, the tumor cells were negative to CD10, CD30, cyclin D1, desmin, synaptophysin, chromogranin, pankeratin, inhibin, S100, EMA, calretinin, NSE and CEA. CD3 positivity was noted in the background reactive T lymphocytes and was negative in the tumor cells. The overall appearances were in keeping with a diffuse large B cell non-Hodgkin's lymphoma.

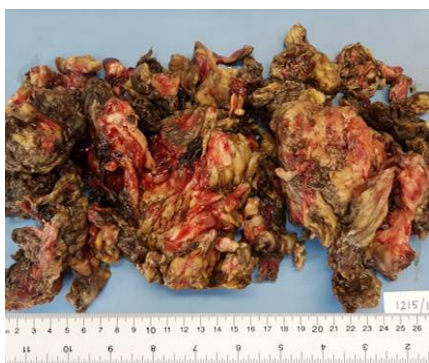


Figure 2: Macroscopic examination of the fragmented adrenal mass with surrounding fat.

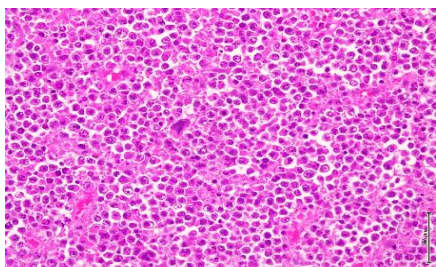


Figure 3: High power microscopic view showing a tumor composed of sheets of medium-sized polygonal cells with a high mitotic rate (H&E stain).

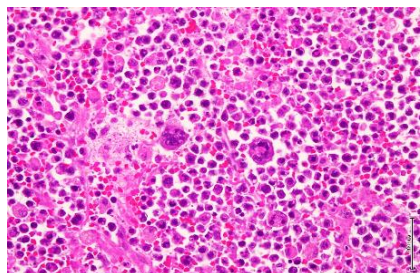


Figure 4: High power microscopic view of the tumor showing many atypical bizarre lymphoblasts (H&E stain).

Postoperatively, the patient's overall hospital course was uneventful, and he was discharged a few days later. He was referred to the Oncology service, where he completed six cycles of Rituximab-CHOP

chemotherapy and then regularly attended his follow up appointments that were scheduled at the urology clinic post hospital discharge. A follow-up positron emission tomography (PET) and regular CT scans were unremarkable. Two and a half years later, he is doing very well and no tumor recurrence is noted.

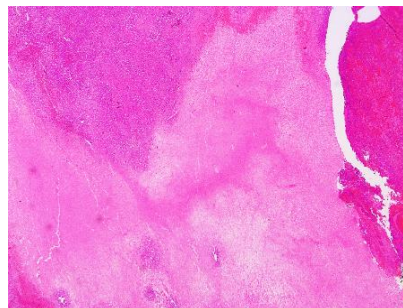

Figure 5: Low power microscopic view of the PAL showing areas of hemorrhage and necrosis (H&E stain).

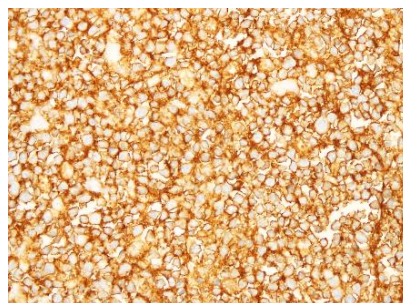


Figure 6: The tumor cells show strong positivity for CD20 tumor marker (IHC stain).

Discussion

Primary adrenal lymphoma is infrequently encountered in clinical settings generally, and it is considered a high-grade malignant lymphoma occurring in an extranodal location, with a non-favourable outcome [7, 11]. PAL is still considered a rare entity despite the noted increase in the number of cases being reported, mainly due to the improved clinical suspicion and the advanced diagnostic imaging modalities [12]. On literature review, less than 200 cases were found [1].

The exact pathogenesis remains unknown; nevertheless, many possible associations have been made. These include immune dysfunction, autoimmune-associated infections, Epstein-Barr virus infection and mutations in certain genes such as p53 and c-Kit [6]. Some researches pointed out that malignant adrenal tumors are caused by undifferentiated mesenchymal cells [4, 5, 11].

Most of PAL cases occur in the elderly male population [4, 6]. Some suggest that higher the age, worse the clinical outcome. Other reports give an average survival time of 15 months [11]. A diagnosis of PAL is quite challenging, as presenting symptoms may vary from no symptoms at all to frank B symptoms such as night sweats and high fever [7, 12]. Many may present with symptoms of adrenal insufficiency, and the few cases that don't are considered unusual, as reported by Lei *et al.* Our patient presented with vague and persistent right flank pain with no other complaints [11]. Symptoms tend to appear when more than 90% of the adrenal gland is destroyed [6]. A number of cases are detected

incidentally on imaging or on autopsy findings, hence the given name “Incidenteloma” [4, 10]. An incidenteloma describes an adrenal mass that is greater than 1 cm in maximum diameter [9]. According to Arnold *et al.*, more than half of incidentelomas are benign or hyperfunctioning adenomas that require further assessment to rule out other possible differential diagnoses [8].

The literature review of previously reported studies was mostly in consensus with regards to the diagnostic approach/imaging modalities to be used. A simple approach is to start with an ultrasound (US) abdomen, followed by CT or Magnetic Resonance Imaging (MRI). When a suspicious mass is detected, a CT-guided core needle biopsy is recommended to be sent for pathological analysis. Diffuse large B cell lymphoma (DLBCL) is the predominant type seen [2, 5, 7, 13]. Diagnosis can be made affirmatively using immunohistochemistry studies. The malignant cells are positive for to antigens specific to B lymphocytes, like CD20, CD79a and CD74 [5, 7, 11]. In our case, the tumor cells showed a strong positive reaction to CD20.

Patients diagnosed with non-Hodgkin’s lymphoma are assigned a stage using the Ann Arbour staging system. This system was originally developed to stage Hodgkin’s lymphoma, but was then adapted for both types [14]. Kim *et al.* proposed a modification to the staging system redefining extranodal involvement, which stated the following: (1) Stage I was defined as the disease being confined to the adrenal gland only (be it in one or both adrenal glands), (2) Stage II included local or distant abdominal nodal involvement, and (3) Stage IV was defined as concomitant supra-diaphragmatic nodal involvement or disseminated extranodal disease [2]. Involvement of other organs outside of the adrenals is not usually seen at presentation, but as the disease progresses, generalised involvement of various systems including the central nervous system (CNS) has been reported [3, 4].

Treatment options include undergoing surgical resection, chemotherapy and radiotherapy, thus choosing a single, most optimal treatment modality is difficult and highly debatable [2]. It has been reported that chemotherapy is the advised mode of treatment, using the R-CHOP regimen (Rituximab, Cyclophosphamide, Doxorubicin, Vincristine and Prednisolone), with surgery as an adjuvant to chemotherapy treatment [4, 6]. The chemotherapy treatment courses plus the doses of the agents used are to be modified by the treating physicians according to the patient’s condition [5]. The surgical intervention is to be individualised, taking into consideration the age, medical background and patients’ preference [4, 13]. In our patient, the initial impression was not a lymphoma thus the approach was different. Surgical resection was done first and then six cycles of R-CHOP chemotherapy were given after the pathology diagnosis was established. No clear role of radiotherapy has been proposed. In young patients in the early stages of the disease, autologous peripheral blood stem cell transplant is encouraged as some authors reported promising outcomes [4, 7].

PAL has poor prognosis, where Chen *et al.* stated that the one-year survival rate is as low as 17.5% [6]. However, Kim *et al.* concluded that the prognostic outcomes using R-CHOP combination chemotherapy are much better than what was previously reported in the literature, suggesting it as an effective first line regimen for cases of primary adrenal DLBCL with better long term outcomes [2, 5, 7].

Conclusion

Although the prognosis for PAL is poor, our patient remains disease-free on regular two and a half years follow up post-surgical resection of the adrenal mass and post six cycles of R-CHOP chemotherapy. We believe that early diagnosis with appropriate clinical, radiological and pathological investigations along with a proper treatment plan and the right chemotherapy regimen play an important role in patient survival.

Conflicts of Interest

None.

REFERENCES

1. Radhakrishnan RK, Mittal BR, Reddy Gorla AK, Malhotra P, Bal A et al. (2018) Unilateral Primary Adrenal Lymphoma: Uncommon Presentation of a Rare Disease Evaluated Using ¹⁸F-fluorodeoxyglucose Positron Emission Tomography/Computed Tomography. *World J Nucl Med* 17: 46-48. [[Crossref](#)]
2. Kim YR, Kim JS, Min YH, Hyunyon D, Shin HJ et al. (2012) Prognostic factors in primary diffuse large B-cell lymphoma of adrenal gland treated with rituximab-CHOP chemotherapy from the Consortium for Improving Survival of Lymphoma (CISL). *J Hematol Oncol* 5: 49. [[Crossref](#)]
3. Aydın K, Okutur K, Bozkurt M, Aydın Ö, Namal E et al. (2013) Primary adrenal lymphoma with secondary central nervous system involvement: a case report and review of the literature. *Turk J Haematol* 30: 405-408. [[Crossref](#)]
4. Karimi F (2017) Primary Adrenal Lymphoma Presenting with Adrenal Failure: A Case Report and Review of the Literature. *Int J Endocrinol Metab* 15: e12014. [[Crossref](#)]
5. Ichikawa S, Fukuhara N, Inoue A, Katsushima H, Ohba R et al. (2013) Clinicopathological analysis of primary adrenal diffuse large B-cell lymphoma: effectiveness of rituximab-containing chemotherapy including central nervous system prophylaxis. *Exp Hematol Oncol* 2: 19. [[Crossref](#)]
6. Chen P, Jin L, Yang Y, Ni L, Yang S et al. (2017) Bilateral primary adrenal diffuse large B cell lymphoma without adrenal insufficiency: A case report and review of the literature. *Mol Clin Oncol* 7: 145-147. [[Crossref](#)]
7. Kim KM, Yoon DH, Lee SG, Lim SN, Sug LJ et al. (2009) A case of primary adrenal diffuse large B-cell lymphoma achieving complete remission with rituximab-CHOP chemotherapy. *J Korean Med Sci* 24: 525-528. [[Crossref](#)]
8. Arnold DT, Reed JB, Burt K (2003) Evaluation and management of the incidental adrenal mass. *Proc (Bayl Univ Med Cent)* 16: 7-12. [[Crossref](#)]
9. Mearini L, Del Sordo R, Costantini E, Nunzi E, Porena M (2012) Adrenal Oncocytic Neoplasm: A Systematic Review. *Urol Int* 91: 125-133. [[Crossref](#)]
10. Kacem K, Zriba S, Lakhall RB, Bouteraa W, Aissaoui L et al. (2014) Primary adrenal lymphoma. *Turk J Haematol* 31: 188-191. [[Crossref](#)]
11. Zheng L, Wang QF, Jiang T, Li QL, Wang KN et al. (2017) Bilateral Adrenal Primary Diffuse Large B-Cell Lymphoma not accompanied by

- Adrenal Insufficiency: A Report of Two Cases. *Chemo Open Access* 6: 2.
12. Joseph FG, Cook S, Gowda D (2017) Primary adrenal lymphoma with initial presentation concerning for bilateral adrenal pheochromocytomas. *BMJ Case Rep* 2017: bcr-2017-220549. [[Crossref](#)]
 13. Aravamudan VM, Fong PK, Sam YS, Singh P, Siok Bian Ng et al. (2017) A Rare Case of Primary Bilateral Adrenal Lymphoma. *Case Rep Med* 2017: 1251950. [[Crossref](#)]
 14. Armitage JO (2005) Staging non-Hodgkin Lymphoma. *CA Cancer J Clin* 55: 368-376. [[Crossref](#)]