

Available online at [www.sciencerepository.org](http://www.sciencerepository.org)

Science Repository



## Case Report

# Analysis of an End Neuroma 6 Months after Capping with a Bioresorbable Polycaprolactone Cap (NEUROCAP®) in a Human Model

Samuel George<sup>1\*</sup>, Ute Pohl<sup>2</sup> and Dominic Power<sup>3</sup>

<sup>1</sup>Peripheral Nerve Fellow, University Hospitals Birmingham NHS Foundation Trust, UK

<sup>2</sup>Consultant Neuropathologist, University Hospitals Birmingham NHS Foundation Trust, UK

<sup>3</sup>Consultant Hand and Peripheral Nerve Surgeon, University Hospitals Birmingham NHS Foundation Trust, UK

### ARTICLE INFO

#### Article history:

Received: 20 December, 2019

Accepted: 3 January, 2020

Published: 30 January, 2020

#### Keywords:

Neuroma

neurocap

polycaprolactone

end neuroma

nerve cap

nerve

pain

polyganics

### ABSTRACT

Various methods have been described in the literature for the treatment of painful end neuromas. One technique involves capping the neuroma with a biological or synthetic material. However, failure of this technique may result from mechanical irritation of the capped nerve. In addition, the physical act of blocking the nerve end is insufficient to prevent further neuroma formation and additional measures need to be taken to halt the regenerative process of the nerve. A new technique of using a bioresorbable polycaprolactone cap (NEUROCAP®), leaving a chamber distal to the nerve ending, has been studied in animal models. The chamber results in a resultant thinner, cone shaped neuroma with a more organised fascicle structure. The chamber prevents mechanical tether or compression by scar. The cap resorbs, preventing mechanical irritation of the nerve ending. We present a case where a NEUROCAP® was excised 6 months after implantation and the nerve end was studied. This study is the first of its kind, analysed in a human model.

© 2020 Samuel George. Hosting by Science Repository.

## Introduction

It is often said that the more techniques there are to treat a problem, the less likely it is that any one treatment is more effective than the others. The painful neuroma falls into this category with more than 150 methods described in the literature to date to prevent the growth of them [1]. Current evidence has shown that regardless of the method used, clinically meaningful resolution of pain will be seen in 77% of patients [2]. Capping the end neuroma stump is one such method and this has been attempted with various synthetic materials as well as veins [3, 4]. Silicone caps were used as early as 1967 [5-7]. Unfortunately, the older silicone caps were either too snug, causing swelling of the proximal nerve, or too loose to prevent the retrograde escape of nerve fascicles causing outgrowth into surrounding tissue along with problems of having a foreign body in the site [5]. The quality of data available is

lacking due to small numbers as well as a paucity of standardised outcome reporting of long-term data and treatment failures [2]. Historical methods concentrated on halting or blocking fibres rather than suppressing their growth, leading to failures [8]. The NEUROCAP® is one of the treatment modalities used, and to date, the only data available in the literature on the long-term histological sequelae has been in animal models. We present a case in which a previous NEUROCAP® has been used where a patient needed re-operation for removal and re-capping, enabling us to study in detail the effects the bioresorbable cap had on the capped stump after 6 months, the first of its kind studied in a human model.

## Methods

The cap used and subsequently excised in this patient was a transparent bioresorbable polycaprolactone device called a NEUROCAP®

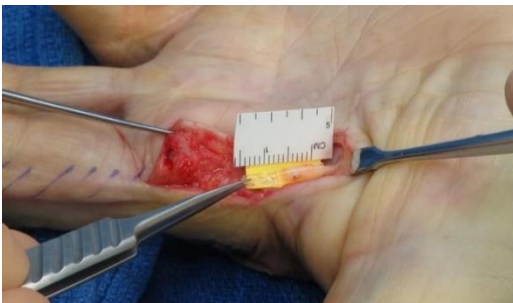\*Correspondence to: Samuel George, Peripheral Nerve Fellow, Peripheral Nerve Injury Service, Trauma & Orthopaedics, University Hospitals Birmingham NHS Foundation Trust, Queen Elizabeth Hospital Birmingham, Mindelsohn Way, Edgbaston, Birmingham B15 2GW, UK; Tel: +447403053945; E-mail: [samgeorge@dr.com](mailto:samgeorge@dr.com)

manufactured by Polyganics (Groningen, Netherlands). Launched in 2016, the cap leaves a small chamber to allow unsupported neural regeneration and blocks the neuroma from adjacent tissues to prevent the typical neuronal sprouting that renders neuromas symptomatic. It degrades by hydrolysis from 12 weeks and is completely resorbed in 18 months [9].

### Case Report

We present the case of a 74-year old man who suffered a complex hand injury from a circular saw. During the initial injury, he required an amputation of his index finger as well as radial and ulnar digital nerve grafting to the middle finger, ulnar digital nerve graft to the ring, and repair of the ulnar digital nerve to the little finger. The patient subsequently was sensitised on his middle finger, bypassing it and using the ring finger for precision pinch. Although he had excellent function, the neuropathic pain was debilitating. Analgesic medication, oral neuromodulator therapy and radio-frequency ablation and medication helped the radial side pain, but the ulnar digital nerve remained problematic. Local anaesthetic nerve blockade provided an effective temporary resolution of the pain, assisting in planning further surgical exploration. There was no useful function in the ulnar nerve territory, and so a proximal neurectomy and implantation of a bioresorbable polycaprolactone cap (NEUROCAP®) was undertaken in September 2017, more than 4 years after the initial injury. This surgery was extremely effective, and the patient reported 0/10 pain 3 months post-operatively.

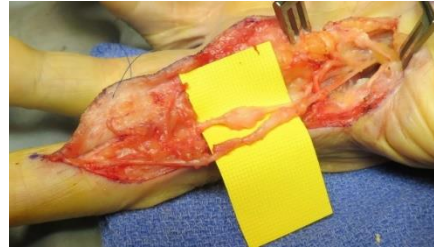
Unfortunately, there appeared to be some central sensitisation of the pre-existing mild radial digital nerve territory pain, increasing to 7/10. The patient requested resection and capping of the radial digital nerve. We were reluctant initially as this was now his border digit. However, he was bypassing the digit for precision grip with the thumb to the ring finger, and the pain was affecting his quality of life. A second procedure was undertaken to resect and cap the radial digital nerve in May 2018 (Figure 1), 8 months after the ulnar digital nerve (UDN) was capped.



**Figure 1:** Capping of the nerve end after excision of the radial digital nerve neuroma to the middle finger.

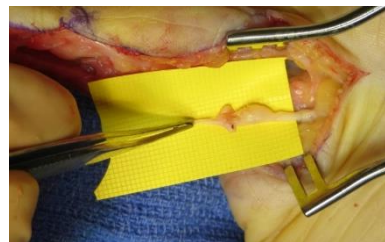
Two months after the second procedure and 10 months after the initial UDN cap, he reported persisting pain on the radial side with no reduction in pain severity. Some mild sensation remained in the radial digital nerve territory. There was concern that the neuroma capping had been to one of the nerve stump neuromas of the original index finger, rather than the radial digital nerve to the middle and so a further exploration was offered. In January 2019, exploration confirmed the cap was placed on the ulnar digital nerve stump from the index. Two volar branches of the

RDN to the middle finger were identified in the scar. Both branches had neuromas in continuity (Figure 2).



**Figure 2:** Two branches of the radial digital nerve to the middle finger, both with neuroma-in-continuity.

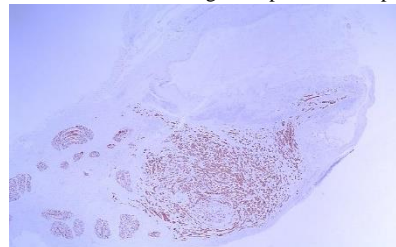
The radial digital nerve branches were resected proximal to the neuromas, and a NEUROCAP® was applied. During the third operation, the exposure of the radial digital nerves necessitated resection of the previous cap, which had been implanted 6 months before. The resected specimen did not appear to have a large neuroma. The tissue was excised en-bloc and sent for histology (Figure 3), along with the two neuroma specimens from the radial side of the middle finger. The third procedure relieved the middle finger pain. The explanted most of the pain NEUROCAP® and surrounding tissue was histologically examined to determine the in-vivo inflammatory response and the extent of any recurrent neuroma formation.



**Figure 3:** Six months following figure 1 demonstrating the capped ulnar digital nerve of the index finger.

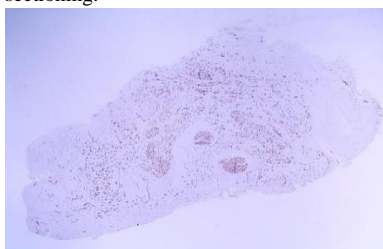
### Histopathology

The specimens from the radial nerve to the middle finger confirmed neuromas. The specimens from the NEUROCAP® explantation demonstrated debris consistent with polymer degradation. Macroscopically there was a granular appearance. The en-bloc specimen of the capped ulnar digital nerve neuroma to the index microscopically showed amorphous, pale eosinophilic material mixed with scanty mononuclear cells compatible with leukocytes. There was no evidence of inflammation or neoplasia. This amorphous material was presumably the residue from the degraded part of the cap.



**Figure 4:** (20x mag) Capped neuroma at 6 months, Neurofilament immunohistochemistry: Prominent granulomatous inflammation to cap material, but more compact neuroma / microfascicle formation and distribution.

Figure 4 is the histological appearance using neurofilament staining of the capped neuroma seen in (Figure 3). On one end of the specimen, there is a patchy moderate chronic granulomatous inflammatory infiltrate with a florid foreign body type giant cell reaction, forming a cyst-like space enclosing amorphous eosinophilic material, again as above presumed to be the degrading cap material. The other end contains fascicles with a small area of overlying microfascicular structure consistent with a small recurrent neuroma that is encased within a thin layer of fibrous tissue. Figure 5 demonstrates the resected uncapped neuroma from the radial digital nerve to the middle finger. This uncapped new neuroma contained seven fascicles, surrounded by numerous microfascicles, embedded in dense fibrous tissue. There was no evidence of inflammation or granuloma formation, and no evidence of neoplasia (Figure 5). The main difference between the capped neuroma (Figure 4) and the uncapped neuroma (Figure 5) is that although both specimens had histological evidence of neuroma formation, the neuroma in the capped specimen was more compact with less microfascicular spread beyond the normal nerve at the point of sectioning.



**Figure 5:** (20x mag) Uncapped new neuroma, Neurofilament immunohistochemistry: No significant inflammation, in particular, no granulomatous inflammation, but more diffuse neuroma / microfascicle formation and distribution.

## Discussion

The use of silicone to cap an end neuroma was first described by Tauras and Frackelton in 1967, while Ducker and Hayes demonstrated using a silastic cuff to assist in peripheral nerve repairs the year after [7, 10]. In 1976, Tupper and Booth looked at using these silicone rubber caps as a secondary procedure to treat failed primary neurectomies for simple neuromas. They used two types of tubes, one which was a snug fit (Frackelton cap) and another which had a loose fit (Ducker-Hayes cuff). Both techniques did not leave a chamber distal to the nerve end and they obtained excellent results in only 25% of patients. They re-explored capping failures, and in half of these, the caps had dislodged, resulting in adherence of neuroma ends to surrounding tissue. In the loose-fitting Ducker-Hayes caps, the nerve fibres had grown out through the loose proximal opening, and one of the snugly fitting caps demonstrated swelling of the nerve proximal to the cap [5, 11].

Swanson et al. studied silicone capping of neuromas in a rabbit model and found that neuroma formation was prevented when a length to diameter ratio of 5:1 up to 10:1 was used [6]. Martini and Fromm obtained good results by dissecting the fascicles away from the epineurium, trimming them back and re-advancing the epineurium, and finally sealing off the space in between the bare epineurium with tissue glue. Two out of 16 nerves developed neuromas using this method in a rat model, although it was not a true capping method [1]. Sakai et al. evaluated the effects of using silicone caps and atelocollagen tubes to

cap resected 4-week old neuromas in a rat model. While they found the typical bulbous neuroma in the control groups, the silicone and atelocollagen groups demonstrated only very thin nerve structure regeneration as well as reduced markers of pain expression [12]. The problems faced by silicone caps, including the foreign body reactions resulted in the technique losing popularity and common practice among surgeons today is to implant nerve ends after neuroma resection into muscle or bone [2, 13].

The newer bioresorbable caps and aligned nanofiber conduits with neurotrophic factors have shown promising results in rat models. There, the weight ratio of neuromas was significantly higher in uncapped nerves, while capped nerves had bullet shaped neuromas integrated within the conduit. These studies have also shown lower expression of pain markers in the capped group [14]. Animal studies have shown that when a nerve is capped with a chamber distal to the nerve end, this results in a nerve that peters out, losing its drive for regeneration. A neuroma still forms initially, but these neuromas have more myelinated fascicles which are organised rather than chaotic. The myelin sheaths are thicker, and although asymptomatic neuromas are usually indistinguishable histologically from painful ones, these features might account for the resolution of symptoms seen, and lower the expression of pain markers [6, 14]. These findings echo ours, where both specimens showed similar neuroma formation with microfascicles and fibrous scar, but the capped neuroma showed a more compact growth, which had most fascicles confined to a small area inside the capped end. Ideally, the nerve end with the excised neuroma should have been inserted further down the cap so that the cap could have encapsulated a good portion of the distal nerve stump. In the slide, in (Figure 4), it appears that the terminal end of the neuroma was sitting very close to where the proximal end of the cap would have been. This could be due to a slight technical error or loosening in-vivo post-operatively.

## Conclusion

Neuroma formation and its aetiology are still very poorly understood. As technology improves, our understanding of the relationship between nerve regeneration and clinically symptomatic neuromas will guide treatment into the near future. The latest technologies include electrospun aligned nanofiber conduits modified with biocompatible peptides to provide a suitable microenvironment to prevent neuroma formation [15]. Our analysis of a bioresorbable polycaprolactone cap is the first in a human model. It will improve our understanding of how these materials behave and influence nerve regeneration to help tailor future innovations.

## Conflicts of Interest

The senior author DP was involved in the PROSPECTIVE COHORT - EVALUATION OF NEUROCAP® - In the Treatment of symptomatic Neuroma (PROTECT NEURO trial), which was run and funded by Polyganics (Groningen, Netherlands). However, the trial is closed, and this study/case report is outside the trial and is not funded or commissioned by Polyganics.

## Funding

None.

## REFERENCES

1. Martini A, Fromm B (1989) A new operation for the prevention and treatment of amputation neuromas. *J Bone Joint Surg* 71: 379-382. [[Crossref](#)]
2. Poppler LH, Parikh RP, Bichanich MJ, Rebehn K, Bettlach CR et al. (2018) Surgical interventions for the treatment of painful neuroma: a comparative meta-analysis. *Pain* 159: 214-223. [[Crossref](#)]
3. Eberlin KR, Ducic I (2018) Surgical algorithm for neuroma management: A changing treatment paradigm. *Plast Reconstr Surg Glob Open* 6: e1952. [[Crossref](#)]
4. Galeano M, Manasseri B, Risitano G, Geuma S, Di Scipio F et al. (2009) A free vein graft cap influences neuroma formation after nerve transection. *Microsurgery* 29: 568-572. [[Crossref](#)]
5. Tupper JW, Booth DM (1976) Treatment of painful neuromas of sensory nerves in the hand: a comparison of traditional and newer methods. *J Hand Surg Am* 1: 144-151. [[Crossref](#)]
6. Swanson AB, Boeve NR, Lumsden RM (1977) The prevention and treatment of amputation neuromata by silicone capping. *J Hand Surg Am* 2: 70-78. [[Crossref](#)]
7. Tauras AP, W H Frackelton (1967) Silicone capping of nerve stumps in the problem of painful neuromas. *Surg Forum* 18: 504.
8. Edds MV Jr (1945) Prevention of nerve regeneration and neuroma formation by caps of synthetic resin. *J Neurosurg* 2: 507-509. [[Crossref](#)]
9. Challoner T, Nijran A, Power DM (2019) The surgical management of traumatic neuromas. *J Musculoskelet Surg Res* 3: 22-29.
10. Ducker TB, G J Hayes (1968) Experimental improvement in the use of Silastic cuff for peripheral nerve repair. *J Neurosurg* 28: 582-587. [[Crossref](#)]
11. Herndon JH, Eaton RG, Littler JW (1976) Management of painful neuromas in the hand. *J Bone Joint Surg Am* 58: 369-373.
12. Sakai Y, Ochi M, Uchio Y, Ryoke K, Yamamoto S (2005) Prevention and treatment of amputation neuroma by an atelocollagen tube in rat sciatic nerves. *J Biomed Mater Res B Appl Biomater* 73: 355-360. [[Crossref](#)]
13. Dellon AL, Mackinnon SE (1986) Treatment of the painful neuroma by neuroma resection and muscle implantation. *Plast Reconstr Surg* 77: 427-438. [[Crossref](#)]
14. Yan H, Zhang F, Kolkin J, Wang C, Xia Z et al. (2014) Mechanisms of nerve capping technique in prevention of painful neuroma formation. *PLoS One* 9: e93973. [[Crossref](#)]
15. Yi J, Jiang N, Li B, Yan Q, Qiu T et al. (2018) Painful Terminal Neuroma Prevention by Capping PRGD/PDLLA Conduit in Rat Sciatic Nerves. *Adv Sci (Weinh)* 5: 1700876. [[Crossref](#)]