

Available online at [www.sciencerepository.org](http://www.sciencerepository.org)

Science Repository



## Case Report

# Epidermoid Cyst within an Intrapancreatic Accessory Spleen Mimicking a Pancreatic Cystic Neoplasm

Arezou Abbasi<sup>1</sup>, Florencia G Jalikis<sup>2</sup>, Lisa K Koch<sup>2</sup> and Venu G Pillarisetty<sup>1\*</sup>

<sup>1</sup>Department of Surgery, University of Washington

<sup>2</sup>Department of Pathology, University of Washington

### ARTICLE INFO

#### Article history:

Received: 1 January, 2020

Accepted: 18 January, 2020

Published: 31 January, 2020

#### Keywords:

*Intrapancreatic accessory spleen  
epidermoid cyst  
pancreatic cyst*

### ABSTRACT

Although intra-abdominal accessory spleens are commonly found in 10-30% of the general population, epidermoid cyst within an intrapancreatic accessory spleen (ECIPAS) is an extremely rare entity and is often misdiagnosed preoperatively as a cystic malignancy. We present the case of a 51-year-old man who was referred to our clinic because of an incidentally found pancreatic tail cystic mass. Due to CA 19-9 level over 2000 and high suspicion of malignancy, the patient underwent distal pancreatectomy with splenectomy. Histopathological analysis revealed a squamous epithelial lining with splenic parenchyma within the cyst wall, which was consistent with ECIPAS. The patient was discharged on postoperative day 4 without any complication. As this disease may mimic malignancy with no characteristic features in preoperative imaging, it should be considered in the differential diagnosis of pancreatic cystic lesions.

© 2020 Venu G Pillarisetty. Hosting by Science Repository.

### Introduction

Accessory spleens (AS) are ectopic masses comprised of splenic tissue found incidentally in 10-30% of the population [1]. The splenic hilum and pancreatic tail are the two most common sites of AS. Other rare sites include stomach, greater omentum, retroperitoneum and pelvis. An epidermoid cyst in an intrapancreatic accessory spleen (ECIPAS) is a non-malignant true cyst within the pancreas lined with squamous epithelium and surrounding parenchyma showing histologic characteristics of AS. The first report of ECIPAS was published by Davidson et al. in 1980 [2]. The diagnostic challenge of this disease is differentiating it from other pancreatic cystic lesions, some of which contain adenocarcinoma. In recent years, due to the advanced diagnostic imaging techniques, increased number of ECIPASs are being reported [3]. However, the true prevalence of ECIPAS remains unknown due to its rarity. Herein, we report a case of ECIPAS diagnosed post-operatively in a 51-year-old male.

### Case Presentation

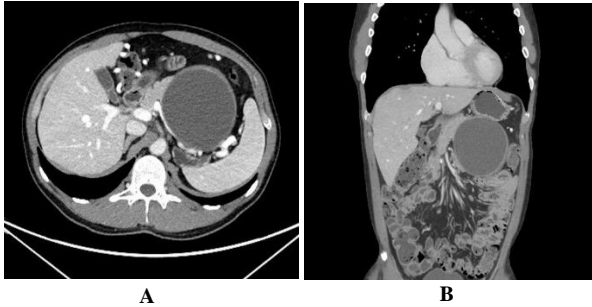
A 51-year-old man was referred to our clinic because of an incidentally found pancreatic tail mass. He initially was admitted to another center with pain and swelling in his left testis, which resolved after a course of antibiotics. Due to the right-sided hydronephrosis revealed by an ultrasonographic examination of the kidneys, the patient underwent an abdominal CT scan to rule out kidney stones. He had no past medical history, and physical examination was unrevealing. The patient reported no other symptoms, including abdominal pain, diarrhea, constipation, weight loss, nausea, or vomiting.

Contrast-enhanced abdominal CT scan showed an 11×11 cm unilocular cyst with a thick, mildly enhancing rim in the pancreatic tail (Figure 1). Splenic vein compression was noted, but there was no vascular invasion or lymphadenopathy. Furthermore, no communication between the cyst and the main pancreatic duct was seen. The laboratory work-up was unremarkable, except for a CA 19-9 over 2000.

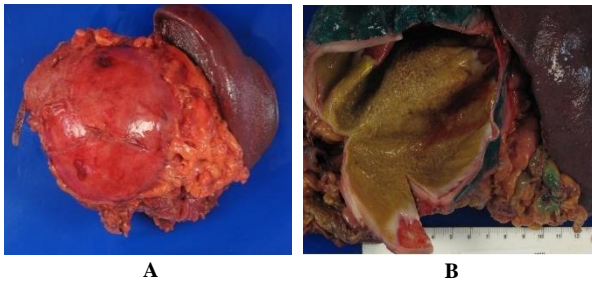
Mucinous cystic neoplasm, cystic pancreatic neuroendocrine tumor, IPMN and solid pseudopapillary tumor were in the differential

\*Correspondence to: Venu G Pillarisetty, M.D., FACS, Associate Professor, HPB Surgical Oncology, University of Washington, Medical Director, Continuous Performance Improvement, Seattle Cancer Care Alliance, 1959 NE Pacific Street, Box 356410, Seattle, WA 98195-6410; Tel: 2066164924; Fax 2065438136; E-mail: [vgp@uw.edu](mailto:vgp@uw.edu)

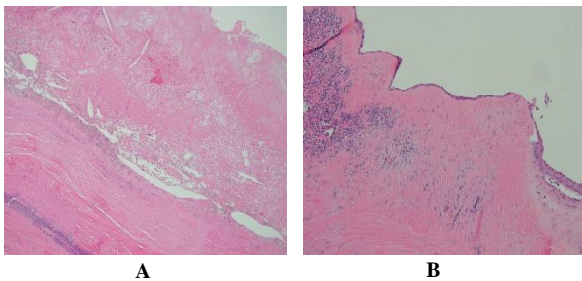
diagnosis. Based on the imaging characteristics and the elevated CA 19-9, mucinous cystic neoplasm was highly suspected, despite the low incidence of this type of lesion in men. Following a diagnostic laparoscopy to rule out evidence of small-volume intraperitoneal metastatic disease, a laparoscopically assisted distal pancreatectomy with splenectomy was performed. Due to the large size of the cyst and its adherence to the adjacent organs and the retroperitoneum, we additionally performed partial left adrenalectomy and segmental left hemicolectomy.



**Figure 1:** Abdominal CT scan with contrast shows a unilocular cyst with mildly enhancing rim in pancreatic tail, **A)** axial. **B)** coronal views.



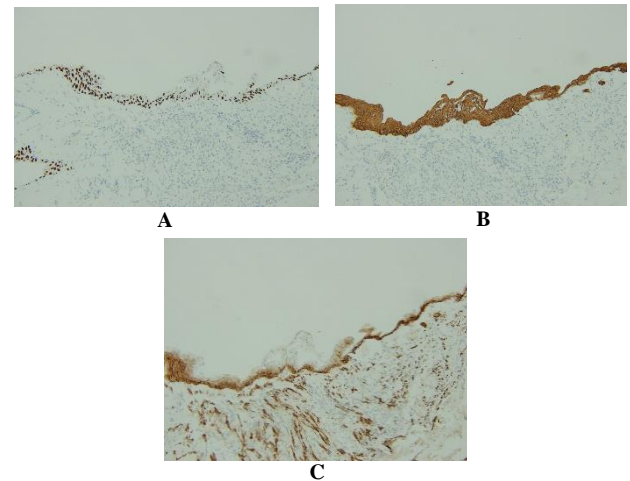
**Figure 2:** Macroscopic image of the epidermoid cyst in an intrapancreatic accessory spleen (ECIPAS), **A)** large smooth mass in the tail of the pancreas with adjacent spleen and the normal spleen. **B)** thick, fibrotic cyst wall with grungy, yellow-brown contents.



**Figure 3:** Microscopic findings. **A)** Extensively denuded cyst wall with associated keratin debris and cholesterol clefts, H&E stain, 100x. **B)** Preserved lining exhibiting mixed cuboidal and multilayer epithelium, and fibrotic cyst wall containing splenic parenchyma, H&E stain, 100x.

Postoperatively, the patient was managed according to our standard enhanced recovery after surgery (ERAS) pathway and after 4 uneventful days, he was discharged home. No complications were noted up to 3 months postoperatively. Macroscopic examination of the 10.1×9.5×7.8 cm tumor revealed a thick (0.6 cm) fibrotic wall (Figure 2). The cyst contained thin brown fluid with no further loculations or distinct masses on the inner surface. On microscopy, the cyst was lined by mixed cuboidal and multilayer epithelium that was positive for squamous (CK5 and P40) and mesothelial (podoplanin) markers (Figures 3 & 4). Within the cyst wall, splenic parenchyma composed of lymphoid tissue

intermixed with red cells and vasculature was evident (Figure 3). These findings were consistent with a definitive diagnosis of ECIPAS.



**Figure 4:** The lining epithelium demonstrated P40, CK5 and podoplanin immunoreactivity. **A)** p40 immunostain, 100x. **B)** CK5 immunostain, 100x. **C)** Podoplanin immunostain, 100x.

## Discussion

ECIPAS are extremely rare, with sparse case reports mostly from the Asian countries [3, 4]. To the best of our knowledge, all epidermoid cysts of an accessory spleen, reported in the literature, were intrapancreatic except for one case report by Mori et al. They reported a huge cyst derived from an accessory spleen located in the greater omentum [5].

Due to its rarity, the exact histopathologic origin of this cyst has been a source of debate. Protrusion of the pancreatic ducts into an accessory spleen located in the pancreatic tail is one of the proposed theories [6-8]. Furthermore, for epidermoid cysts of the spleen, it has been suggested that inclusion cysts develop from mesothelial cells of the splenic parenchyma and undergo squamous metaplasia, leading to expression of CEA and CA 19-9. In contrast, analyzing the cytokeratin pattern of epidermoid cysts of the spleen, Lifschitz-Mercer et al. proposed a teratomatous origin, which derives from inclusion of fetal squamous epithelial tissue [9].

The importance of this benign yet clinically challenging disease lies in the fact that in most cases, as in ours, CA 19-9 is elevated [10-12]. High CA 19-9 without pathognomonic imaging features makes preoperative differentiation between the ECIPAS and a malignancy exceptionally difficult. Consequently, few cases have been diagnosed pre-operatively [13]. Hu et al. suggested that ECIPAS should be considered if the cystic wall and spleen show similar contrast enhancement during multiphase scans [3]. However, given the limited available data on ECIPAS, surgical resection remains the only option for definitive diagnosis.

## REFERENCES

1. Paredes A, Beal EW, Dillhoff ME (2018) Epidermoid cyst within an intrapancreatic accessory spleen. *BMJ case rep pii:* bcr-2017-223600. [[Crossref](#)]

2. Davidson ED, Campbell WG, Hersh T (1980) Epidermoid splenic cyst occurring in an intrapancreatic accessory spleen. *Dig Dis sci* 25: 964-967. [[Crossref](#)]
3. Hu S, Chen K (2012) Epidermoid cyst in intrapancreatic accessory spleen: computed tomography findings and clinical manifestation. *Abdom Imaging* 37: 828-833. [[Crossref](#)]
4. Servais EL, Sarkaria IS, Solomon GJ, Gumpeni P, Lieberman MD (2008) Giant epidermoid cyst within an intrapancreatic accessory spleen mimicking a cystic neoplasm of the pancreas: case report and review of the literature. *Pancreas* 36: 98-100. [[Crossref](#)]
5. Mori M, Ishii T, Iida T, Tanaka F, Takikawa H et al. (2003) Giant epithelial cyst of the accessory spleen. *J HepatoBiliary Pancreatic Surg* 10: 118-120. [[Crossref](#)]
6. Tateyama H, Tada T, Murase T, Fujitake S, Eimoto T (1998) Lymphoepithelial cyst and epidermoid cyst of the accessory spleen in the pancreas. *Mod pathol* 11: 1171-1177. [[Crossref](#)]
7. Sasou S, Nakamura Si, Inomata M (1999) Epithelial splenic cysts in an intrapancreatic accessory spleen and spleen. *Pathol Int* 49: 1078-1083. [[Crossref](#)]
8. Kadota K, Kushida Y, Miyai Y, Katsuki N, Hayashi T et al. (2010) Epidermoid cyst in an intrapancreatic accessory spleen: three case reports and review of the literatures. *Pathol Oncol Res* 16: 435-442. [[Crossref](#)]
9. Lifschitz-Mercer B, Kushnir I, Czernobilsky B (1994) Epidermoid cyst of the spleen: a cytokeratin profile with comparison to other squamous epithelia. *Virchows Archiv* 424: 213-216. [[Crossref](#)]
10. Hirabayashi K, Yamada M, Kono H, Hadano A, Kawanishi A et al. (2017) Epidermoid cysts are a characteristic feature of intrapancreatic but not of extrapancreatic accessory spleens. *Virchows Archiv* 471: 91-98. [[Crossref](#)]
11. Zavras N, Machairas N, Foukas P, Lazaris A, Patapis P et al. (2014) Epidermoid cyst of an intrapancreatic accessory spleen: a case report and literature review. *World J Sur Oncol* 12: 92. [[Crossref](#)]
12. Fujii M, Yoshioka M, Shiode J (2016) Two cases of an epidermoid cyst developing in an intrapancreatic accessory spleen identified during laparoscopic distal pancreatectomy. *Intern Med* 55: 3137-3141. [[Crossref](#)]
13. Zhou B, Zhang Q, Zhan C, Ding Y, Yan S (2018) Laparoscopic spleen-preserving pancreatic resection for epidermoid cyst in an intrapancreatic accessory spleen: case report and literature review. *Ther Clin Risk Manag* 14: 937-944. [[Crossref](#)]