

Available online at [www.sciencerepository.org](http://www.sciencerepository.org)

Science Repository



## Case Report and Review of Literature

# Richter Paraumbilical Hernia Managed by Invagination: A Case Report and Review of Literature

*K Ahmed\* and A Abo-elmagd*

*General Surgery Department, Alexandria Main University Hospital, Alexandria, Egypt*

### ARTICLE INFO

#### Article history:

Received: 23 November, 2019

Accepted: 20 December, 2019

Published: 27 December, 2019

#### Keywords:

*Richter hernia*

*paraumbilical hernia*

*invagination*

### ABSTRACT

**Background:** Richter hernia is a peculiar type of enterocele, which may progress to fatal bowel perforation unless early intervention is made. It used to occur at femoral ring but occurrence at ventral hernia is extremely rare.

**Case presentation:** We report a 60-year-old female patient with tender paraumbilical hernia with absolute constipation and vomiting. On examination the patient had a low-grade fever, while the swelling was tense, tender with no impulse on cough. Plain radiograph abdomen erect position was done revealing multiple air fluid level. Repair was done after invagination of the ischemic part of the bowel loop.

**Conclusion:** ventral hernia may be of a Richter type. Management of ischemic loop in Richter hernia does not necessitate resection and anastomosis, as invagination only is enough. Repair of the defect is mandatory while mesh placement is conditional.

© 2019 Khaled Ahmed. Hosting by Science Repository.

### Introduction

Richter hernia is a special type of hernia in which part of the circumference of bowel loop is entrapped in the sac through a defect. It usually occurs in old female patients, mostly at femoral ring deep inguinal ring. Nowadays it became more noticed in port site hernia after laparoscopic surgery [1]. It has different presentation from painless abdominal swelling up to enterocutaneous fistula. Its management is variable according to condition of the entrapped bowel, while mesh placement is controversial [2]. Here we are reporting a rare case of Richter paraumbilical hernia with a short review of the related literature regarding different presentations and modalities of treatment.

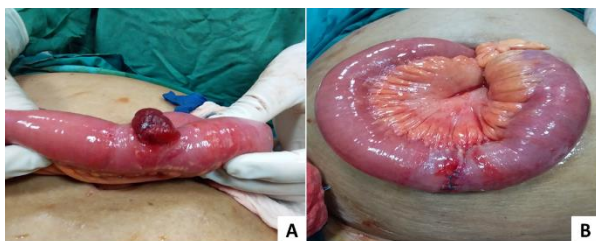
### Case Presentation

We report a 60-year-old female patient presented to our Emergency Department complaining of reducible paraumbilical swelling for two years yet, it became tender irreducible for one day earlier associated with absolute constipation and persistent vomiting. She had no medical

comorbidity or previous abdominal surgery. On examination the patient had a low-grade fever but was hemodynamically stable, the swelling was about 3 cm in diameter, tense, tender with no impulse on cough with distorted umbilicus. The abdomen was distended with audible hyperperistalsis on auscultation. Laboratory investigation showed leukocytosis with normal serum creatinine and potassium level, plain radiograph abdomen erect position was done revealing multiple air fluid level. Nasogastric tube was inserted draining intestinal fluid, resuscitation with i.v. fluids, electrolytes and antibiotics was done.

Decision was made to proceed to surgical intervention, transverse incision was made on the hernia site with dissection of overlying layers. The toxic fluid was drained, part of the circumference of ileal bowel loop was entrapped with ischemic changes <50% at antemesenteric border with rupture of subserosal tissue (Figure 1A), trimming of the disrupted subserosal tissue with invagination through serosal suture using vicryl 3/0 was made (Figure 1B). Closure of the defect with mayo repair was done. The patient started oral fluid at the 3rd postoperative day and discharged on the 4th postoperative day, follow up visit at six months later was uneventful with no recurrence.

\*Correspondence to: Khaled Ahmed Ahmed, General Surgery Department, Alexandria Main University Hospital, Alexandria, Egypt; E-mail: [k\\_Ahmed14@alexmed.edu.eg](mailto:k_Ahmed14@alexmed.edu.eg)



**Figure 1:** Intraoperative images of paraumbilical Richter hernia.

**A)** Ischemia of the entrapped bowel limited at antemesenteric border <50%, with rupture of the subserosal tissues.

**B)** Excision of the ruptured tissues and invagination with serosal interrupted suture using vicryl 3/0.

## Discussion

Richter hernia is a peculiar type of enterocele, in which part of the circumference of bowel loop entrapped in the sac through a defect. It was described for the first time by Fabricius Hildanus in 15983, but it was given the name later by August Gottlieb Richter [3, 4]. The condition usually occurs in elderly female despite no age nor gender is immune especially after popularity of laparoscopic surgery. Any gastrointestinal organ may be in the content of Richter hernia but, the commonest is distal ileum in majority of cases. Based on the fact stated by Richter that the defect of this particular hernia must be small enough to prevent passage of entire bowel loop with a firm edges, Richter hernia occurs mostly at femoral ring (71%), deep inguinal ring (23%), with the least incidence at ventral hernia (6%) also port sites of laparoscopic surgery became a common site for such type of hernia [2, 5].

Therefore, we faced a Richter hernia at uncommon site as, ventral hernias are usually of a large defect permitting passage of entire bowel loops and omentum with a less sharp edges. Richter hernia has wide spectrum of presentation, it presents as a swelling of different sizes even may be unnoticed, it may be associated with nausea and abdominal pain. Symptoms and signs of intestinal obstruction depends on the part entrapped from circumference of bowel wall, as it occurs with the entrapment of about 2/3 of the circumference. Progression into strangulation and ischemia present generally as fever and tense tender hernia with redness of overlying skin, it is a common complication of Richter hernia especially when associated with normal flow of intestinal content without obstruction, as this delay the diagnosis leading to gangrene and may be perforation with enterocutaneous fistula [2].

Despite, in our case the patient suffered from intestinal obstruction which helped in early seeking medical advice and prevented further perforation and fistula. Diagnosis of Richter hernia is never difficult, as usually made by CT scan of the abdomen, or intraoperatively when CT scan was not done preoperatively like in our case scenario [1]. Also, it may be detected by CT Fistulogram in cases presented with just fistulous opening draining intestinal content of the entrapped bowel loop [2]. Management of Richter hernia differs according to condition of the entrapped bowel, as just application of packs soaked in warm saline is the sole treatment if the bowel is viable. On the other hand, if the bowel is perforated it essentially needs resection of this segment with anastomosis.

Dilemma is usually in case of ischemic bowel without perforation, as if the ischemia is >50% or the mesentery is affected this segment should be resected, while if ischemia is < 50% or limited at antemesenteric border invagination of the affected part under serosal suture is the best management as in our case scenario [1]. Repair of the defect is mandatory to prevent recurrence but, mesh placement is controversial. Mesh repair in most studies were done in case of no ischemia, while were avoided in setting where infection may occur as in ischemic or perforated bowel [2]. In our case we preferred not to do mesh repair due to ischemic bowel with some toxic fluid in the sac which may increase the risk of infection.

## Conclusion

Richter hernia can occur in ventral hernias, usually at elderly female patients. Obstructed hernia does not rule out being a Richter one. Diagnosis is made by CT scan or intraoperatively once explored. Management of ischemic loop in Richter hernia does not necessitate resection and anastomosis, as if ischemia is limited at antemesenteric border invagination only is enough. Repair of the defect is mandatory while mesh placement is conditional.

## Conflicts of Interest

All authors declare no conflict of interest.

## Consent

Consent of the patient for publishing was obtained.

## Ethical Committee

The report was approved by ethical committee of Alexandria faculty of medicine.

## Author's Contribution

Khaled Ahmed: analysis & interpretation of data, reviewing related literature, writing manuscript.

Ahmed Abo-elmagd: collecting of data, drafting manuscript, revision of the manuscript.

All authors read and approved the final manuscript for publication.

## REFERENCES

1. Martis JJ, Rajeshwara K, Shridhar MK, Janardhanan D, Sudarshan S (2011) Strangulated Richter's umbilical hernia-a case report. *Indian Journal of Surgery* 73: 455-457. [[Crossref](#)]
2. Chen W, Liu L, Huang H, Jiang M, Zhang T (2017) A case report of spontaneous umbilical enterocutaneous fistula resulting from an incarcerated Richter's hernia, with a brief literature review. *BMC surgery* 17: 15. [[Crossref](#)]
3. Steinke W, Zellweger R (2000) Richter's hernia and Sir Frederick Treves: an original clinical experience, review, and historical overview. *Ann sur* 232: 710-718. [[Crossref](#)]

- 
4. Rutkow IM (2003) A selective history of hernia surgery in the late eighteenth century: the treatises of Percivall Pott, Jean Louis Petit, D. August Gottlieb Richter, Don Antonio de Gimbernat, and Pieter Camper. *Surg Clin North Am* 83: 1021-1044. [[Crossref](#)]
  5. Sreeramulu P, Shetty NS (2012) *Open Access Scientific Reports*.