

Available online at www.sciencerepository.org

Science Repository



Case Report

Synovial chondromatosis masquerading as a para-meniscal cyst of the knee

Karthikeyan P Iyengar^{1*}, Chary Duraikannu², R George Brice³, Michael Greenhalgh⁴ and R F Adam⁵

¹Trauma & Orthopaedic Surgeon, Southport & Ormskirk Hospital NHS Trust, UK

²Consultant Radiologist, Southport & Ormskirk Hospital NHS Trust, UK

³Consultant Histopathologist, St. Helens and Knowsley Teaching Hospitals NHS, UK

⁴Core Surgical Trainee Orthopaedics, Southport & Ormskirk Hospital NHS Trust, UK

⁵Consultant Orthopaedic Surgeon, Southport & Ormskirk Hospital NHS Trust, UK

ARTICLE INFO

Article history:

Received: 9 May, 2019

Accepted: 5 July, 2019

Published: 23 July, 2019

Keywords:

Knee

synovial chondromatosis

para meniscal cyst

magnetic Resonance Imaging

knee arthroscopy

ABSTRACT

Synovial chondromatosis and parameniscal cysts are well documented pathologies around the knee joint. We present an unusual presentation of synovial chondromatosis masquerading as a parameniscal cyst of the knee. The patient was an 82-year old gentleman seen in our knee clinic with painful swelling over medial aspect of the right knee, no history of injury and with symptoms of a locked knee. Clinico-radiological features were suggestive of a binary pathology of a meniscal tear and multi-locular cyst of the knee. An arthroscopic assisted open excision of the cystic lesion allowed clinical recovery with histological confirmation of benign synovial chondromatosis.

We highlight the challenges in our case with the overlap of diagnostic features of both synovial and meniscal pathology with surgical management of this patient.

© 2019 Karthikeyan P Iyengar. Hosting by Science Repository.

Introduction

Synovial chondromatosis is a benign proliferative disease of the synovium associated with cartilaginous metaplasia resulting in multiple intra-articular loose bodies [1, 2]. It is usually monoarticular and commonly affects the knee, hip, elbow or shoulder joints. The knee is affected in > 50% of cases and patients present with symptoms of chronic swelling, pain and spontaneous locking due to intra-articular loose bodies [3, 4]. First described by Nicaise (1883) parameniscal cysts originating from the lateral meniscus are reported 3 to 10 times more commonly than originating from the medial meniscus [5]. Usually associated with an underlying meniscal tear, they can vary in their presentation [6]. Plain radiographs undertaken may show non-specific features and Magnetic Resonance Imaging (MRI) is the diagnostic modality of choice in both of these pathologies. Imaging plays a vital role in diagnosing these two conditions and for pre-surgical planning. However, occasionally there could be an overlap of imaging findings which presents a diagnostic dilemma [7, 8]. We highlight an interesting presentation of an extra-articular symptomatic synovial chondromatosis,

confirmed on histopathology which clinically presented as a parameniscal cyst. We managed to treat this binary pathology with a combined arthroscopic assisted open excision of the lesion.

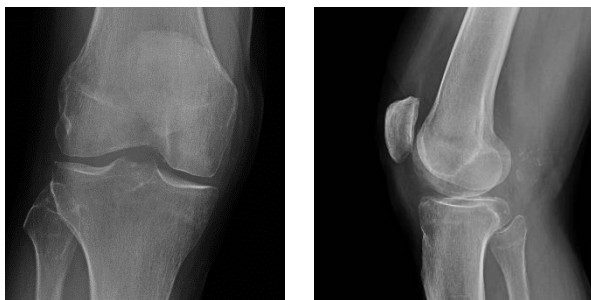Case description

An 82-year-old gentleman was seen in our knee clinic with a 12 month history of painful swelling over medial aspect of his right knee with no history of injury. The pain increased while descending stairs and he was unable to squat. His background included a history of ischaemic heart disease and he used glyceryl trinitrate spray occasionally. Examination revealed a locked right knee in 15° of flexion. A firm, slightly tender swelling of size of a lemon was palpable on the medial aspect of knee with medial joint line tenderness. McMurray's test was painful for the medial meniscus. The knee was locked at 15° with further flexion possible from 15° to 100° of flexion. The knee joint was stable without ligamentous instability.

Plain radiographs revealed soft tissue swelling on medial and posterior aspect of the knee with some scattered calcifications (Figure 1a and 1b).

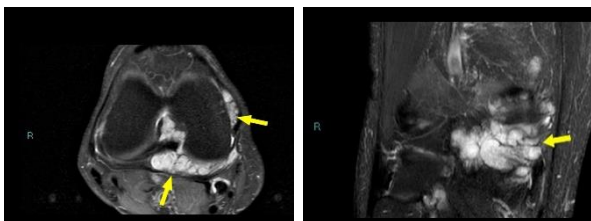
*Correspondence to: Karthikeyan P Iyengar, Trauma & Orthopaedic Surgeon, Southport & Ormskirk Hospital NHS Trust, UK; E-mail: kiyengar@nhs.net

Magnetic Resonance Imaging (MRI) of the right knee revealed a horizontal cleavage degenerate tear of the posterior horn of the medial meniscus. There was a moderate sized multilobulated T1 hypo intense and T2 hyper intense parameniscal cyst like lesion in posteromedial aspect of joint space extending to the intercondylar region measuring approximately 40 x 42 x 15mm and in close proximity to the posterior horn of the medial meniscus (Figure 2a and 2b). There were no intra-articular loose bodies.



1a 1b

Figure 1a and 1b: Plain anteroposterior and lateral right knee radiograph showing mild soft tissue swelling in the medial and posterior aspect of knee with some calcific densities.



2a 2b

Figure 2a and 2b: Axial and coronal Proton Density Fat Saturation (PDFS) MRI shows multilobulated hyper intense lesion (yellow arrows) in posteromedial aspect of knee joint space extending to intercondylar region.

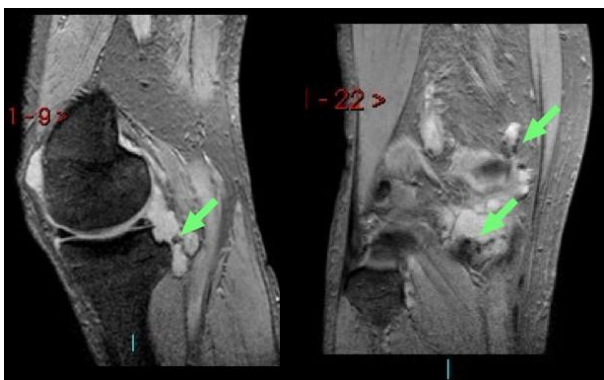


Figure 3a and 3b: Sagittal and coronal T2 Fast Field Echo (FFE) MRI shows small hypo intense foci scattered within the lesion suggesting calcifications (green arrows).

There was focal scalloping of posterior cortex of proximal medial tibia seen adjoining the lesion. Few scattered small T2 hypo intense foci were visible within the lesion suggesting calcification (Figure 3a and 3b). Although the presence of calcification and cortical scalloping favored a diagnosis of synovial chondromatosis, the multilobulated appearance

and its close proximity to the medial meniscus suggested differential diagnosis of a parameniscal cyst. A high signal in the posterior horn of the medial meniscus suggestive of tear and close proximity of the intra-articular lesion with the meniscus was noted (Figure 4a and 4b).

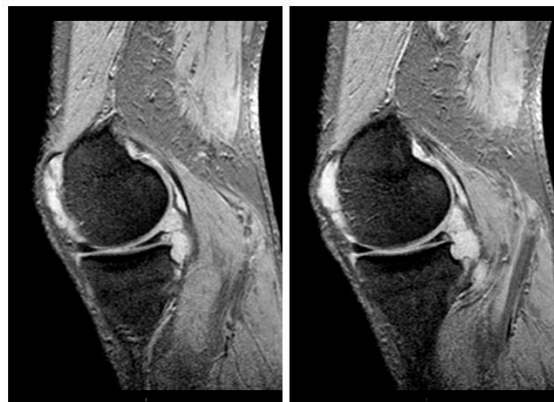

Figure 4a and 4b: MRI Sagittal T2 shows abnormal focal T2 hyper intense signal in posterior horn of medial meniscus suggestive of tear. Also note the close proximity of the intra articular lesion with the meniscus.

The patient underwent arthroscopic debridement of the degenerate medial meniscal tear. The swelling on the medial aspect of the knee was excised using a medial longitudinal incision, dissecting down to the base with careful capsular closure over the meniscal defect. The specimen sent for histology. The patient was discharged from the hospital with an unlocked knee and full weight bearing mobilization. The stitches were removed at two weeks at the follow-up clinic and he made an uneventful recovery. Initial histological examination reported fragments of pale cartilaginous and fibrous connective tissue with features of atypical chondroid neoplasm. A specialist opinion was sought from the regional soft tissue tumour unit and cellular pathologist.

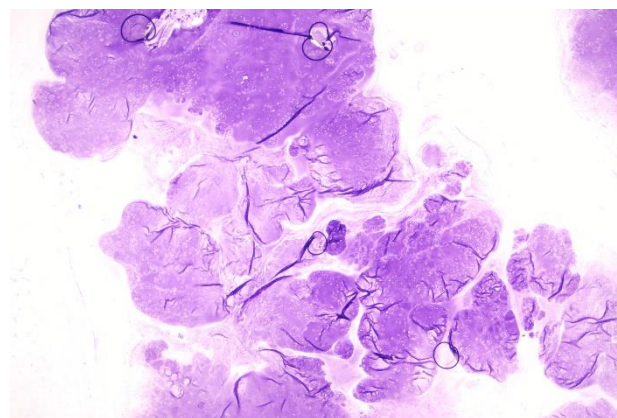


Figure 5: Low power photomicrograph shows lesion composed of discrete nodules of mature hyaline cartilage.

The cytology report revealed features of synovial tissue with multiple nodules of hyaline cartilage of variable size. The cartilage was of low-moderate cellularity with a few binucleate cells. No mitoses were identified and there was no necrosis (Figure 5, 6 and 7). The appearances were consistent with synovial chondromatosis. The Multidisciplinary team meeting confirmed the benign nature of the swelling and this was

conveyed to our patient for reassurance.

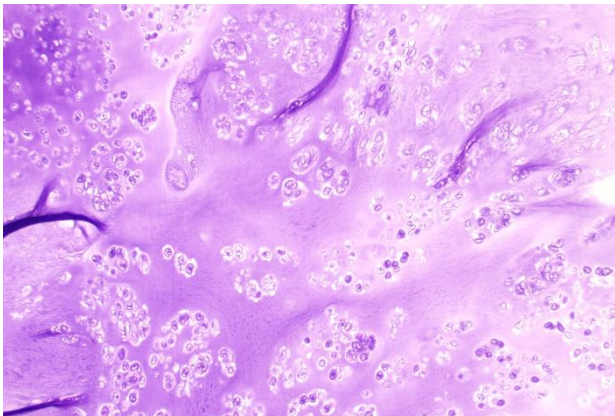


Figure 6: Medium power photomicrograph shows the variable cellularity of the cartilage, ranging from low to moderate.

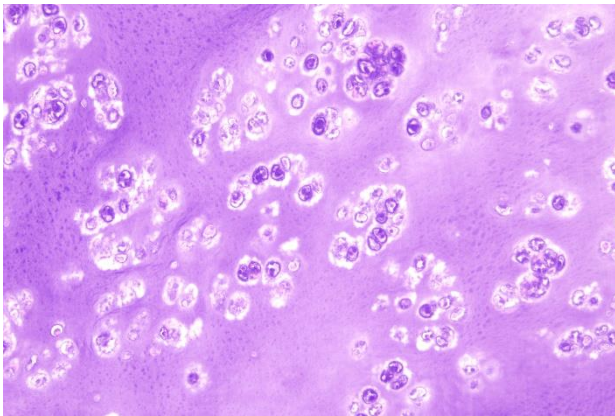


Figure 7: The high power photomicrograph highlights atypical chondrocytes, occasional binucleate cells, occasional mitoses but no necrosis.

Discussion

Synovial chondromatosis and parameniscal cysts are well documented pathologies around the knee joint [4, 5]. The challenge in our case was the overlap of diagnostic features of both synovial and meniscal pathology, with the histopathology confirming the former. Synovial chondromatosis is a rare, benign proliferative condition of the synovial lining of joints, synovial sheaths and bursae. Predominantly associated with cartilaginous metaplasia of the synovium; the process goes through phases resulting in the formation of characteristic loose bodies and classically affecting the knee [4].

Parameniscal cysts of the knee are located along the peripheral margins of the meniscus and 3 to 10 times more commonly associated with lateral meniscus than the medial side. [7]. Medial parameniscal cysts are almost always associated (98%) with underlying horizontal cleavage meniscal tears and hence more likely to be symptomatic. Aetio-pathologically medial parameniscal cysts often tend to be larger permeating through the extrusion of the synovial fluid and forming a swelling at the meniscocapsular around the medial collateral ligament of the knee [6]. Patients with synovial chondromatosis typically presents with swelling, pain and feature of locking secondary to intra-articular cartilaginous loose bodies

[4]. Parameniscal cysts on the other hand typically present with features of swelling, pain and locked knee secondary to commonly associated meniscal tears [6].

Clinically findings of a medial knee swelling with features of a locked knee led us to suspect a parameniscal cyst and we undertook further investigations. Plain radiographs may reveal soft tissue swelling in parameniscal cysts or characteristic features of scattered calcification with synovial chondromatosis depending on the stage of the disease [4, 6, 7, 8]. Magnetic Resonance Imaging [MRI]; however is the diagnostic modality of choice in assessing both of these pathologies with superior soft tissue contrast [4]. In diagnosing meniscal cysts, MRI can provide information about anatomy, size, location and concomitant intra-articular pathologies such as meniscal tears [6, 7]. MRI in synovial chondromatosis of the knee allows the ability to pick up cartilage nodules in the initial stages of the disease and 'pop-corn' appearance consistent with calcification in the later stages [4, 8].

As described by Kramer et al, primary synovial osteochondromatosis has three distinct MRI appearances [9]. The most common pattern is a lobulated homogeneous T1 isointense and T2 hyper intense intra articular lesion with focal areas of low signal corresponding to calcification. The next common pattern is similar to the previous one, but without any low signal or calcifications. The third less common pattern had features of the previous types and in addition showed findings of enchondral ossification which is better appreciated in radiograph and Computerized Tomography (CT). Although in our case there were features of synovial pathology like lobulated T2 hyper intense lesion with some calcifications and bone scalloping; the proximity of the lesion to the medial meniscal with a suspicion of tear in posterior horn included a differential of parameniscal cyst.

Management of both of these conditions when symptomatic is essentially surgical. Open, arthroscopic or a combination of both procedures can be undertaken to treat synovial chondromatosis and meniscal cysts of the knee [3, 4, 5, 6, 10, 11]. Synovectomy has shown to give better results as compared to loose body removal alone in synovial chondromatosis [10]. In treating parameniscal cysts arthroscopic meniscectomy with simultaneous open cystectomy is preferred than simple arthroscopic decompression and shown to reduce incidence of recurrence [12]. It allows surgical clearance of the lesion from the base and histological evaluation of the tissue. This was particularly relevant in our case, since an unusual presentation of synovial chondromatosis as a solitary, predominantly extra-articular parameniscal cyst could be confirmed with cytology. The differential diagnosis of similar soft tissue masses around the knee should include synovial cyst, ganglion cyst, cystic benign and malignant neoplasms such as synovial sarcoma [4, 6]. Histopathology is of particular importance since it helps to conclusively provide a diagnosis and analyses benign or malignant nature of the lesion. In fact; radiology and histology both help in accurately differentiate amongst them.

Conclusion

An unusual presentation of synovial chondromatosis mimicking as a parameniscal cyst of the knee is reported here and should be considered in differential diagnosis of soft tissue pathologies around the knee. A

combined clinico-radiological, surgical excision and histopathological correlation is essential in evaluating these lesions so they are not over diagnosed as chondrosarcomas.

Conflicts of Interest

None

Funding

None

Ethical approval

Consent was obtained from the patient using an appropriate form. The patient's details have been kept anonymous in the manuscript.

Author contributions

Mr. Karthikeyan Iyengar – 1st Author of case report, performed the operation, obtained consent, involved in writing 1st draft of case report, literature search.

Dr. Chary Duraikannu – 2nd Author of case report, gave radiological expertise.

Dr R George Brice – 3rd Author of case report – involved in 2nd draft of case report and histopathology expertise.

Dr Michael Greenhalgh- 4th author–made initial draft, collected complimentary information

Mr R F Adam – Supervising Orthopaedic Consultant, performed the operation, reviewed 2nd draft of case report.

REFERENCES

1. Maurice H, Crone M, Watt I (1988) Synovial chondromatosis. *J Bone Joint Surg Br* 70: 807-811. [[Crossref](#)]
2. Miligram JW (1977) Synovial osteochondromatosis: a histopathological study of thirty cases. *J Bone Joint Surg* 59: 792-801. [[Crossref](#)]
3. Serbest S, Tiftikçi U, Karaaslan F, Tosun HB, Sevinç HF et al. (2015) A neglected case of giant synovial chondromatosis in knee joint. *Pan Afr Med J* 22: 5. [[Crossref](#)]
4. Kukreja S (2013) A Case Report of Synovial Chondromatosis of the Knee Joint arising from the Marginal Synovium. *J Orthop Case Rep* 3: 7-10. [[Crossref](#)]
5. Kurian J, Schindler OS, Hussain A (2003) Medial meniscal cyst of the knee--an unusual presentation: a case report. *J Orthop Surg (Hong Kong)* 11: 234-236. [[Crossref](#)]
6. Kose O, Erol B, Ozyurek S, Ege T (2013) A giant medial parameniscal cyst of the knee joint. *BMJ Case Rep* 2013. [[Crossref](#)]
7. Campbell SE, Sanders TG, Morrison WB (2001) MR imaging of meniscal cysts: incidence, location, and clinical significance. *Am J Roentgenol* 177: 409-413. [[Crossref](#)]
8. Frick MA, Wenger DE, Adkins M (2007) MR imaging of synovial transformation in synovial chondromatosis of the knee: an update. *Radiol Clin North Am* 45: 1017-1031.
9. Kramer J, Recht M, Deely DM, Schweitzer M, Pathria MN et al. (1993) MR appearance of idiopathic synovial osteochondromatosis. *J Comput Assist Tomogr* 17: 772-776. [[Crossref](#)]
10. Ogilvie-Harris DJ, Saleh K (1994) Generalized synovial chondromatosis of the knee: a comparison of removal of the loose bodies alone with arthroscopic synovectomy. *Arthroscopy* 10: 166-170. [[Crossref](#)]
11. Choi EH, Huang J, Bryk D, Bryk E (2009) Giant medial parameniscal cyst in an osteoarthritic knee. *Orthopedics* 32. [[Crossref](#)]
12. Chang JJ, Li YH, Lin GM, Wu CC, Shen HC et al. (2016) Comparison of the recurrence risk of parameniscal cysts between patients treated with arthroscopic excision and arthroscopic decompression techniques. *Knee Surg Sports Traumatol Arthrosc* 24: 1547-1554. [[Crossref](#)]