

Available online at [www.sciencerepository.org](http://www.sciencerepository.org)

Science Repository



## Case Report

# Two Piece Inflation Penile Prosthesis Surgery: Operative Steps

Priyeshkumar Patel<sup>1</sup>, R. B. Nerli<sup>1\*</sup>, Shridhar C. Ghagane<sup>2</sup>, Pulkit Gupta<sup>1</sup>, Shashank Patil<sup>1</sup> and Neeraj S. Dixit<sup>2</sup>

<sup>1</sup>Department of Urology, JN Medical College, KLE Academy of Higher Education & Research, JNMC Campus, Belagavi, Karnataka, India

<sup>2</sup>Department of Urology, KLES Kidney Foundation, KLES Dr. Prabhakar Kore Hospital & Medical Research Centre, Nehru Nagar, Belagavi, Karnataka, India

### ARTICLE INFO

#### Article history:

Received: 17 February, 2021

Accepted: 1 April, 2021

Published: 13 April, 2021

#### Keywords:

Two-piece inflatable penile prosthesis  
erectile dysfunction

### ABSTRACT

The placement of a penile prosthesis has been considered the most reliable and effective treatment for erectile dysfunction in men with failed medical treatment. The 2-piece system eliminates a need for separate reservoir making the surgery easy for the treating surgeon/urologist. We report the use of this two-piece prosthesis in a 50-year-old patient with erectile dysfunction and describe the surgical steps of the same.

© 2021 R. B. Nerli. Hosting by Science Repository.

## Introduction

Use of penile prostheses has been an option in the treatment of erectile dysfunction (ED) since the mid-1970s [1, 2]. Approximately 20,000 penile prosthetic devices are implanted annually in the United States, accounting for 75% of the global market [3, 4]. The primary goal is to restore erections that closely resemble normal function like rigidity, girth expansion, and length expansion. We all know that ED is often associated with mental disturbances like feelings of inadequacy, disappointment, and loss of self-confidence. Prosthetic implants are the most effective means for obtaining an artificial erection in patients with ED who are not responding to medications, intra-corporeal injections or tolerate other treatment options [5]. The additional goal of implant surgery is to improve the patient's quality of life and self-esteem [6, 7].

Two broad categories of penile implants exist as of today namely, the semi-rigid rods and inflatable devices. Whichever device be used, they achieve mainly penile rigidity, but with a few differences in cosmetic appearance and flaccidity. The selection of the device depends on various factors i.e., the surgeon's experience, insurance coverage or affordability, and patient's preference. Inflatable prostheses are designed to function in such a manner that it can permitting girth and length expansion during erection and penile flaccidity when not in use. Inflatable devices are made of two hollow intra-corporeal cylinders, each

of which fill a corpus cavernosum. The cylinders are inflated with saline solution to produce penile rigidity during sexual activity and can be deflated after intercourse.

The two-piece penile prosthesis (AMS Ambicor™ American Medical systems) is a closed, fluid-filled system consisting of a pair of cylinders, and a pump which needs to be implanted in the scrotum. The inflation pump placed in the scrotum is easy for the patient to locate and with a few squeezes inflates the device by displacing a large amount of fluid. To deflate the device, the patient has to simply bend the penis towards the scrotum and hold in the position for 6-12 seconds. We report the use of this two-piece prosthesis in a 50-year-old patient with ED and describe the surgical steps of the same.

## Case Report

A 50-year-old married male presented with symptoms of erectile dysfunction of several months duration. The patient was evaluated and counselled for oral sildenafil. The patient did not get adequate erection so as to have intercourse. Following prolonged failed attempts with several 5 alpha reductase inhibitors the patient was counselled for a penile prosthesis. The couple were counselled for the surgery and a detailed explanation of the outcomes and complications were discussed in detail.

\*Correspondence to: Dr. R. B. Nerli, Department of Urology, JN Medical College, KLE Academy of Higher Education & Research, JNMC Campus, Belagavi, 590010, Karnataka, India; Tel: +919886616317; E-mail: rbnerli@gmail.com

## I Preoperative Setting-Up of Materials

Instruments that are normally required for a urological surgical procedure need to be kept. In addition to the penile prosthesis, the following instruments are also necessary, such as Keith needles, corporal length measuring tool, Furlow insertion tool for passing traction sutures through glans, corporal dilators, and antibiotic solution for irrigation.

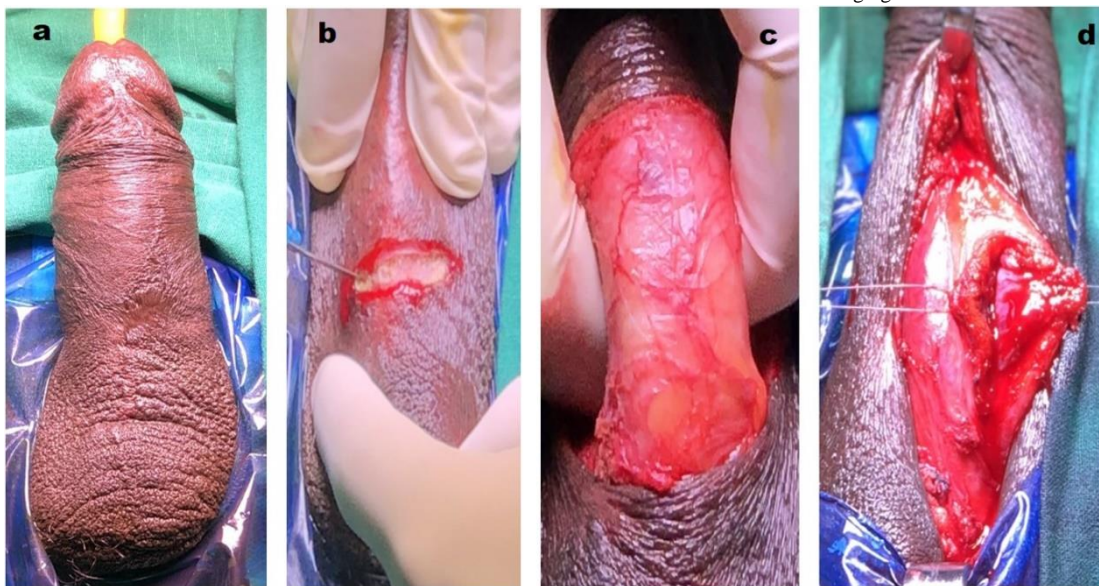
## II Patient Preparation

Adequate steps must be taken preoperatively to limit the risk of post-operative infection. Patient is shaved in the operating room; the abdominal and genital area should be scrubbed with povidone-iodine soap for ten minutes. The surgical area is painted and draped as per the

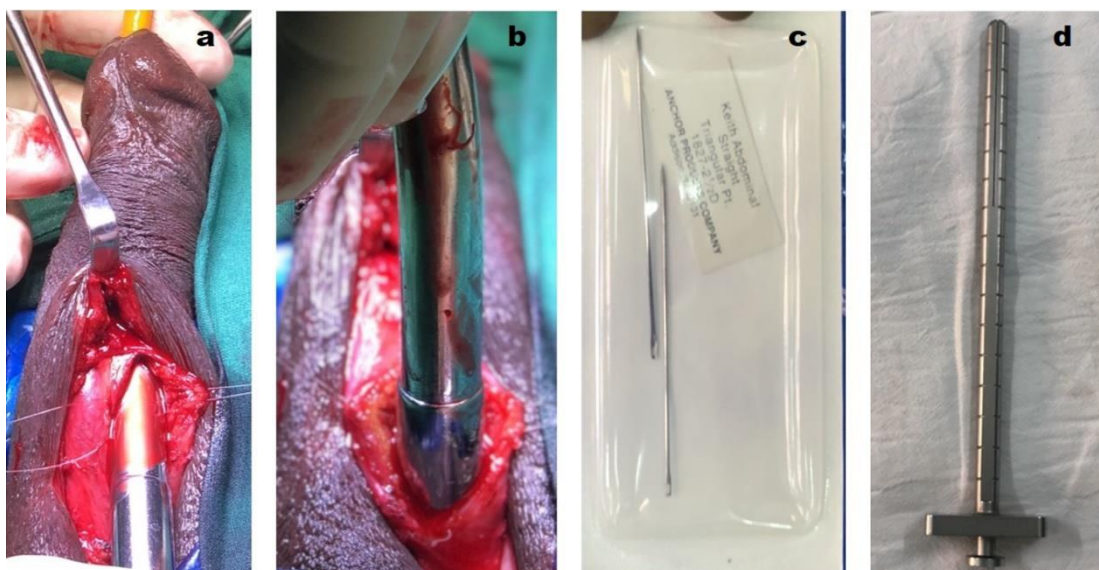
surgeon's need. Throughout the procedure, the surgical site should be flushed with copious amounts of broad- spectrum antibiotics.

## III Surgical Procedure

The patient is positioned for a penoscrotal surgical approach. The penoscrotal approach leaves the incision well-hidden and provides convenient access to the corpora cavernosa. Foley catheter is introduced so as to facilitate identification of the urethra (Figure 1a). A good retractor system can be used to place the penis on 'stretch' so as to provide adequate exposure of the corpora. A 2 cm to 3 cm incision is made through the median raphe of the scrotum at the penoscrotal junction (Figure 1b). Some surgeons may prefer a high scrotal incision for better proximal corporal access. The corpus spongiosum is laterally retracted so as to avoid damaging the urethra.



**Figure 1:** a) Foleys catheter is inserted. b) Penoscrotal incision made. c) Bucks fascia dissected. d) incision made on corpora.



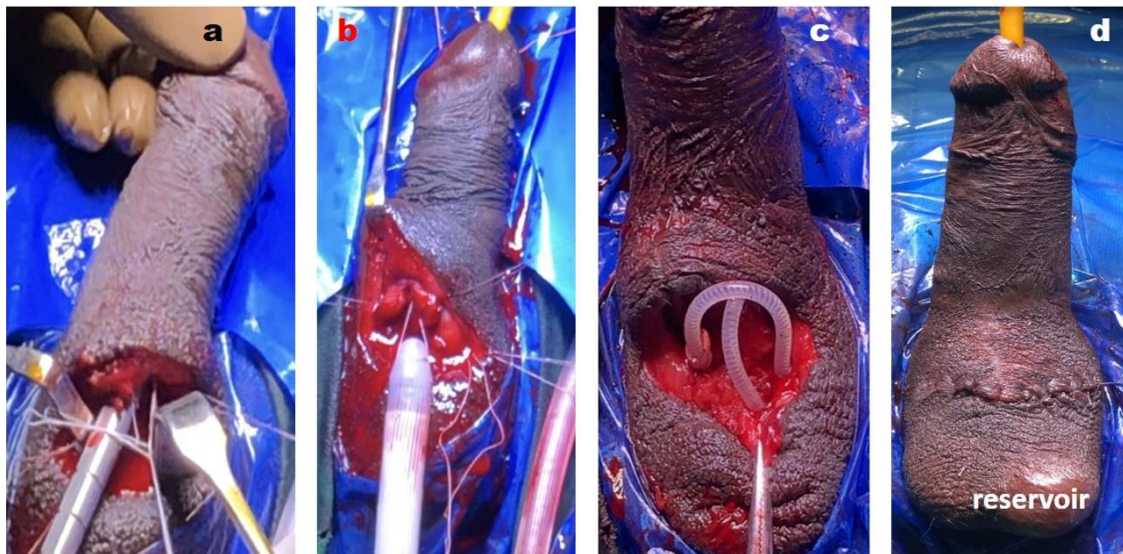
**Figure 2:** a) The corpora dilated distally. b) Corpora dilated proximally. c) Keith needle. d) Furlow insertion tool.

The Buck's fascia (Figure 1c) is dissected so as to expose the tunica albuginea. Stay sutures are placed so as to use as a reference point while

measuring the corpora. Then an incision is made into one of the corpora cavernosa (Figure 1d). The proximal corpus (crus) and the distal corpus

are dilated to create a space for inserting the penile cylinder. The corpus cavernosum is dilated up to 13-16 mm (Figures 2a & 2b). Similarly, the opposite corpus cavernosum is incised and dilated. The correct sized cylinders and rear tip extenders are chosen so as to fit the patient's anatomy. Each corpus is measured proximally and distally using the Furlow Insertion Tool or an appropriate measuring device (Figure 2d). As a general rule, the corporotomy is best placed at a site that lies at a point wherein two-thirds of the total corporal measurement is distal to the incision and one-third is proximal. This facilitates the proper placement of the cylinders and avoids the need to extend the corporotomy during the procedure.

The Furlow Insertion Tool should be used when inserting the cylinder distally and to put the penis on mild stretch. The tool should be palpable beneath the glans. The thread that is attached to the front of the cylinder is threaded through a Keith needle (Figure 2c). The Keith needle is inserted into the Furlow insertion device. The Furlow insertion tool is inserted distally into the corpora cavernosa and the needle is passed through the glans. The cylinders are inflated (Figure 3a) and the proximal end is inserted into the corpora. The cylinders are deflated (Figure 3b) by bending both the cylinders evenly to 55-65 degrees and holding them in that position for 6-12 seconds. The distal end is positioned by using the traction sutures. Once both cylinders are implanted, the tunica albuginea is closed (Figure 3c).



**Figure 3:** a) Keith needle inserted onto Furlow insertion tool and this assembly passed through the corpora to come out of the glans. b) The cylinders inserted into the corpora. c) The reservoir placed in the dependent position of the scrotum. d) The wound closed in layers.

Blunt dissection is used to create a pocket in the lateral and dependent portion of the scrotum. The pump is inserted into the scrotal pocket (Figure 3d). The tubing between the pump and cylinders should not be palpable. After both the cylinders and pump are implanted, the function of the prosthesis is checked by inflating and deflating the device. The dartos is closed in two layers using a running 2-0 absorbable suture. The dressing is applied to the wound and a drain may be placed if necessary, for 12-24 hours.

#### IV Post-Operative Care

After 24 hours, the dressing is removed, and the cylinders are completely deflated. The penis is supported on the abdomen for four to six weeks so as to obtain a straight erection. Taping the penis to the abdomen is usually the right procedure.

#### V Evaluating Long-Term Function

After the postoperative healing period, the surgeon should follow-up with the patient at least on an annual basis so as to evaluate the function of the device. During the annual evaluation, the patient is asked as to how the device was functioning and if he had noticed any changes in the function, for example, the cylinders losing rigidity. Also check the patient for signs of infection or erosion.

#### Discussion

The two-piece penile prosthesis device consists of the two cylinders and a scrotal pump. The reservoir in the proximal portion of the cylinders is prefilled with saline and preconnected to the pump via silicone tubing. As a separate reservoir is eliminated, this two-piece prosthesis provides certain advantages for both the patient and surgeon. The pump transfers fluid from the built-in reservoirs in the proximal aspect of the cylinders to the inflatable, more distal, portion of the cylinders.

The advantage of a two-piece device is that there is no need to implant a separate reservoir, thus facilitating the surgery for the urologist and may be also useful with patients in whom placement of the reservoir is extremely difficult because of colostomy, ileostomy, kidney transplant, or extensive pelvic surgery. A patient with limited manual dexterity because of age, thick fingers, or neurologic disease benefits from a two-piece prosthesis [8]. A two-piece device reaches full inflation with fewer squeezes of the pump. However, as the pump is very small and hard, it makes it difficult for patients to manipulate.

Lux *et al.* published in 2007 the largest series describing outcomes and satisfaction rates among Ambicor recipients [9]. A total of 146 men from two medical centers received the redesigned 2-piece penile prosthesis. They reported a 0.7% infection rate and a 0.7% mechanical failure rate

with a relatively short mean follow-up of 38 months. 95% of patients had little or no trouble learning how to use the prosthesis and 84% of patients stated that the prosthesis provided good to excellent rigidity for coitus. Patient and partner satisfaction rates also were noted to be high at 85% and 76%, respectively.

Gentile *et al.* found that patients older than 65 years were more satisfied with their two-piece prosthesis than younger patients [10]. In their series of 42 patients, all patients older than 65 were very or mostly satisfied with their implant compared with men younger than 65, of whom only 70% felt the same way. They proposed that within their patient population, the older man might have lower expectations and therefore be more easily pleased than a younger man. In an appropriately selected patient, the 2-piece penile prosthesis is a reliable, user-friendly prosthesis with high patient and partner satisfaction rates.

### Conclusion

The advantage of a two-piece device is that there is no need to implant a separate reservoir, thus facilitating the surgery for the urologist and may be also useful with patients in whom placement of the reservoir is extremely difficult. In an appropriately selected patient, the 2-piece penile prosthesis is a reliable, user-friendly prosthesis with high patient and partner satisfaction rates.

### Funding

None.

### Conflicts of Interest

None.

## REFERENCES

1. Scott FB, Bradley WE, Timm GW (1973) Management of erectile impotence: use of implantable inflatable prosthesis. *Urology* 2: 80-82. [[Crossref](#)]
2. Nerli R, Dixit N, Ghagane S (2016) Erectile dysfunction and diabetes mellitus. *J Sci Soc* 43: 1-2.
3. Small MP, Carrion HM, Gordon JA (1975) Small-Carrion penile prosthesis: new implant for management of impotence. *Urology* 5: 479-486. [[Crossref](#)]
4. Mulcahy JJ, Wilson SK (2006) Current use of penile implants in erectile dysfunction. *Curr Urol Rep* 7: 485-489. [[Crossref](#)]
5. Garber BB (2008) Inflatable penile prostheses for the treatment of erectile dysfunction: an update. *Expert Rev Med Devices* 5: 133-144. [[Crossref](#)]
6. Patil AY, Nerli RB, Dixit NS, Hiremath MB (2018) Satisfaction with the semirigid penile prosthesis among couples from a Semiurban Indian population. *J Sci Soc* 45: 26.
7. Bettocchi C, Palumbo F, Spilotros M, Palazzo S, Saracino GA et al. (2010) Penile prosthesis. *Ther Adv Urol* 2: 35-40. [[Crossref](#)]
8. Levine LA, Estrada CR, Morgentaler A (2001) Mechanical reliability and safety of and patient satisfaction with the Ambicor inflatable penile prosthesis: results of a 2 center study. *J Urol* 166: 932-937. [[Crossref](#)]
9. Lux M, Reyes Vallejo L, Morgentaler A, Levine LA et al. (2007) Outcomes and satisfaction rates for the redesigned 2-piece penile prosthesis. *J Urol* 177: 262-266. [[Crossref](#)]
10. Gentile G, Franceschelli A, Massenio P, Tuccio A, Cocci A et al. (2016) Patient's satisfaction after 2-piece inflatable penile prosthesis implantation: an Italian multicentric study. *Arch Ital Urol Androl* 88: 1-3. [[Crossref](#)]