

Available online at www.sciencerepository.org

Science Repository



Research Article

Outcome Based on Metastatic Humerus and Surgical Fixation: Finding of a Systematic Review

Yi Zhao^{1#}, Qianqian Zhang^{2#}, Hongzeng Wu¹, Jianfa Xu¹, Jianjun Xun¹ and Helin Feng^{1*}

¹Department of Orthopedics, The Fourth Hospital of Hebei Medical University, 12 Health Road, Shijiazhuang, Hebei 050011, P. R. China

²Department of Gynecology, Hebei Medical University Second Affiliated Hospital, 215 Heping Road, Shijiazhuang, Hebei 050011, P.R. China

#These authors contributed equally.

ARTICLE INFO

Article history:

Received: 9 November, 2019

Accepted: 18 December, 2019

Published: 27 December, 2019

Keywords:

Humerus

surgical fixation

meta-analysis

ABSTRACT

Background: As for treating metastatic humerus, open reduction with internal fixation (ORIF), intramedullary nail fixation as well as reconstruction of endoprosthesis act as the approaches with highest frequency in surgeries. In the current study, the postoperative complications and functional outcomes were compared after 3 operating treatments for metastatic humerus by performing a meta-analysis.

Methods: An electronic search of relevant studies was done on December 29, 2015 and rigorously screened them according to inclusion and exclusion criteria. The summary results of the included studies were pooled using a random-effects mode.

Results: A total of 21 studies were included for analysis. we evaluated the functional outcome according to the MSTs score, found that the upper limb function apparently returned after surgery. For local complications, the overall reoperation rate after endoprosthetic reconstruction (95%CI 0.06-0.11) ranged from 0-14%, 0-9% after intramedullary nailing (95%CI 0.04-0.08), and 0-8% after ORIF (95%CI 0.05-0.24). The rate of re-operation for failed fixations ranged from zero to 10% after reconstruction of endoprosthesis (95%CI 0.03-0.07), 0-6% after intramedullary nailing (95%CI 0.01-0.04), and was 0-19% in all studies after ORIF (95%CI 0.02-0.19), while that for dislocations ranged from 0% to 8% after reconstruction of endoprosthesis (95%CI 0.02-0.05), and 0-5% after intramedullary nailing (95%CI 0.01-0.04).

Conclusions: Compared with the high rate of reoperation due to ORIF, those of intramedullary nail fixation and endoprosthetic construction are of comparability. The findings in the current study is applicable for aiding to make appropriately surgical decision to improve the living quality of patients in the remainder of their lives.

© 2019 Helin Feng. Hosting by Science Repository.

Introduction

The humerus is secondary to the femur in long bone site affected by bone metastases, and the proximal and diaphysis are commonly sites [1]. Bone metastases, particularly lytic disease, cause ache and finally broken bones, and the surgery aiming to ameliorate discomfort and restore function are frequently required [2, 3]. The orthopedic surgery including open reduction with internal fixation (ORIF) using screws and plates,

intramedullary nail fixation as well as reconstruction of endoprosthesis and many more approaches is applicable to treating metastatic humerus [4]. The surgical plan is not made by the patient together with their doctors, but also partially dependent on whether to undergo pathological fracture, overall survival, metastasizing sites and sizes, as well as functional outcomes in expectancy and operational complications [5]. Several papers in the literature described that the three most common treatments including ORIF, intramedullary nail fixation as well as

*Correspondence to: Helin Feng, MD, PhD, Department of Orthopedics, The Fourth Hospital of Hebei Medical University, 12 Health Road, Shijiazhuang, Hebei 050011, P. R. China; Tel: 13931859633; E-mail: helinfeng0311@163.com

reconstruction of endoprosthesis are helpful in metastatic humerus [6]. However, relatively few have been reported about postoperative arm recovery, reoperations and complications. And thus, require large cohorts to adequately compare the three most common treatments. The review focuses: (1) to provide an up-to-date report about comparing

outcome among the three surgical strategies, and (2) to clarify the outcome of postoperative arm recovery, the local and systemic complication rate for metastatic humerus.

Table 1: Characteristics of All Patients With Metastatic Humerus Per Study (%).

Author, year	Implant	Patients	humerus	Pathological fractures	Median age	Minimum follow-up ^m	One year survival in (%)
Lewallen RP et al (1982)	IMN	55	55	--	--	--	10M ^a
Capanna R et al (1988)	EPR	20	19	--	--	--	--
Yazawa Y et al (1990)	IMN	166	41	30	62	24	40%
Fuhrmann RA et al (2000)	EPR	22	22	--	57	47 ^a	--
Gebhart, M. et al (2001)	EPR+IMN	56	55	31	62	1	9 ^a
Bickels J et al (2002)	EPR	134	12	--	--	24	--
Bauze AJ, et al (2003)	IMN	31	31	25	67	--	--
Bauze AJ et al (2006)	EPR+IMN	96	77	--	63	8 ^a	43.5%
Thai DM et al (2008)	EPR	154	37	--	59	--	69.5%
Scotti, C. et al (2008)	EPR	40	40	12	67	--	70%
Cannon CP et al (2009)	EPR	83	67	--	55	24	55.8%
Piccioli A et al (2010)	EPR+IMN	85	87	76	59	8.3 ^a	67.3%
Siegel, H.J. et al (2010)	ORIF	32	23	--	52	17.6 ^a	--
Raiss, P. et al (2010)	EPR	43	30	--	60	38 ^a	77% ⁽²⁾
Griffiths, D. et al (2011)	EPR	68	30	--	53	71 ^a	--
Wedin R et al (2012)	EPR+IMN+ORIF	214	204	173	67	8 ^a	40%
Henrichs MP et al (2014)	EPR	82	26	--	63	--	94.7%
Pruksakorn D et al (2015)	EPR+ ORIF	27	27	--	--	16 ^a	91.7%
Janssen SJ et al (2016)	EPR+IMN+ORIF	295	292	237	63	4 ^a	49%
Choi ES et al (2016)	IMN	32	32	21	--	14.2 ^a	48%
Schmolders J et al (2016)	EPR	30	21	--	--	26 ^a	83%

--, not available; EPR, endoprosthesis; IMN, intramedullary nail; ORIF, open reduction internal fixation.

^a Mean age.

^m In months.

Table 2. Functional Outcome Per Implant Type for Metastatic Humerus (%).

Author, year	Implant	Follow-up (Months)	Patients	Outcome measure	Median score (Range)
Scotti, C. et al (2008)	EPR	30	40	MSTS	73.1 ^a (69.9-76.3)
Cannon CP et al (2009)	EPR	24	67	MSTS	63 ^a (40-83)
Piccioli A et al (2010)	EPR	8	26	MSTS	73 ^a
	IMN		57		79 ^a
Raiss, P. et al (2010)	EPR	38	30	MSTS	19 ^a (7-27)
Griffiths, D. et al (2011)	EPR	71	30	MSTS	72.3 ^a (53.3- 100)
Choi ES et al (2016)	IMN	14.2	32	MSTS	27.7 ^a (27.0-28.5)
Pruksakorn D et al (2015)	ERP	16	16	MSTS	33-77
Siegel, H.J. et al (2010)	ORIF	17.6	23	MSTS	94.6 ^a (86-99)

MSTS, musculoskeletal tumor society score; EPR, endoprosthesis; IMN, intramedullary nail; ORIF, open reduction internal fixation.

^a Mean score.

Methods and Materials

Our results were reported in line with the guidelines from the preferred reporting items for PRISMA statement [7].

I Search Strategy

A systematic search was performed in the PubMed, Embase, Clinical Evidence, Up To Date and Cochrane libraries for studies on December 29, 2015 using the search terms: (“metastatic” OR “metastases”) AND (“humerus”) AND (“surgery” OR “surgeries” OR “operatio*” OR “operativ*” OR “surgical*” OR “resection*” OR “intramedull*” OR “osteosynth*” OR “fixation*” OR “arthroplas*” OR “endoprosth*” OR “prosth*”) in all fields without any limitation and yielded 2265 articles (Figure 1). All publications were loaded on to the software of Medical literature King and the ‘find duplicates’ application was performed.

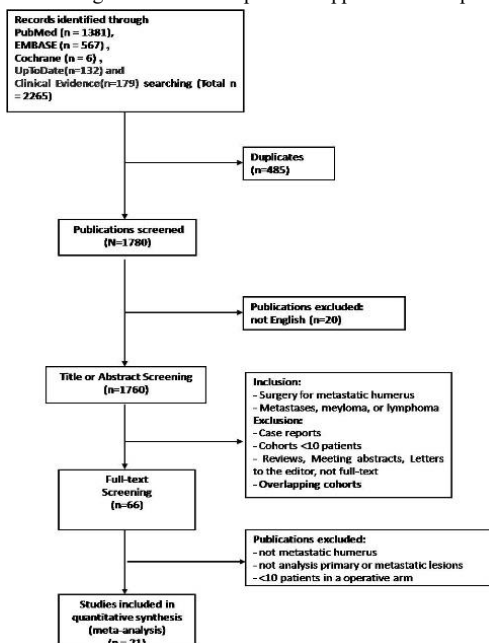


Figure 1: A flow diagram of study selection.

II Inclusion and exclusion criteria

Two reviewers (FHL, WJ) independently reviewed titles and abstracts and subsequently full texts on the basis of predetermined criteria. Disagreements were resolved following assessment by consensus. Inclusion criteria: (i) Studies that described postoperative complication and functional outcomes after treating metastasizing humerus were included. (ii) We included studies reporting on three surgical approaches including ORIF, intramedullary nail fixation as well as reconstruction of endoprosthesis for metastatic proximal humerus. (iii) Only English language studies were included. Exclusion criteria: (i) Meeting abstracts, case report, letters and technique papers were excluded. (ii) Studies including indiscernible treatment arms or unclear regions of metastatic lesion in long bones were also excluded. (iii) We excluded studies with less than 10 patients within surgical approaches. Additionally, authors were contacted if studies within indiscernible reported outcomes or unclear regions of metastatic lesion were published after the year 1985 [8-12]. The qualities of these included researches by predetermined standards-prospective design publicity, bias of loss to follow-up, study of outcomes, basic line, appropriateness standards for selecting patients, comparing treatment arms were independently assessed by two reviewers (FHL, WJ).

III Outcomes of Interest and Data Extraction

We extracted the following information from each articles: the author, year of publication, sample size, median age, sex, surgical techniques, lesions, the mean follow up period, the distribution of primary tumor, quantity of existing and imminent pathological fracture, duration of follow-up and one year survival. In addition, three outcomes of interest were extracted to assess the efficacy of the three surgical techniques.

- Postoperative physical function based on the measure.
- The local complications including reoperation caused by fixation failure (such as: loosened implants, disunion, fractures of implants or near implants), deep infection (including surgical debridement with or without hardware removal) and tumor relapse or progression.

- All proposed general complications whatever the treating outcomes are.

IV Study Characteristics

A total of 21 studies were included for analysis (Figure 1) [2-4, 6, 11-24]. We found that retrospective designs existed in entire researches and 16 (76%) studies included properly standards and approaches of patient selection which resulted in a selection bias. Uncertain methods were present in 9 (43%) studies for comparison of techniques. Only 9 (43%) studies were described more fully for outcome and 8 (38%) studies were considered as having bias resulting from probably elevated loss to follow-up (Figure 2).

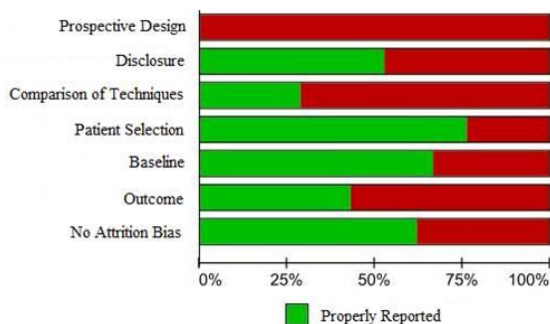


Figure 2: The global qualities of all researches contained in this work and all of which possessed retrospective designs.

V Metastatic Proximal Femoral Fractures and the Features of Patients

The age range of the participants from the entire 21 researches which reported 1228 pathological changes in humerus was 52 to 61 (Table 1). The most common primary tumors included Breast (21.9%), Lung (14.0%), Myeloma and Lymphoma (14.2%) and Kidney (14.3%). The unknown primary tumor type accounted for 15.1% of the cases (Figure 3, Appendix 1). In the 21 studies, there were 15 studies reporting on 455 endoprostheses (418 [91.9%] proximal humerus, 2 [0.4%] Midhumerus, 7 [1.5%] distal humerus and not specified in 28 [6.2%]); 15 studies reporting on 620 intramedullary nails (190 [30.7%] proximal humerus, 278 [44.8%] Midhumerus, 8 [1.3%] distal humerus and not specified in 144 [23.2%]) and 4 studies reporting on 153 ORIFs (53 [34.6%] proximal humerus, 50 [32.7%] Midhumerus, 39 [25.5%] distal humerus and not specified in 11[7.2%]). (Appendix 2).

Results

I Functional Outcome

The endoprosthetic reconstruction was reported on functional outcome for the MSTS score in six studies (209 participants). The range of the mean values of MSTS scores was 19%-73.1% while that of the follow-up duration was 8-71 months. The range of the scores among individuals participating the research was 7%-100% (Table 2).

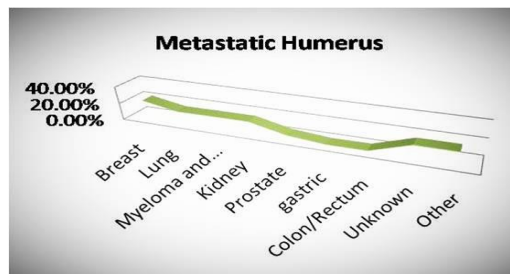


Figure 3: The distribution of primary tumors with data included in appendix two.

Both researches show functional outcome for the scores of MSTS after intramedullary nail fixation. One reported a mean value of 79 among 57 participants after 8 months, while the other reported the value of 27.7 (27.0-28.5) in 32 patients after 14.2 months. One study demonstrated that the average score of MSTS after the 23 patients receiving ORIF was 94.6% ranged from 86% to 99% and the follow-up duration was 17.6 months.

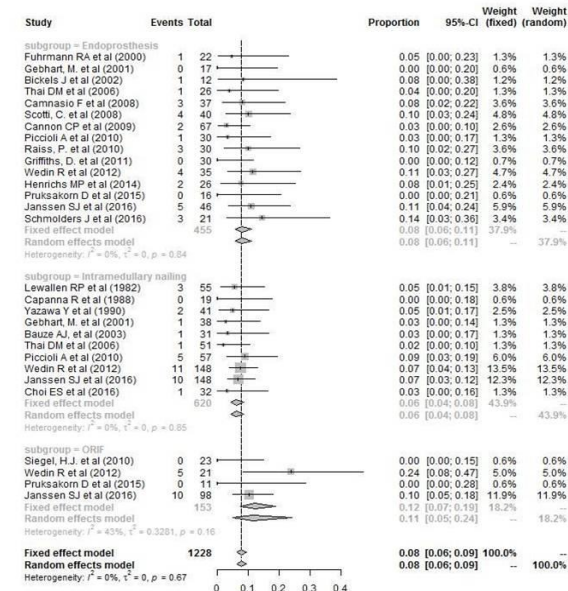


Figure 4: The meta-analysis with global rates of reoperation (black solid rhombuses) for each treatment arm and research which include the confidence interval of 95% [95% CI] expressed as a black horizontal line that crosses the solid rhombuses. ORIF refers to Open Reduction with Internal Fixation. The estimated percentages of the variations in the therapeutic evaluation resulting from heterogenetic nature across researches are demonstrated by the I-squared statistics. The changed scale of percentages on the x-axis is worth to be noted.

II Local Complications

For the patients receiving endoprosthetic reconstruction, the global rate of reoperation was ranged from 0-14%, while those for the patients receiving ORIF and intramedullary nail fixation were 0-8% and 0-9% respectively. It was indicated by the results of Meta-analysis that the respective pooled rates of reoperation for ORIF, intramedullary nail fixation as well as endoprostheses were (95%CI 0.05-0.24), (95%CI 0.04-0.08) as well as (95%CI 0.06-0.11) (Figure 4). The funnel plots and

Egg's plots demonstrated low risk of publication bias based on total reoperation rates as an outcome measure (Figure 5, Figure 6).

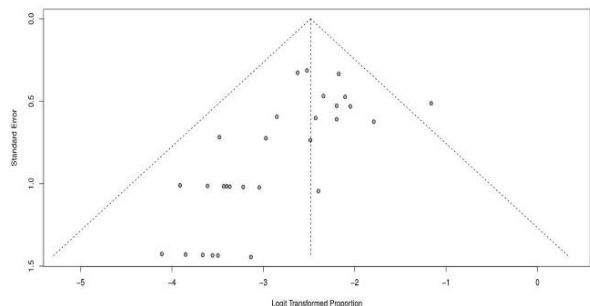


Figure 5: The funnel plots demonstrating low risk of publication bias based on total reoperation rates as an outcome measure.

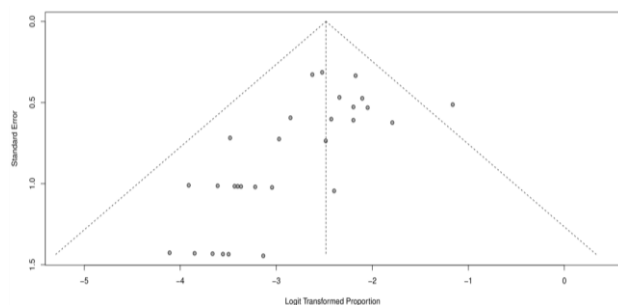


Figure 6: The Egg's plots demonstrating low risk of publication bias based on total reoperation rates as an outcome measure.

The ranges of reoperation rates after fixation failure by ORIF, intramedullary nail fixation as well as reconstruction of endoprosthesis were 0-19%, 0-6% as well as 0-10%. The results of Meta-analysis indicated that the reoperation rates of patients receiving ORIF, intramedullary nail fixation as well as endoprostheses were (95%CI 0.02-0.19), (95%CI 0.01-0.04) as well as (95%CI 0.03-0.07) (Figure 7). The ranges of reoperation rates due to deep infection in patients receiving ORIF, intramedullary nail fixation as well as endoprostheses were 0-2%, 0-2% and 0-9%. The results of Meta-analysis indicated that the reoperation rates of patients receiving ORIF, intramedullary nail fixation as well as endoprostheses were (95%CI 0.01-0.06), (95%CI 0.01-0.03) as well as (95%CI 0.02-0.07) (Figure 8). The ranges of reoperation rates due to dislocations in patients receiving intramedullary nail fixation and endoprostheses were 0-5% and 0-8%, respectively. The results of Meta-analysis indicated reoperation rates of (95%CI 0.02-0.05) for endoprostheses, and (95%CI 0.01-0.04) for intramedullary nails. In the ORIF group, only one patient required reoperation due to dislocations (Figure 9) [4]. There were 10 cases required reoperation because of tumor recurrence or progression in three surgical techniques. The recurring tumors included: 3 renal tumor, 1 colorectal tumor, 1 lung tumor, as well as undefined tumors in the rest 5 cases. There were causes else including hematoma (2) after endoprosthetic reconstruction; nonunion after intramedullary nailing (9) and ORIF (1) in the overall reoperation rates [4, 6, 15].

III Systemic Complications

Only partially studies reported systemic complications including pneumonia, pulmonary embolism, cerebrovascular accident, respiratory failure, intraoperative mortality and so on. However, with these limited

data the impact of surgical approaches for outcomes could not be sufficiently analyzed (Table 3).

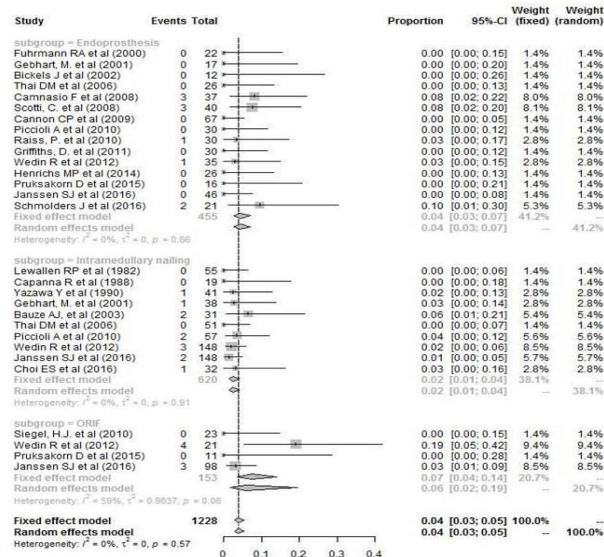


Figure 7: The meta-analysis with rates of reoperation for fixation failure (black solid rhombuses) for each treatment arm and research which include the confidence interval of 95% [95% CI] expressed as a black horizontal line that crosses the solid rhombuses. ORIF refers to Open Reduction with Internal Fixation. The estimated percentages of the variations in the therapeutic evaluation resulting from heterogenetic nature across researches are demonstrated by the I-squared statistics. The changed scale of percentages on the x-axis is worth to be noted.

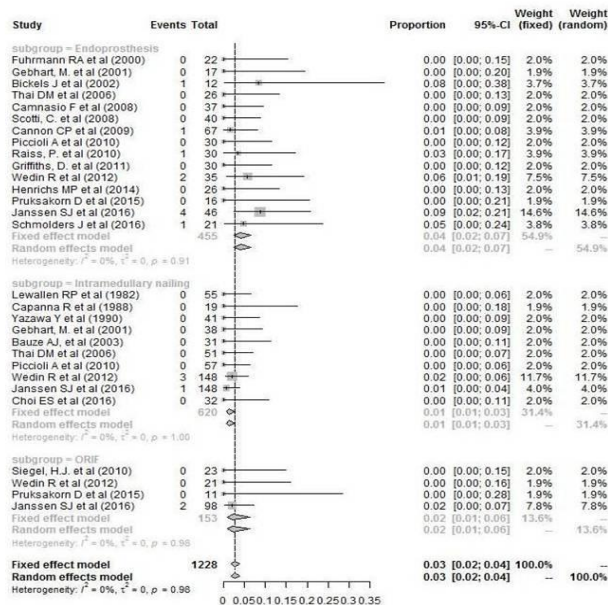


Figure 8: The meta-analysis with rates of reoperation for deep infections (black solid rhombuses) for each treatment arm and research which include the confidence interval of 95% [95% CI] expressed as a black horizontal line that crosses the solid rhombuses. ORIF refers to Open Reduction with Internal Fixation. The estimated percentages of the variations in the therapeutic evaluation resulting from heterogenetic nature across researches are demonstrated by the I-squared statistics. The changed scale of percentages on the x-axis is worth to be noted.

Table 3: Local and Systemic Complication Rates Per Implant Type for Metastatic Humerus.

Author, year	Implant	humerus	Pathological fractures	Deep infection	Fixation failure	Disloc.	Recurr.	Reop.	Sys. comp.
Lewallen RP et al (1982)	IMN	55	--	0(0)	0(0)	3(5)	0(0)	3(5)	--
Capanna R et al (1988)	IMN	19	--	0(0)	0(0)	0(0)	0(0)	0(0)	--
Yazawa Y et al (1990)	IMN	41	--	0(0)	1(2)	1(2)	0(0)	2(5)	--
Fuhrmann RA et al (2000)	EPR	22	--	0(0)	0(0)	0(0)	0(0)	1(5)	0
Gebhart, M. et al (2001)	EPR	17	--	0(0)	0(0)	0(0)	0(0)	0(0)	0(0)
Gebhart, M. et al (2001)	IMN	38	--	0(0)	1(3)	0(0)	0(0)	1(3)	0(0)
Bickels J et al (2002)	EPR	12	--	1(8)	0(0)	0(0)	0(0)	1(8)	--
Bauze AJ, et al (2003)	IMN	31	25	0(0)	2(6)	0(0)	0(0)	2(6)	--
Thai DM et al (2006)	EPR	26	--	0(0)	0(0)	1(4)	0(0)	1(4)	---
Thai DM et al (2006)	IMN	51	--	0(0)	0(0)	0(0)	1(2)	1(2)	--
Camnasio F et al (2008)	EPR	37	--	0(0)	3(8)	0(0)	0(0)	3(8)	--
Scotti, C. et al (2008)	EPR	40	12	0(0)	3(8)	1(3)	0(0)	4(10)	--
Cannon CP et al (2009)	EPR	67	--	1(1)	0(0)	0(0)	1(1)	2(3)	--
Piccioli A et al (2010)	EPR	30	--	0(0)	0(0)	0(0)	1(4)	1(4)	--
Piccioli A et al (2010)	IMN	57	--	0(0)	2(4)	0(0)	3(5)	5(9)	--
Siegel, H.J. et al (2010)	ORIF	23	--	0(0)	0(0)	0(0)	0(0)	0(0)	--
Raiss, P. et al (2010)	EPR	30	--	1(3)	1(3)	1(3)	0(0)	3(10)	--
Griffiths, D. et al (2011)	EPR	30	--	0(0)	0(0)	0(0)	0(0)	0(0)	--
Wedin R et al (2012)	EPR	35	--	2(6)	1(3)	1(3)	0(0)	4(11)	--
Wedin R et al (2012)	IMN	148	--	3(2)	3(2)	0(0)	0(0)	11(7)	--
Wedin R et al (2012)	ORIF	21	--	0(0)	4(19)	0(0)	0(0)	5(24)	--
Henrichs MP et al (2014)	EPR	26	--	0(0)	0(0)	2(8)	0(0)	2(8)	--
Pruksakorn D et al (2015)	EPR	16	--	0(0)	0(0)	0(0)	0(0)	0(0)	--
Pruksakorn D et al (2015)	ORIF	11	--	0(0)	0(0)	0(0)	0(0)	0(0)	--
Janssen SJ et al (2016)	EPR	46	--	4(9)	0(0)	0(0)	0(0)	5(11)	--
Janssen SJ et al (2016)	IMN	148	--	1(1)	2(1)	1(1)	2(1)	10(7)	--
Janssen SJ et al (2016)	ORIF	98	--	2(2)	3(3)	1(1)	2(2)	10(10)	--
Choi ES et al (2016)	IMN	32	21	0(0)	1(3)	0(0)	0(0)	1(3)	0(0)
Schmolders J et al (2016)	EPR	21	--	1(2)	2(10)	0(0)	0(0)	3(14)	--

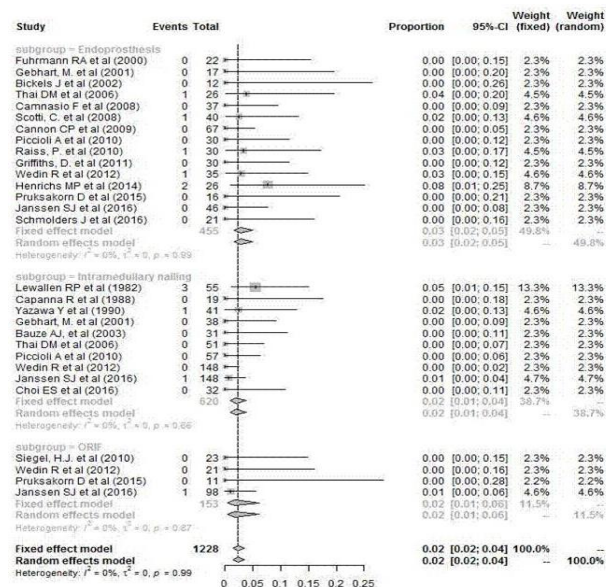


Figure 9: The meta-analysis with rates of reoperation for dislocations (black solid rhombuses) for each treatment arm and research which include the confidence interval of 95% [95% CI] expressed as a black

horizontal line that crosses the solid rhombuses. ORIF refers to Open Reduction with Internal Fixation. The estimated percentages of the variations in the therapeutic evaluation resulting from heterogenetic nature across researches are demonstrated by the I-squared statistics. The changed scale of percentages on the x-axis is worth to be noted.

Discussion

Analyzing outcomes after the common operative treatments including endoprosthetic reconstruction, intramedullary nailing, and ORIF could contribute to intervene surgically for metastatic humerus. We aimed to make appropriately surgical decision to improve the living qualities of the remainder of the patients’ lives by comparing the three among common operative treatments. The general and local complications as well as the functional outcomes were analyzed.

We found that there was wide variation in the criteria applied for functional outcome measures and the MSTS score is most frequently used. There were 8 studies in 21 studies where MSTS score was applied. Additional we didn’t directly assess functional outcome of three operative treatments due to the limited number of studies and the discordant follow-up period. The functional outcome indicated that the upper limb function apparently returned after surgery, however the

degree to improvement was unknown. Furthermore, both the preoperative and postoperative functional levels were included. Additionally, the outcome assessors completing the evaluation on the functional outcomes of the patients shouldn't overestimate function and underestimate pain, but also measurement of living qualities, such as the instrument of EQ-5D or SF-36 were considered [25]. It was discovered that ORIF exhibited the maximized general rate of reoperation, in spite of the limitation in direct comparisons of local complication among operating treatments. The endoprosthetic reconstruction and intramedullary nailing have a lower overall reoperation rate. Furthermore, we found that revision surgery for failure of fixation was more frequent after ORIF, and revision surgery due to deep infections seemed more frequent after endoprostheses. Reoperations resulting from dislocations was relatively rare in three surgical treatments. We consider that intramedullary nailing has become the acceptable alternative for treatment of metastatic humerus in the metastatic diaphyseal humeral lesion of the patients whose expected live durations were shorter than half a year. Prosthetic arthroplasty is appropriate to reconstruct proximal humeral neck or head injuries, injuries with massive osseous losses in proximal humerus, or injuries resisting to radiotherapy. It is also suitable for the patients whose expected life durations were desirable, that is, longer than half a year. Additionally, total elbow prostheses can be a suitable alternative for injuries with massive osseous losses in distal humerus.

Our study has five main limitations. Firstly, although we searched five large literature databases, several relevant articles might be omitted since which were not included in the above-mentioned databases. However, we didn't find other publications after we had extensively screened the bibliographies of these articles. Secondly, several researches including uncertain lesions or the reason for revision surgery were excluded [26, 27]. However, we also energetically contacted author for primary data. The study would be excluded only if the author didn't be contacted. Thirdly, the elements of these studies including the type of implants, the surgical technique, postoperative rehabilitation, location of the lesion and extend of bone destruction probably varied and we didn't perform subgroup analysis based on these factors which led to selection bias. Efforts were made to focus on humerus metastasis with the aim of minimizing the bias. Fourthly, whether adjuvant treatment-radiotherapy and chemotherapy should be considered as an important limitation. Finally, it is important to determine a strict follow-up protocol. The follow-up protocol varied might cause attrition bias. Despite of the shortcomings, meta-analysis is proved to be an appropriate way to estimate the pooled rates of reoperation of each operating technique since the result of which is normally the initial appealing result thus is usually perfectly reported.

General complications reported with the highest frequency include pneumonia, pulmonary embolism, cerebrovascular accident and respiratory failure. However, we didn't perform meta-analysis between surgical treatments in systemic complication due to poor quality of reporting data. We considered that future studies including uniform kinds and treatment consequences of systemic complications for one limb per one patient should be more clear [28, 29].

Conclusion

In the current work, the postoperative complications and functional outcomes of three operating treatments for metastatic humerus are analysed. Compared with the high rate of reoperation due to ORIF, those of intramedullary nail fixation and endoprosthetic construction are of comparability. The findings in the current study is applicable for aiding to make appropriately surgical decision to improve the living quality of patients in the remainder of their lives.

Acknowledgements

This work was supported by the Key Project of Medical-Science Research of Hebei Province [20180564] and the Project of the Natural Science Foundation of Hebei Province [H2019206309].

Disclosure

The authors declare that they have no competing interests.

REFERENCES

1. Guzik G (2016) Results of the treatment of bone metastases with modular prosthetic replacement--analysis of 67 patients. *J Orthop Surg Res* 11: 20. [[Crossref](#)]
2. Choi ES, Han I, Cho HS, Park IW, Park JW et al. (2016) Intramedullary Nailing for Pathological Fractures of the Proximal Humerus. *Clin Orthop Surg* 8: 458-464. [[Crossref](#)]
3. Henrichs MP, Krebs J, Gosheger G, Streitbueger A, Nottrott M et al. (2014) Modular tumor endoprostheses in surgical palliation of long-bone metastases: a reduction in tumor burden and a durable reconstruction. *World J Surg Oncol* 12: 330. [[Crossref](#)]
4. Janssen SJ, van Dijke M, Lozano Calderon SA, Ready JE, Raskin KA et al. (2016) Complications after surgery for metastatic humeral lesions. *J Shoulder Elbow Surg* 25: 207-215. [[Crossref](#)]
5. Schwabe P, Ruppert M, Tsitsilonis S, Melcher I, Schaser KD et al. (2014) Surgical management and outcome of skeletal metastatic disease of the humerus. *Acta Chir Orthop Traumatol Cech* 81: 365-370. [[Crossref](#)]
6. Wedin R, Hansen BH, Laitinen M, Trovik C, Zaikova O et al. (2012) Complications and survival after surgical treatment of 214 metastatic lesions of the humerus. *J Shoulder Elbow Surg* 21: 1049-1055. [[Crossref](#)]
7. Panic N, Leoncini E, de Belvis G, Ricciardi W, Boccia S (2013) Evaluation of the endorsement of the preferred reporting items for systematic reviews and meta-analysis (PRISMA) statement on the quality of published systematic review and meta-analyses. *PLoS One* 8: e83138. [[Crossref](#)]
8. Siegel HJ, Lopez Ben R, Mann JP, Ponce BA (2010) Pathological fractures of the proximal humerus treated with a proximal humeral locking plate and bone cement. *J Bone Joint Surg Br* 92: 707-712. [[Crossref](#)]
9. Raiss P, Kinkel S, Sauter U, Bruckner T, Lehner B (2010) Replacement of the proximal humerus with MUTARS tumor endoprostheses. *Eur J Surg Oncol* 36: 371-377. [[Crossref](#)]
10. Griffiths D, Gikas PD, Jowett C, Bayliss L, Aston W et al. (2011)

- Proximal humeral replacement using a fixed-fulcrum endoprosthesis. *J Bone Joint Surg Br* 93: 399-403. [[Crossref](#)]
11. Cannon CP, Paratitici GU, Lin PP, Lewis VO, Yasko AW (2009) Functional outcome following endoprosthesis reconstruction of the proximal humerus. *J Shoulder Elbow Surg* 18: 705-710. [[Crossref](#)]
 12. Capanna R, Mapelli S, Ruggieri P, Biagini R, Ferruzzi A et al. (1988) Resection of the proximal humerus and I.O.R. modular prosthesis in the treatment of metastatic lesions. *Ital J Orthop Traumatol* 14: 143-148. [[Crossref](#)]
 13. Lewallen RP, Pritchard DJ, Sim FH (1982) Treatment of pathologic fractures or impending fractures of the humerus with Rush rods and methylmethacrylate. Experience with 55 cases in 54 patients, 1968-1977. *Clin Orthop Relat Res* 193-198. [[Crossref](#)]
 14. Yazawa Y, Frassica FJ, Chao EY, Pritchard DJ, Sim FH et al. (1990) Metastatic bone disease. A study of the surgical treatment of 166 pathologic humeral and femoral fractures. *Clin Orthop Relat Res* 213-219. [[Crossref](#)]
 15. Fuhrmann RA, Roth A, Venbrocks RA (2000) Salvage of the upper extremity in cases of tumorous destruction of the proximal humerus. *J Cancer Res Clin Oncol* 126: 337-344. [[Crossref](#)]
 16. Gebhart M, Dequanter D, Vandeweyer E (2001) Metastatic involvement of the humerus: A retrospective study of 51 cases. *Acta Orthop Belg* 67: 456-63. [[Crossref](#)]
 17. Bickels J, Wittig JC, Kollender Y, Kellar Graney K, Meller I et al. (2002) Limb-sparing resections of the shoulder girdle. *J Am Coll Surg* 194: 422-435. [[Crossref](#)]
 18. Bauze AJ, Clayer MT (2003) Treatment of pathological fractures of the humerus with a locked intramedullary nail. *J Orthop Surg (Hong Kong)* 11: 34-37. [[Crossref](#)]
 19. Thai DM, Kitagawa Y, Choong PFM (2006) Outcome of surgical management of bony metastases to the humerus and shoulder girdle: a retrospective analysis of 93 patients. *Int Semin Surg Oncol* 3: 5. [[Crossref](#)]
 20. Camnasio F, Scotti C, Peretti GM, Fontana F, Fraschini G (2008) Prosthetic joint replacement for long bone metastases: analysis of 154 cases. *Arch Orthop Trauma Surg* 128: 787-793. [[Crossref](#)]
 21. Scotti C, Camnasio F, Peretti GM, Fontana F, Fraschini G (2008) Modular prostheses in the treatment of proximal humerus metastases: Review of 40 cases. *J Orthop Traumatol* 9: 5-10. [[Crossref](#)]
 22. Piccioli A, Maccauro G, Rossi B, Scaramuzza L, Frenos F et al. (2010) Surgical treatment of pathologic fractures of humerus. *Injury* 41: 1112-1116. [[Crossref](#)]
 23. Pruksakorn D, Chantarapanich N, Arpornchayanon O, Leerapun T, Sitthiseriratip K et al. (2015) Rapid-prototype endoprosthesis for palliative reconstruction of an upper extremity after resection of bone metastasis. *Int J Comput Assist Radiol Surg* 10: 343-350. [[Crossref](#)]
 24. Schmolders J, Koob S, Schepers P, Kehrer M, Frey SP et al. (2017) Silver-coated endoprosthetic replacement of the proximal humerus in case of tumour-is there an increased risk of periprosthetic infection by using a trevira tube. *Int Orthop* 41: 423-428. [[Crossref](#)]
 25. Cheng EY (2003) Prospective quality of life research in bony metastatic disease. *Clin Orthop Relat Res* S289-97. [[Crossref](#)]
 26. Stern L-DL, Martínez MF, Rodríguez ME, Delgado TJL (2001) Intramedullary nailing in the treatment of pathological fractures of the humerus. El enclavado endomedular en el tratamiento de las fracturas patológicas de húmero. *Revista de Ortopedia y Traumatología Rev. Ortop. Traumatol* 45: 410-414.
 27. Toepfer A, Lenze U, Pohlig F, Rv E, Gerdesmeyer L et al. (2016) [Pathological Fractures of the Humerus: Experience with 76 Cases in a Musculoskeletal Oncology Centre]. *Z Orthop Unfall* 154: 364-369. [[Crossref](#)]
 28. Clavien PA, Barkun J, de Oliveira ML, Vauthey JN, Dindo D et al. (2009) The Clavien-Dindo classification of surgical complications: five-year experience. *Ann Surg* 250: 187-196. [[Crossref](#)]
 29. Bryant D, Havey TC, Roberts R, Guyatt G (2006) How many patients? How many limbs? Analysis of patients or limbs in the orthopaedic literature: a systematic review. *J Bone Joint Surg Am* 88: 41-45. [[Crossref](#)]