

Available online at www.sciencerepository.org

Science Repository



Case Report

Ossifying Fibroma of the Maxilla: A Case Report and Literature Update

Ukwas A^{1*}, Magdy M² and Elshik M²

¹Division of Maxillofacial Diagnostic, Medical and Surgical Sciences, UCL Eastman Dental Institute, London, UK

²Oral and Maxillofacial Surgery Department, Elaraby Hospital, Menofia, Egypt

ARTICLE INFO

Article history:

Received: 11 August, 2021

Accepted: 26 August, 2021

Published: 10 September, 2021

Keywords:

Fibro-osseous lesions

ossifying fibroma

osteosarcoma

maxilla

bone lesions

ABSTRACT

Ossifying fibroma is a rare benign fibro-osseous neoplasm of the jaw characterized by the replacement of normal bone tissue by a combination of fibrous tissue and newly formed calcified tissues of bone and/or cementum-like material. Lesions often manifest at the 2nd to 4th decades of life with a predominant female predilection. The tumor is usually slow-growing and asymptomatic but can cause notable expansion of the jawbones. Definitive diagnosis of OF can be challenging and usually requires careful clinical, radiographic and histologic assessments. Treatment commonly depends on the size, location and aggressiveness of tumor and can accordingly vary from enucleation and curettage to resection and bone grafting. The prognosis is generally good when the lesion is completely removed, but recurrence is possible in some circumstances. The aim of this article is to present a case report of a recurrent ossifying fibroma in a 28-year-old female patient and to provide an update of the literature.

© 2021 Abdouldaim Ukwas. Hosting by Science Repository.

Introduction

Ossifying fibroma is a rare benign fibro-osseous neoplasm of the jaw characterized by the replacement of normal bone tissue by a combination of fibrous tissue and newly formed calcified tissues of bone and/or cementum-like material [1]. Lesions predominately affect craniofacial bones unilaterally, with the mandible reportedly more commonly affected than the maxilla, where OF tends to affect the canine fossa and zygomatic arch regions [2, 3]. Although commonly occur in the 2nd to 4th decades, OF can occasionally affect children and adolescents [4]. While both genders can be affected, there seems to be a prevalent female predilection [5]. Ossifying fibroma is generally painless and slow-growing lesion, frequently resulting in a significant expansion of the bone and severe deformity [4, 6]. It often presents as a round or ovoid, expansive, painless jawbone mass that may sometimes cause displacement and/or resorption of the roots of adjacent teeth [7]. Although OF is mostly asymptomatic, some patients experience pain, paraesthesia, nasal obstruction, malocclusion, sinusitis, or proptosis, depending on the location of the lesion [8, 9].

Early lesions often have a radiolucent appearance, but as they grow, they become mixed radiolucent-radio-opaque and eventually radio-opaque as more calcified tissue is deposited [10, 11]. Microscopically, OF often appears as a well-demarcated lesion consisting of a fibroblastic stroma containing plexiform and lamellar bone in addition to acellular mineralized material [12]. Lesions also contain hypercellular fibrous tissue with the randomly distributed islands of bony tissue or cementiform calcifications [13]. The definitive diagnosis is often challenging and usually requires a combined assessment of clinical, microscopic, and radiological features [8]. Treatment of OS is variable and usually depends on the size of the lesion, the location, the degree of bone invasion and involvement of surrounding structures [14]. The aim of this article is to present a rare recurrent case of ossifying fibroma and an update of the literature.

Case Report

A 28-year-old female patient was referred by her dentist to the Oral and Maxillofacial Surgery Department of Elaraby Hospital for further investigations and management of a significant mass of the left anterior maxillary alveolar region, causing swelling over the left cheek. The

*Correspondence to: Dr. Abdouldaim Ukwas, Senior Clinical Teaching Fellow, Division of Maxillofacial Diagnostic, Medical and Surgical Sciences, UCL Eastman Dental Institute, Rockefeller Building, 21 University Street, London, WC1E 6DE, UK; Tel: +447588724848; E-mail: abdouldaim.ukwas.09@ucl.ac.uk, a.ukwas@gmail.com

patient had visited the dentist complaining of loose anterior teeth (upper right and left central and lateral incisors and upper left canine.) which had subsequently been extracted before referral. The patient reported that she had been aware that the mass had been slowly increasing in size over the past 18 months. There had been no history of dental infection, trauma to the region or generalized illness. The patient had not had similar lesions elsewhere in her body, and her medical history was unremarkable, with no known allergies or regular medications. However, two years earlier, she had been diagnosed with an ossifying fibroma of the left maxillary alveolar region obliterating the buccal sulcus, which had subsequently been surgically removed.

General examination showed that all of the patient's vital signs were within the normal range. Extra-oral examination revealed a large, diffuse swelling over the left cheek, extending from the upper lip to the left side of the nose obliterating the nasolabial fold and causing deviation of the nose to the right (Figure 1). There were no palpable lymph nodes in the head and neck region. Intra-orally, the upper right and left central and lateral incisors, as well as the upper left canine, were missing. All the remaining teeth in the maxillary left quadrant were vital. There was a diffuse, expansile swelling involving the left maxillary anterior region, measuring approximately 6 × 4 cm, extending antero-posteriorly from the midline to the left upper 2nd molar, and obliterating the labial and left buccal vestibule. Palatally, there was a bony bulge extending from the left alveolar segment and ending abruptly just short of the midline (Figure 2).

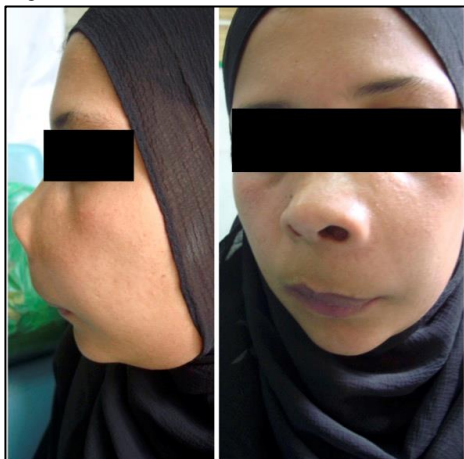

Figure 1: Front and side views of the patient.

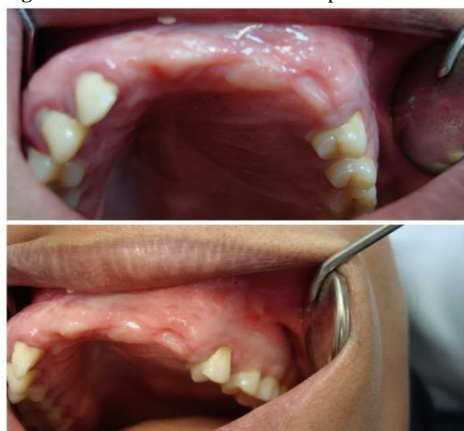

Figure 2: The intraoral presentation of the lesion.

The swelling was non-tender, non-mobile and bony hard in consistency. There was no ulceration or any other mucosal abnormalities. In view of the likelihood that the lesion was of bony origin, radiology was requested. A panoramic view showed a large, diffuse, mixed radiolucent-radiopaque lesion of the left maxillary bone, while an occipitomental view (OMV) showed a large, diffuse radio-opaque lesion obscuring the left maxillary sinus (Figure 3). A subsequent computed tomography (CT) scan revealed a large, mixed radiolucent-radiopaque lesion with predominant homogenous radiopacity occupying the entire left maxillary alveolar and basal bones. The left maxillary antrum was completely occupied by the lesion that abruptly stopped at the midline, while the nasal septum deviated to the right (Figure 4).

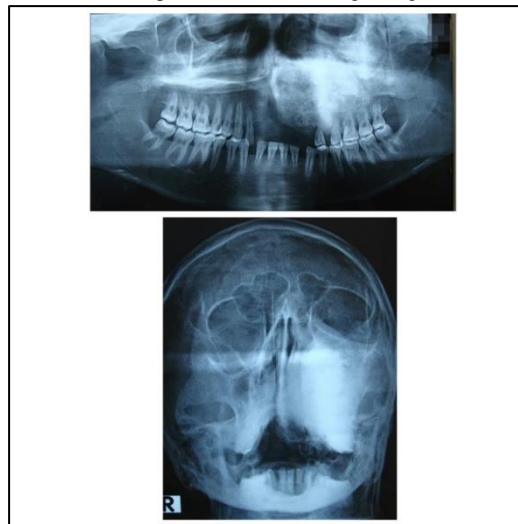


Figure 3: OPG and OMV views of the lesion.

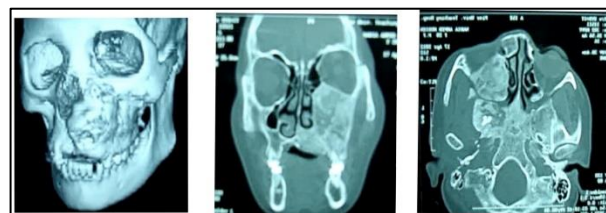

Figure 4: CT scan views of the lesion.

The working differential diagnosis included ossifying fibroma, fibrous dysplasia, giant cell granuloma, calcifying odontogenic cysts, calcifying epithelial odontogenic (Pindborg) tumor. An incisional biopsy was thus undertaken, and histopathologic examination revealed proliferating sheets of spindle-shaped fibroblasts stroma with evident deposition of lamellar bone, which is consistent with ossifying fibroma. Because serum levels for calcium, phosphate, alkaline phosphatase and parathyroid hormone were all normal, conditions like hyperparathyroidism and Paget's disease were excluded. In view of the recurrent nature of the disease in this patient, en bloc surgical resection (hemi-maxillectomy) of the affected area was undertaken with subsequent construction of an obturator (Figure 5). Under GA with nasotracheal intubation, the lesion was approached by Weber-Ferguson with a lip split approach. A hemi-maxillectomy type of resection was accomplished using a reciprocating saw and different sizes of osteotomes. The resection was extended beyond the midline. Following the resection, the wound bed was washed out, debrided and all bleeding points were controlled. The wound bed was then packed with petrolatum gauze, and a prefabricated maxillary obturator was inserted, fitted and

secured in place. Flap edges were re-approximated and closed with 5-0 proline. A nasogastric tube was inserted, and the patient's recovery was uneventful.

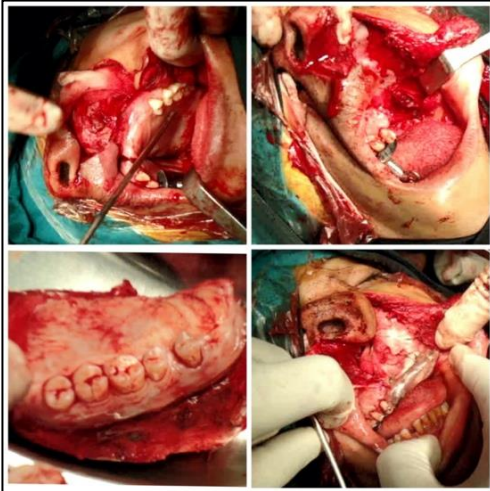


Figure 5: Resection of the tumor and insertion of the prefabricated maxillary obturator.

Discussion

Ossifying fibroma is a slow-growing, asymptomatic, expansive, bone-producing, benign jawbone tumor which often manifests in the 2nd to 4th decades of life and has a predominant female predilection [1, 4, 5, 10]. The patient in our case was a 28-year-old female and, as such, fell into this category even when she had first been diagnosed. Although lesions are reportedly less common in the maxilla than mandible, they are frequently very large at the time of diagnosis in view of their ability to expand freely into the maxillary sinus [4]. Lesions may also involve the nasal septum, orbital floor and/or the infraorbital canal [15]. As a consequence of their possible large size and location, maxillary lesions can be more challenging than mandibular lesions to be completely removed [8].

In the present patient, the lesion had invaded the whole left maxillary antrum, with subsequent nasal septum deviation towards the contralateral side. In view of the tumor's aggressiveness and location, the chosen approach was radical surgical resection. Although the typical treatment of OF is complete surgical removal, the choice of treatment is usually dependent on the size and/or location of the lesion and the degree of involvement of surrounding structures. Small and well-demarcated lesions can sometimes be successfully treated conservatively by enucleation or curettage until healthy bone margins are reached, whereas larger lesions, with an evident aggressive pattern, especially in the maxilla, require radical surgery with healthy margins [16]. Curettage is often indicated in cases where the lesion comprises of soft bone, which is merged with the surrounding bone, where there is a poorly defined radiolucency around the pathology, or where the lesion could not be removed completely due to its size or lack of access. Enucleation is indicated if the lesion is well-demarcated, encapsulated and has not reached a very large size, whereas radical resection with continuity defect is indicated in cases involving the inferior border of mandible or those extending into the maxillary sinus and nasal cavities and having diffuse or ill-defined margins [17].

The present case had initially been treated conservatively with enucleation and curettage, but the procedure appeared to be unsuccessful as the tumor recurred two years later. The recurrence rates of OF are generally low, reportedly at 10.1% after an average of 25.1 months follow up: 49.7% after enucleation, 36.6% after curettage and 13.7% after resection [7, 18, 19]. Perhaps, unsurprisingly, the disease is much more likely to recur following incomplete resection, which raises the question of whether it is a true recurrence (i.e., a new disease) or further growth of the incompletely removed tumor. The available literature is still ambiguous regarding this matter; thus, further studies are required. Furthermore, recurrence is often unpredictable and frequently seen in younger patients. Therefore, a follow-up period of at least 10 years with an OPG once every three years is recommended by some authors [2]. Although enucleation and curettage may carry the highest risk for recurrence, such an approach is advocated by some authors as they are associated with less morbidity and uneventful healing in comparison to radical resection - which often requires bone grafting and could result in an aesthetic deformity and/or loss of function [19]. Surgeons must therefore plan their approach for each case individually and carefully consider the lesion's features (size, site, aggressiveness etc.) as well as patient-specific factors or wishes to weigh up the potential benefits and risks for each treatment option e.g. a single procedure of surgical resection of maxillary OF which has the potential to expand hugely, versus a conservative surgery of the lesion with a potential 2nd surgery should the tumor recurs. Currently, there are no reported guidelines to be followed; thus, treatment of OF still largely depends on the experience and/or preference of the operating surgeon as well as the facilities at their disposal.

Conclusion

Ossifying fibroma is a painless, benign fibrous-osseous tumor that has the potential to grow to extensive sizes if left untreated. The best treatment is complete surgical excision especially for large, recurrent and/or aggressive lesions. Recurrence is generally low, but it is often unpredictable, and its likelihood seems to increase with conservative treatment approaches such as enucleation and curettage. Available literature provides different recurrence rates, but there is an ambiguity whether recurrent tumors are true, newly developing lesions or incompletely removed ones. We have presented a case of recurrent ossifying fibroma of the left anterior maxilla in a 28-year-old female patient which had been incompletely removed two years earlier and the patient had to undergo resection with the construction of an obturator. This case is another example that highlights the importance of a regular, long-term follow-up of OF lesions after surgical removal as recommended by several authors.

Conflicts of Interest

None.

Consent

The patient has been consented according to the International Committee of Medical Journal Editors (ICMJE) recommendations.

REFERENCES

1. Khan SA, Sharma NK, Raj V, Sethi T (2011) Ossifying fibroma of maxilla in a male child: Report of a case and review of the literature. *Natl J Maxillofac Surg* 2: 73-79. [[Crossref](#)]
2. Ibrahem HM (2020) Gnathic Bones and Hyperparathyroidism: A Review on the Metabolic Bony Changes Affecting the Mandible and Maxilla in case of Hyperparathyroidism. *Adv Med* 2020: 6836123. [[Crossref](#)]
3. da Silveira DT, Cardoso FO, E Silva BJA, E Alves Cardoso CA, Manzi FR (2015) Ossifying fibroma: report on a clinical case, with the imaging and histopathological diagnosis made and treatment administered. *Rev Bras Ortop* 51: 100-104. [[Crossref](#)]
4. Bhat P, Kaushik A, Vinod VC, Sridevi K, Chaudhry A (2017) Ossifying fibroma of the maxilla: a rare case. *Int J Radiol Radiat Ther* 3: 198-201.
5. Brannon RB, Fowler CB (2001) Benign fibro-osseous lesions: a review of current concepts. *Adv Anat Pathol* 8: 126-143. [[Crossref](#)]
6. Alsharif MJ, Sun ZJ, Chen XM, Wang SP, Zhao YF (2009) Benign fibro-osseous lesions of the jaws: a study of 127 Chinese patients and review of the literature. *Int J Surg Pathol* 17: 122-134. [[Crossref](#)]
7. Chang CC, Hung HY, Chang JYF, Yu CH, Wang YP et al. (2008) Central ossifying fibroma: a clinicopathologic study of 28 cases. *J Formos Med Assoc* 107: 288-294. [[Crossref](#)]
8. Gondivkar SM, Gadbail AR, Chole R, Parikh RV, Balsaraf S (2011) Ossifying fibroma of the jaws: report of two cases and literature review. *Oral Oncol* 47: 804-809. [[Crossref](#)]
9. Shetty SK, Dasukil S, Arora G (2020) Aggressive Ossifying Fibroma of the Maxilla. *Ann Maxillofac Surg* 10: 262-266. [[Crossref](#)]
10. Sciubba JJ, Younai F (1989) Ossifying fibroma of the mandible and maxilla: review of 18 cases. *J Oral Pathol Med* 18: 315-321. [[Crossref](#)]
11. Domingue MHL, Domingue AAS, Matos BH, Domingue PR, León JE et al. (2014) Extensive presentation of central ossifying fibroma treated with conservative surgical excision. *Case Rep Dent* 2014: 204258. [[Crossref](#)]
12. Moshy J, Dimba E, Ocholla T, Chindia M (2012) Characteristic Radiological and Histological Patterns of Fibrous Dysplasia and Ossifying Fibroma of the Jaws at University of Nairobi Dental Teaching Hospital. *Surg Sci* 3: 189-193.
13. Silvestre Rangil J, Silvestre Donat FJ, Requeni Bernal J (2011) Cemento-ossifying fibroma of the mandible: presentation of a case and review of the literature. *J Clin Exp Dent* 3: 66-69.
14. Macedo D de V, Ferreira G, Vieira EH, Monnazzi MS (2020) Ossifying fibroma in the maxilla and orbital floor: report of an uncommon case. *J Korean Assoc Oral Maxillofac Surg* 46: 204-207. [[Crossref](#)]
15. Ramesh DNSV, Thriveni R, Byatnal A, Shereen W, Kattimani S et al. (2017) Ossifying Fibroma- A Case Report. *J Dent Med Sci* 16: 63-66.
16. Triantafillidou K, Venetis G, Karakinaris G, Iordanidis F (2012) Ossifying fibroma of the jaws: a clinical study of 14 cases and review of the literature. *Oral Surg Oral Med Oral Pathol Oral Radiol* 114: 193-199. [[Crossref](#)]
17. Mohanty S, Gupta S, Kumar P, Sriram K, Gulati U (2014) Retrospective Analysis of Ossifying Fibroma of Jaw Bones Over a Period of 10 Years with Literature Review. *J Maxillofac Oral Surg* 13: 560-567. [[Crossref](#)]
18. Waldron CA (1993) Fibro-osseous lesions of the jaws. *J Oral Maxillofac Surg* 51: 828-835. [[Crossref](#)]
19. Titinchi F, Morkel J (2016) Ossifying Fibroma: Analysis of Treatment Methods and Recurrence Patterns. *J Oral Maxillofac Surg* 74: 2409-2419. [[Crossref](#)]