

Available online at [www.sciencerepository.org](http://www.sciencerepository.org)

Science Repository



## Case Report

# Neurophysiological Monitoring During Large Femoral and Pelvic Tumoral Resections

*Hector Marcelo, Camilla Arvinus\*, Susana Martín-Albarrán, Elena Manrique-Gamo, Roberto Garcia-Maroto and Juan-Luis Cebrian*

*Hospital Clínico San Carlos, Calle Profesor Martín Lagos s/n. 208040 Madrid, Spain*

### ARTICLE INFO

#### Article history:

Received: 2 January, 2020

Accepted: 21 January, 2020

Published: 27 January, 2020

#### Keywords:

*Neurophysiological monitoring*

*intraoperative monitoring*

*tumor*

*reconstructive surgery*

*resection*

### ABSTRACT

**Background:** Oncological femoral or pelvic resections and reconstruction have become an alternative to large amputations. However, one of the frequent risks is the neurological injury. The use of intraoperative evoked potentials allows its control in order to modify the surgical gestures. The purpose of this study was to evaluate the results of intraoperative neurophysiologic monitoring in large reconstructive arthroplasty surgeries.

**Case presentation:** A prospective study (2012-2018) was performed, including 8 patients with 6 complete resections of the femur and 2 resections of the pelvis. In all cases, intraoperative lumbar plexus monitoring was performed using evoked potentials in order to analyze variations during surgery as well as a postoperative control. 100% could be correctly monitored throughout the surgery. In 4 cases, intraoperative anomalies were detected requiring modification of the surgery. Of these, postoperatively only one nerve injury persisted: a complete sciatic nerve injury due to an intraoperative vascular injury.

**Conclusion:** Intraoperative neurophysiological monitoring is a very useful resource in large oncological resection, allowing detection of nerve distress due to manipulation or excessive limb traction during reconstruction. The use of somatosensory evoked potentials in large oncological resections can predict and minimize the risk of relevant postoperative nerve complications.

© 2020 Camilla Arvinus. Hosting by Science Repository.

### Background

Peripheral nerve injury is a serious complication after prosthetic hip surgery, its incidence is low in primary hip arthroplasty, 0.2-0.3%, while it raises to 2.9-7.6% in revision surgery [1-4]. However, there is no literature to be found concerning peripheral nerve lesions in pelvic or femoral reconstructive surgery after large tumoral resections. In these surgeries there are multiple factors that can cause peripheral nerve damage. Traditionally, excessive limb traction during hip reduction has been considered the most important factor [1, 5]. It has been shown in experimental models that nerve injury occur when nerve elongation is greater than 6% of its length [7]. Other causes are direct injuries (retraction, section, laceration or cauterization) or problems in the positioning of the components [8].

Multiple studies have described intraoperative use of somatosensory evoked potentials and continuous intraoperative electromyography as a method of early detection of nerve suffering and injury in spine deformities correction surgeries, resection of intramedullary spine tumors and complex hip surgeries [3, 9-11]. Large pelvic and femoral resection and its reconstruction with megaprosthesis implies a high incidence of postoperative dislocation, but the excessive elongation of the lower limb may cause postoperative nerve injuries. Evaluation of neural distress using intraoperative neurophysiologic monitoring could allow a more optimal degree of stress during prosthesis implantation while avoiding a postoperative nerve injury. The aim of our study was to evaluate the results of intraoperative neurophysiologic monitoring in pelvic reconstruction arthroplasty surgeries after large tumoral resections in order to establish a possible benefit of its systematic use in these surgeries.

\*Correspondence to: Camilla Arvinus, Calle Gaztambide 60, 6B, 28015 Madrid, Spain, Tel: 34693208680; E-mail: [arvinuscamilla@hotmail.com](mailto:arvinuscamilla@hotmail.com)

## Case Presentation

A prospective study was performed between 2012 and 2017 in our center including 8 patients with pelvic reconstructive arthroplasty after large tumoral resections in which intraoperative neurophysiologic monitoring was carried out. The patients were selected by the orthopedic surgeons in collaboration with the neurophysiologic team due to their high risk of

nerve injury during surgery. All patients were operated by the same team of oncological orthopedic surgeons and monitored by the same neurophysiologist. The surgeries were performed with general anesthesia, in such a way that the alterations or variations of the intraoperative neurophysiologic studies could be noticed. The demographic data such as age, type of tumor and arthroplasty used are presented in (Table 1).

**Table 1:** Monitored patients characteristics and surgical procedures. ORIF: open reduction internal fixation.

Nº	Sex	Age	Diagnosis	Approach	Procedure
1	Male	54	Femoral fibrous dysplasia	Direct lateral	Total femoral prosthesis (type Mega C, Link®)
2	Male	63	Femoral chondrosarcoma grade III	Direct lateral	Total femoral prosthesis (type Mega C, Link®)
3	Male	46	Pathological femoral fracture secondary to intraosseous leiomyosarcoma	Direct lateral	Total femoral prosthesis type Mega C, Link®
4	Male	45	Femoral Ewing's sarcoma 2000. Posterior fracture, non-union and failure of ORIF.	Direct lateral	Total femoral prosthesis type Mega C, Link®
5	Male	56	Femoral chondrosarcoma grade III in Paget's disease	Direct lateral	Total femoral prosthesis type Mega C, Link®
6	Female	54	Pelvic chondrosarcoma grade II affecting Enneking 2 and 3	Triradiate approach	Prosthesis type Coned, Stanmore®
7	Male	33	Femoral osteosarcoma	Direct lateral	Total femoral prosthesis type Mega C, Link®
8	Male	72	Pelvic Paget's disease malignization affecting Enneking 1 and 2	Triradiate approach	Prosthesis Custom-Made, Link®

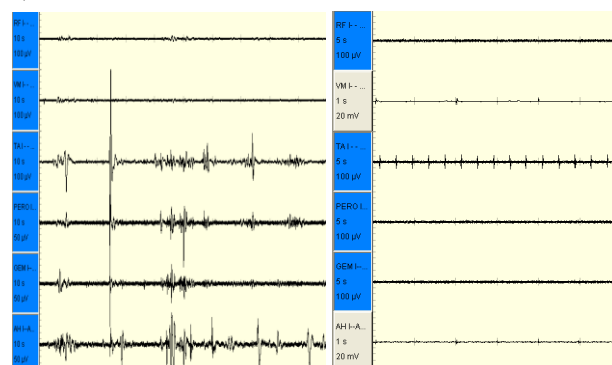
Every patient was monitored intraoperatively with motor and somatosensory evoked potentials (MEP and SSEP) as well as continuous and stimulated electromyography. Motor evoked potentials from the terminal branches of the sciatic and femoral nerves were monitored. In order to monitor the superficial peroneal nerve electrodes were placed on peroneus longus muscle (PE), for the deep peroneal nerve they were placed on the tibialis anterior muscle (TA) and in order to monitor the lateral and medial branch of the tibial nerves they were placed on abductor hallucis (AH) and lateral gastrocnemius (GE) respectively. The electrodes placed on the vastus medialis (VM), vastus lateralis (VL) and rectus femoris (RF) monitored the femoral nerve. Neurophysiological monitoring of the contralateral limb was used as a control. Both upper limbs were monitored on the first dorsal interosseous muscle (ulnar nerve) as control. Somatosensory evoked potentials of both lower limbs were recorded on the posterior tibial nerve and both upper limbs on the ulnar nerve. Evoked potentials were considered altered when the variations of the amplitude were greater than 50% or an increase of the latency of more than 10% was registered.

During surgery, a continuous electromyographic registry was carried out and the stimulation through the surgical field was accomplished through a bipolar electrical field. The existence of nervous distress was considered when electromyographic activity was recorded. The postoperative nervous state of the patients was assessed by clinical exploration and a neurophysiological study was performed in those cases where either intraoperative alteration or clinical postoperative suspicion of nerve injury was detected. The functional evaluation of the patients was determined by the Musculoskeletal Tumor Society Score (MSTS) 12 months after the surgery [12].

## Outcomes

All patients were monitored correctly during surgery. In 4 of the 8 cases (50%), intraoperative anomalies were detected in the neurophysiological registry (Table 2).

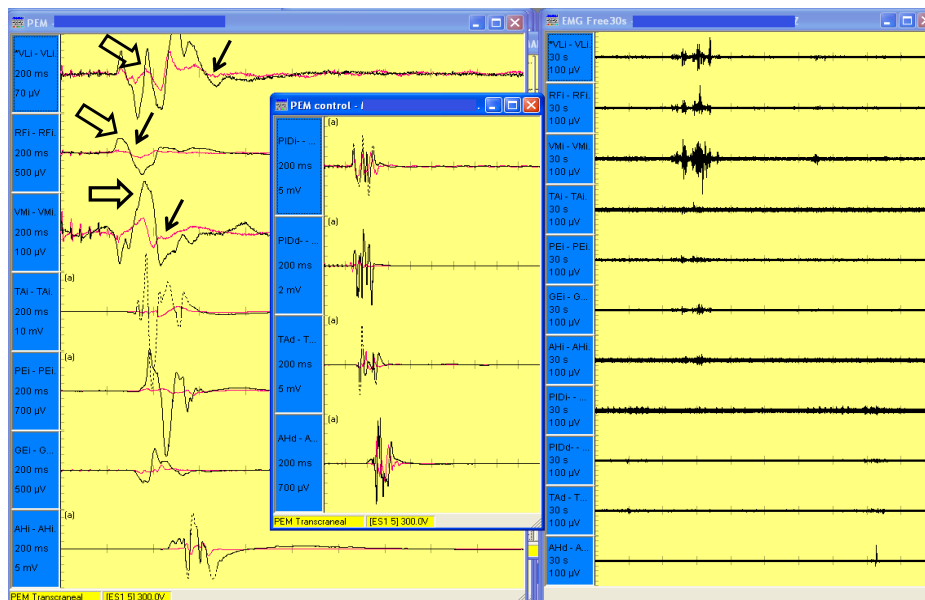
In the first case, when performing traction of the lower extremity in order to test and adapt the prosthesis, continuous neurotonic discharges were recorded in muscles corresponding to the sciatic nerve (TA, PL, GE and AH). The irregular activity disappeared when the traction ceased (Figure 1).



**Figure 1:** Both images show a continuous electromyography record. The left image shows neurotonic discharges that indicate neural distress due to excessive traction of the extremity. On the right image the traction has been interrupted, therefore no activity is recorded, and the neural activity is considered normal.

**Table 2:** Descriptions of the alerts given to the surgeon, the subsequent action taken by the surgeon and postoperative outcomes.

Nº	Register alteration	Intraoperative maneuver	Surgeon maneuver	Postoperative lesion	MSTS
1	SSEP femoral nerve	Traction to reduce the prosthesis	Change of neck length	No nerve lesion	100
2	No	-	-	No nerve lesion	60
3	No	-	-	No nerve lesion	43
4	No	-	-	No nerve lesion	50
5	No	-	-	No nerve lesion	83
6	SSEP femoral nerve	Traction to place the trial prosthesis	Change of neck length	No nerve lesion	48
7	Sudden loss of PESS and PEM in sciatic nerve (TA, PE, GE, AH)	Vascular repair	Progressive recovery after vascular repair	Complete sciatic nerve lesion	36
8	PEM amplitude loss in sciatic nerve (PE and TA)	Placement of the prosthesis	None, spontaneous progressive recovery of PEM	No nerve lesion	53



**Figure 2:** On the left image there is a register of the basal PEM (arrow) and the final PEM (hollow arrow). To detect nerve injury or nervous suffering there must be a 50% amplitude increase or a 10% increase of the latency corrected by ceasing of the stimulus. The image on the right is a continuous electromyography record where the presence of activity (waves appearing in the first 3 lines) indicates nervous suffering. In this case, the activity yields with decreased limb movement.

In the sixth case, while tractioning in order to reduce the femoral prosthesis, the motor evoked potentials corresponding to the femoral nerve (RF, VL and VM) registered alterations as well as a continuous activity at the electromyographic register. These anomalies ceased when the limb traction was diminished, and therefore a shorter femoral neck length was used without detecting any postoperative complications (Figure 2). In the seventh case an abrupt loss of the MEP and SSEP corresponding to the sciatic nerve were detected at the same time as a vascular injury occurred. Vascular reparation was performed and in order to increase the nerve vascularization a state of hypertension was generated that allowed recovery of the potentials 40 minutes after its abolition. This patient represents the only postoperative nerve injury case with a complete sciatic lesion. In the eighth case the MEP amplitude of the peroneal and tibial nerves (TA, PE and GE) decreased after placing the definitive prosthesis, it progressively recovered using high intensity loads through motor cortical stimulation (Figure 3). The

average score on the MSTS scale was 59 (Table 2).

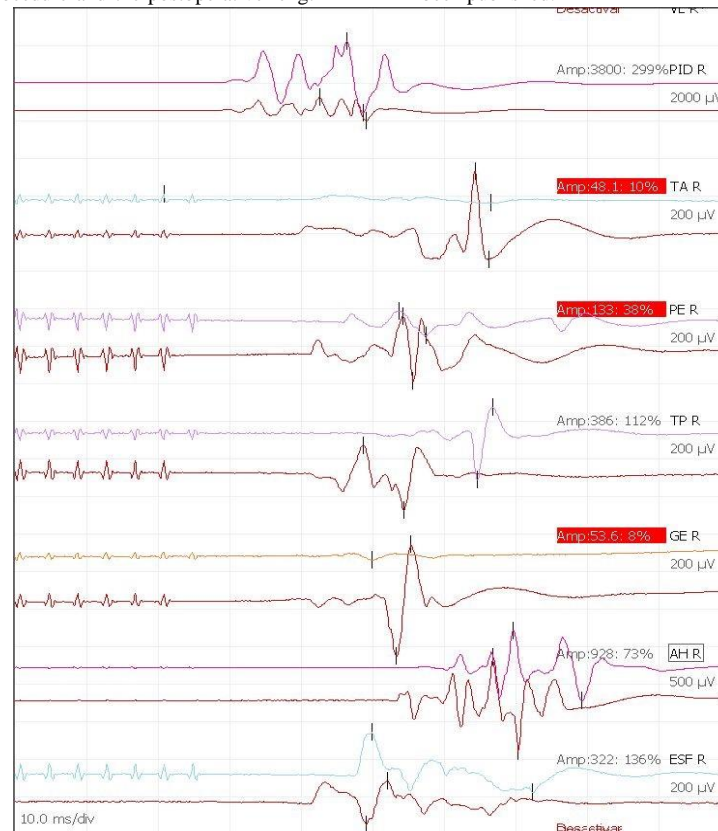
## Discussion

Postoperative nerve injury is a rare but devastating complication. In hip surgery, the sciatic nerve is the most affected structure representing 80% of the cases [13]. The posterior approach, a preoperative diagnosis of hip dysplasia, the use of non-cemented implants and the increased length of the lower limb are factors that increase the risk of nerve injury in primary hip arthroplasty [3]. Intraoperative neurophysiological monitoring is a tool that allows early detection of nerve injuries. Initially it was used in corrective surgery of large spinal deformities and its use has progressively extended to other surgical procedures such as intramedullary spine tumors and prosthetic surgery of the lower limbs [10, 14].

There are several studies in which the sciatic nerve neurophysiological monitoring is performed using intraoperative SSEP during primary hip

prosthetic surgery and revision surgery [3, 16]. When dealing with large tumoral resections the use of megaprosthesis is an alternative to amputation that permits higher rates of postoperative function. However, the complexity of the surgical procedure and the postoperative length

discrepancy may increase the risk of nerve injury compared to prosthetic revision surgery. Nevertheless, no studies concerning intraoperative neurophysiological monitoring in large tumoral pelvic resections have been published.



**Figure 3:** The image corresponds the sciatic PEM register of the right lower limb. The inferior line is a register of the basal PEM and the superior line final PEM at the moment of nerve suffering.

The use of intraoperative neurophysiologic monitoring allows the surgeon to register potential nerve suffering during surgery and to minimize possible postoperative nerve injuries. According to the results of Sutter et al, it is an effective method to alert the surgeon about the risk of a possible nerve injury and adapt the surgical maneuvers according to the registry [17]. Necessian et al conducted a study in patients undergoing prosthetic hip revision surgery [3]. Intraoperative nervous distress was detected on 32% of the monitored patients. No postoperative nerve injuries were registered on the monitored patients compared to a 5,7% of nerve injuries in those who were not monitored. In our study, 50% of the patients presented abnormalities during the intraoperative registration, forcing the surgeon to introduce variations in the surgical technique to correct the anomalies.

Therefore, in line with the results of previous studies we consider that intraoperative neurophysiological monitoring is a tool that alerts the surgeon of the existence of nerve suffering and allowing the surgeon to adapt she surgical maneuvers to decrease such suffering and minimize postoperative injuries. Finally, only one postoperative sciatic nerve lesion was recorded (12.5%) in relation to the ischemia that occurred secondary to a vascular injury. The high percentage of alterations in the intraoperative registry (50%) is due to the greater complexity of the surgical procedures performed and the proximity of some tumoral

lesions to the vascular and nerve structures of the lower limb. These circumstances support the importance of the use of intraoperative monitoring in prosthetic reconstruction surgeries after large tumoral resections.

As to the intraoperative maneuvers Black et al experienced a decrease in the amplitude or increased latency in 18 of 100 patients with SSEP monitoring during hip replacement either while the reaming of the femoral canal or while reducing the prosthesis [18]. In our study 3 of the 4 alterations that were registered occurred during the reduction of the prosthesis. It therefore seems that the prosthesis reduction maneuver is crucial when it comes to generation of postoperative nerve injury. An excessive traction of the limb that generates nervous suffering can be detected by alterations in the neurophysiological register. This permits the surgeons to adapt the selection of prosthetic components (different neck lengths) in order to achieve a balance in which adequate stability of the prosthesis does not compromise the nerve structures.

Another fact to consider is that during large tumoral resections there are more nerve structures at risk than in hip revision surgery. Most of the studies published only perform sciatic nerve monitoring through somatosensory evoked potentials. Sutter et al monitored the femoral nerve on the vastus medialis and used stimulated electromyography as an auxiliary tool to identify nerve structures in the surgical field [17]. In

every case of this study we have monitored intraoperatively the sciatic nerve terminal branches (AH, PE, TE and GE) and femoral nerve terminal branches (VM, VL and RF). There was a continuous electromyography register during the surgery and a stimulated register in the surgical field which allows a complete monitoring of the nervous structures of the lower limb that increases the sensitivity in detection a possible nerve injury. The benefits of the neurophysiological monitoring of motor and somatosensory evoked potentials have been well described as a method of prevention and prediction of nerve injuries [3, 17, 18]. However, this is the first study with a complete lower limb monitoring with MEP and SSEP, continuous electromyography and stimulated electromyography in large tumoral resections. We consider that it is a useful tool that permits registration of nerve injuries in real time and therefore recommend its use in order to predict and prevent postoperative nerve complications.

### Conclusion

Intraoperative neurophysiological monitoring is a very useful resource in large oncologic resections, allowing detection of nerve injuries due to nerve manipulation or excessive limb traction during reconstruction. The use of somatosensory evoked potentials allows the surgeon to predict and minimize the risk of relevant postoperative nerve complications.

### Availability of Data and Materials

The dataset supporting the conclusion of this article is included within the article.

### Declaration of Interest

None.

### Ethics Approval and Consent to Participate

Not applicable.

### Consent for Publication

Not applicable.

### Author Contributions

All authors contributed to the design of the study, collection of data as well as the preparation of the article. All authors approve the final article.

### Funding

None.

### REFERENCES

1. Edwards BN, Tullos HS, Noble PC (1987) Contributory factors and etiology of sciatic nerve palsy in total hip arthroplasty. *Clin Orthop Relat Res* 218: 136-141. [[Crossref](#)]
2. Johanson NA, Pellicci PM, Tsairis P, Salvati EA (1983) Nerve injury in total hip arthroplasty. *Clin Orthop Relat Res* 179: 214-222. [[Crossref](#)]
3. Nercessian OA, Gonzalez EG, Stinchfield FE (1989) The use of somatosensory evoked potential during revision or reoperation for total hip arthroplasty. *Clin Orthop Relat Res* 243: 138-142. [[Crossref](#)]
4. Amstutz HC, Ma SM, Jinnah RH, Mai L (1982) Revision of aseptic loose total hip arthroplasties. *Clin Orthop Relat Res* 170: 21-33. [[Crossref](#)]
5. Nercessian OA, Macaulay W, Stinchfield FE (1994) Peripheral neuropathies following total hip arthroplasty. *J Arthroplasty* 9: 645-651. [[Crossref](#)]
6. Nercessian OA, Piccoluga F, Eftekhar NS (1994) Postoperative sciatic and femoral nerve palsy with reference to leg lengthening and medialization/lateralization of the hip joint following total hip arthroplasty. *Clin Orthop Relat Res* 304: 165-171. [[Crossref](#)]
7. Lewallen DG (1998) Neurovascular injury associated with hip arthroplasty. *Instr Course Lect* 47: 275-283. [[Crossref](#)]
8. Strike SA, Hassanzadeh H, Jain A, Kebaissh KM, Njoku DB et al. (2017) Intraoperative Neuromonitoring in Pediatric and Adult Spine Deformity Surgery. *Clin Spine Surg* 30: 1174-1181. [[Crossref](#)]
9. Kennedy WF, Byrne TF, Majid HA, Pavlak LL (1991) Sciatic nerve monitoring during revision total hip arthroplasty. *Clin Orthop Relat Res* 264: 223-227. [[Crossref](#)]
10. Rasmussen TJ, Black DL, Bruce RP, Reckling FW (1994) Efficacy of corticospinal somatosensory evoked potential monitoring in predicting and/or preventing sciatic nerve palsy during total hip arthroplasty. *J Arthroplasty* 9: 53-61. [[Crossref](#)]
11. Enneking WF, Dunham W, Gebhardt MC, Malawar M, Pritchard DJ (1993) A system for the functional evaluation of reconstructive procedures after surgical treatment of tumours of the musculoskeletal system. *Clin Orthop Relat Res* 286: 241-246. [[Crossref](#)]
12. Schmalzried TP, Noordin S, Amstutz HC (1997) Update on nerve palsy associated with total hip replacement. *Clin Orthop Relat Res* 344: 188-206. [[Crossref](#)]
13. Farrell CM, Springer BD, Haidukewych GJ, Morrey BF (2005) Motor nerve palsy following primary total hip arthroplasty. *J Bone Joint Surg Am* 87: 2619-2625. [[Crossref](#)]
14. Satcher RL, Noss RS, Yingling CD, Ressler J, Ries M (2003) The use of motor -evoked potentials to monitor sciatic nerve status during revision total hip arthroplasty. *J Arthroplasty* 18: 329-332. [[Crossref](#)]
15. Stone RG, Weeks LE, Hajdu M, Stinchfield FE (1985) Evaluation of sciatic nerve compromise during total hip arthroplasty. *Clin Orthop Relat Res* 201: 26-31. [[Crossref](#)]
16. Sutter M, Hersche O, Leunig M, Gugli T, Dvorak J et al. (2012) Use of multimodal intra-operative monitoring in averting nerve injury during complex hip surgery. *J Bone Joint Surg Br* 94: 179-184. [[Crossref](#)]
17. Black DL, Reckling FW, Porter SS (1991) Somatosensory-evoked potential monitored during total hip arthroplasty. *Clin Orthop Relat Res* 262: 170-177. [[Crossref](#)]
18. Porter SS, Black DL, Reckling FW, Mason J (1989) Intraoperative cortical somatosensory evoked potentials for detection of sciatic neuropathy during total hip arthroplasty. *J Clin Anesth* 1: 170-176. [[Crossref](#)]