

Available online at www.sciencerepository.org

Science Repository



Research Article

Diagnosis and Surgical Treatment of Traumatic Intracranial Hematomas in Young Children

Igor Ivanovich Larkin^{1*}, Valeriy Ivanovich Larkin¹, Tadeush Petrovich Milcharek², Svetlana Yurievna Vegner³ and Igor Petrovich Koshman¹

¹Department of Neurology and Neurosurgery, Omsk State Medical University, Omsk, Russia

²Department of Labour Psychology and Organizational Psychology, Omsk State Technical University, Omsk, Russia

³City Children's Clinical Hospital №3, Omsk, Russia

ARTICLE INFO

Article history:

Received: 15 March, 2021

Accepted: 6 April, 2021

Published: 19 April, 2021

Keywords:

Mass effect

volume hematoma index

minimally invasive surgery

ABSTRACT

Objective: To improve the treatment of young children with traumatic intracranial hematomas by improving the diagnosis and use of minimally invasive surgical methods based on calculations of the intracranial hematoma volume index (VICH).

Subjects and Methods: An analysis of the clinical course as well as the surgical treatment of 111 patients was carried out. The patients were under the age of 3, with severe traumatic brain injury, and formation of intracranial hematomas. The children were treated at the Department of Pediatric Neurosurgery of the City Children's Clinical Hospital No.3 in Omsk, Russia, from 2008 to 2018. Three groups were identified: Group A - children with epidural hematomas (n=30), Group B - children with subdural hematomas (n=43), Group C - children with multiple hematomas (n=38). The volume index of intracranial hematomas (VICH) was calculated, and the surgical tactics were determined based on the value of the VICH.

Results: Children with a VICH less than 2% received conservative treatments. Those with a VICH from 2 to 4% were treated with minimally invasive methods (puncture, drainage). Children with VICH above 4% underwent decompressive surgery.

Conclusion: The effectiveness of the developed differentiated tactics of treatment of young children with traumatic intracranial hematomas (ICH) is characterized by a decrease in the risk of an unfavourable outcome by 74.2% and mortality by 1.2%.

© 2021 Igor Ivanovich Larkin. Hosting by Science Repository.

Objective

To improve the treatment of young children with traumatic intracranial hematomas by improving diagnostics as well as the application of minimally invasive surgical methods, taking into account the volume of intracranial hematomas (CHVI) index.

Introduction

Traumatic injuries are the leading cause of death and the leading cause of disability among children [1, 2]. The most common causes of these traumas are falling from heights, car accidents, and child abuse [3, 2]. Patients with severe brain injury require surgical treatment [4, 5-7].

*Correspondence to: Igor Ivanovich Larkin, Department of Neurology and Neurosurgery, Omsk State Medical University, 644099, 12, Lenina Street, Omsk, Russia; Tel: +79237673513; E-mail: larkinomsk@mail.ru

Currently, the problem of choosing the optimal surgical techniques for young children has not been fully resolved.

Subjects and Methods

The study was conducted in two stages. From 1999 to 2008, CT morphometry was performed on 232 children to help determine the volume of the skull cavity “in vivo”. The study also correlated the brain size with age and established the dependence of the cranial cavity volume based on its circumference, while taking into account the age of the child [6]. In order to study the features of the clinical course of traumatic intracranial hematomas (ICH) in young children, which depends on the type of hematomas, and the degree of their volume index (CHVI). A comparative analysis of the clinical course of isolated traumatic brain injuries (TBI) with the formation of ICH supratentorial localization in 111 children under 3 years of age was carried out. The children were treated in the Department of Pediatric Neurosurgery of the City Children’s Clinical Hospital No.3 in Omsk, Russia from 2008 to 2018. Three groups were identified: Group A - children with epidural hematomas (n=30), Group B - children with subdural hematomas (n=43), Group C - children with multiple hematomas (n=38).

A comparative analysis of the results of the surgical treatment of 102 patients was carried out. In 71 patients, the value of CHVI was taken into account during treatment (Group I). In 31 patients, surgical treatment was carried out without the value of CHVI (Group II). All patients were evaluated for neurological status using “the Glasgow Coma Scale” (GCS), and CT or MRI studies were performed with the calculation of the CHVI index. The calculation of the CHVI was carried out using the formula:

$$CHVI = \frac{Vg}{Vc} \times 100\%$$

The volume index of the hematoma is equal to the ratio of the volume of the hematoma (Vg), calculated in cm³ to the volume of the cranial cavity (Vc) in cm³, expressed as a percentage (%).

The hematoma volume was calculated using the Erickson formula:

$$Vg = \frac{A \times B \times C}{6} \times \pi$$

Where A, B, and C are the main diameters of the hematoma, π - 3.14 (Figure 1). Studies conducted at the first stage allowed us to establish a correlation between the circumference of the skull and its volume (Figure 2).

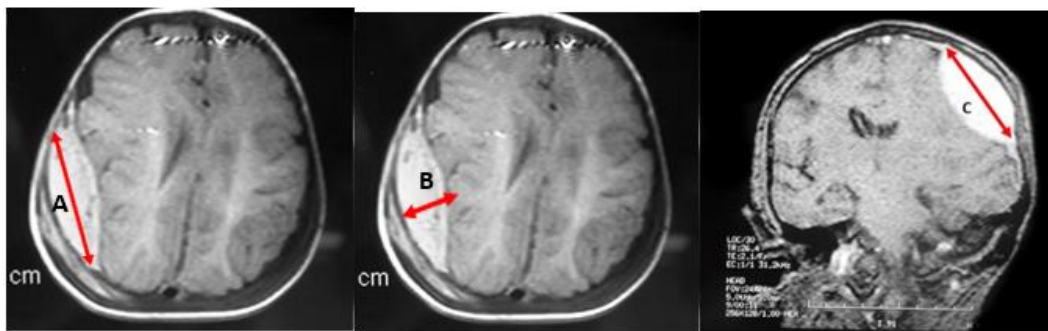


Figure 1: Example of calculating the volume index of a hematoma: A - the longitudinal size of the hematoma; B - the transverse size of the hematoma; C - the vertical size of the hematoma.

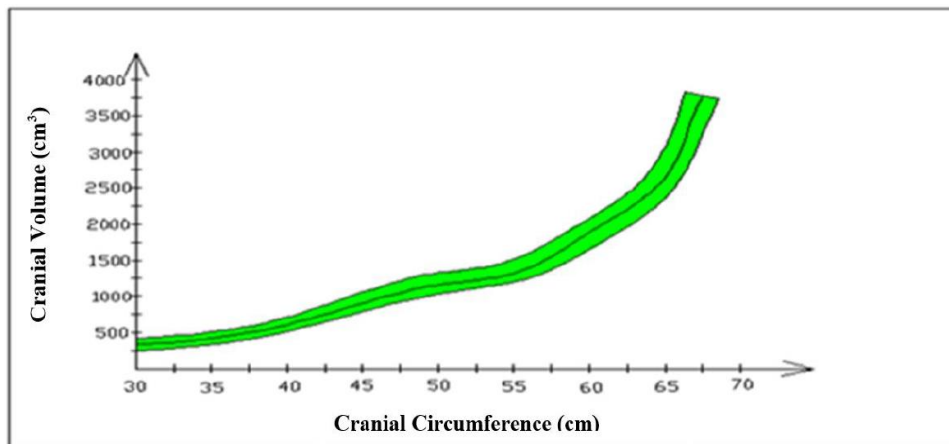


Figure 2: Correlation between the volume of the cranial cavity and the cranial circumference.

When the children were operated on, 71 cases of surgical intervention, were carried out taking into account the CHVI. System statistical analysis was performed using the licensed statistical software “Statistica for Windows V. 8.0”, with preference given to methods of

nonparametric statistics (Mann-Whitney, Kolmogorov-Smirnov, Kruskal-Wallis ANOVA, Spearman correlation analysis). To evaluate the proposed method of a differentiated approach to the surgical treatment of subdural clusters, the severity of the condition was assessed

on all patients using the “Lansky scale” on the first day. The dynamics were assessed on the 7th, 14th, 28th days, as well as at discharge. To identify the differentiation in the dynamics of the conditions of patients in the study groups, the Yates-correction χ^2 criterion and the exact Fisher criterion were used (when $n < 5$).

Results

I The Characteristics of Traumatic Intracranial Hematomas in Young Children

We analysed the features of the clinical course of traumatic ICH in 111 young children, depending on the type of hematomas and the value of CHVI. The distribution of early-age patients, by age and type of traumatic ICH, is presented in (Table 1).

Table 1: Distribution of patients by age and type of intracranial hematomas.

Type of hematoma	Age						Total	
	Neonatal		1m - 1y		1 - 3y		Abs. number	%
	Abs. number	%	Abs. number	%	Abs. number	%		
Epidural	4	4	19	17	7	6	30	27
Subdural	7	6	18	16	19	17	43	39
Multiple	6	5	21	19	11	10	38	34
Total	17	15	58	52	36	33	111	100

II Features of the Clinical Course of Epidural Hematomas in Young Children

Group A - children with epidural hematomas (n=30) was represented as subgroups A1 (n=12), A2 (n=7), and A3 (n=11), depending on the value of CHVI. A direct correlation between the CHVI and the clinical picture of TBI in young children was established.

Table 2: Mass effect of epidural hematomas.

Group, (Amount)	CHVI	M-echo, mm	Cranial volume, cm ³	EPH volume, cm ³	Mass Effect, %
A1 (n=12)	Mild	0 (0; 0) $p=0,01$	734 (440; 741)	5,0 (4,6; 5,3) $p=0,001$	0,9 (0,7; 1,1); $p=0,001$
A2 (n=7)	Moderate	2 (1; 4)	925 (510; 1080)	20 (13; 21,8)	2,0 (2,0; 2,5)
A3 (n=11)	Severe	4 (3; 7)	752 (490; 930)	50 (40; 85) $p=0,001$	9,3 (5,1; 13,3) $p=0,001$
ANOVA df=2, (n=30)		H=15,8; $p=0,0004$	H=3,3; $p=0,19$	H=23,4; $p=0,00001$	H=23,8; $p=0,00001$

In mild epidural hematomas with mass effect (ME) up to 2% (A1), the volume of intracranial hematomas ranged from 2.3 to 9.0 cm³, and the dislocation of median structures was up to 2 mm. At admission, the majority of children (7 out of 12) were rated as moderate, with a GSC score of 10-11 points. The remaining 5 out of 12 children were admitted with a GCS score of 9 points. All of the children were admitted with general cerebral and vegetative syndromes. Focal pyramidal syndrome in the form of anisoreflexia was observed in 4 out of 12 children (Figure 3). When technical monitoring of the course of the traumatic process and the volume of intracranial hematoma was possible, a conservative treatment was used.

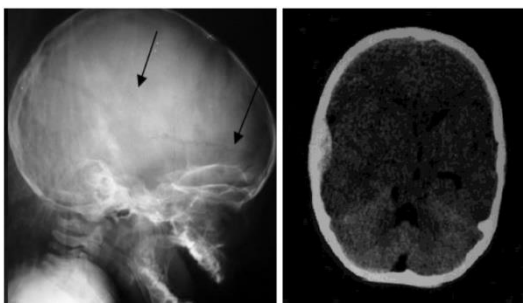


Figure 3: (L) MRI craniogram of a 6-month-old patient with an epidural hematoma (the arrow indicates a linear fracture of the parietal bone). (R) the result of a CT scan. ME<2%.

In hematomas with moderate ME from 2 to 4% (A2), the volume of intracranial hematomas was from 6.9 - 21.8 cm³, the dislocation of the

median structures of the brain from 0 - 4 mm. In newborns, the clinical picture remained poor, there were no focal syndromes, the appearance of focal pyramidal and dislocation syndromes in 4 out of 7 children. A high plasticity of the craniocerebral system in the group of children less than one year is indicated by the absence of dislocation syndrome and the additional volume in the cranial cavity, created by epidural-subperiosteal hematomas (EPH) with CHVI up to 4%. The possibility of increased volume in the cranial cavity is caused by stretching the cranial sutures and dura mater, thereby creating “additional reserve spaces”. 1 out of 7 children received a score of 12 points, 4 out of 7 children received scores of 10 - 11 points, and 2 out of 7 children received scores of 9 points. Patients in this group had their hematomas removed through trephination. In hematomas with severe ME of more than 4% (A3), the volume of intracranial hematomas was from 25.0 - 120.0 cm³, the dislocation of the median structures of the brain was from 1 - 11 mm (Table 2).

Upon admission to the hospital, out of 11 children, four infants were rated as moderate with a GCS score of 10 - 11 points, five of them were with a score of 8 points and two infants were with a score of 7 points. In 10 out of 11 children, of all age groups, in severe condition (GCS 7 - 10), manifested a number of focal syndromes, including focal craniobasal and dislocation syndromes. Newborns during the first months of life were distinguished by a manifestations of hydrocephalus syndrome and underwent decompression operations.

As seen in (Table 3), conservative treatment and minimally invasive methods of treatment were carried out in children with mostly mild and

moderate mass effect. As the mass effect of the hematomas increased, the number of trephinations and decompressive craniectomies increased.

Table 3: Types of treatment for patients with EPH depending on the value of CHVI.

Type of surgical intervention	Groups with EDH			Total
	Group A1 CHVI < 2%	Group A2 CHVI 2-4%	Group A3 CHVI > 4%	
Trephination	0	3	2	5
Decompressive craniectomy	0	1	4	5
CPT	0	1	0	1
Conservative treatment	10	1	1	12
Total	n=10	n=6	n=7	n=23

III Features of the Clinical Course of Subdural Hematomas (SDH) in Young Children

Group B (n=43) - children with subdural hematomas, depending on the value of CHVI, was represented as subgroups B1 (n=9), B2 (n=10), and B3 (n=24) (Table 4). In subdural hematomas with CHVI up to 2%, the volume of hematomas ranged from 5.0 - 35.0 cm³, the dislocation of the median brain structures was 0 - 3 mm. In the analysis of clinical manifestations, the following patterns were revealed: 6 out of 9 children

with subdural hematomas with CHVI up to 2%, (B1), at admission they were evaluated using the GCS, scoring from 13 to 15 points. All 9 children had cerebral syndromes, vegetative and pyramidal (7 out of 9 children), focal craniobasal (4 out of 9 children), and dislocation (3 out of 9 children), while focal syndromes were not complete and were presented only in children older than 6 months. In subdural hematomas with a CHVI of 2 - 4%, the volume of hematomas was from 15.0 - 40.0 cm³, the dislocation of the median structures was from 0 - 7 mm.

Table 4: Mass effect of subdural hematomas.

Group, (Amount)	CHVI	M-echo, mm	Cranial volume, cm ³	EPH volume, cm ³	ME %
B1 (n=9)	Mild	0 (0; 2,5)	920 (630; 1059)	11 (10; 15) p=0,004	1,4 (1,1; 1,6) p=0,0002
B2 (n=10)	Moderate	2 (0; 3,5)	1015 (800; 1063)	20 (20; 30)	2,5 (2,0; 2,7)
B3 (n=24)	Severe	3 (2; 7,5)	725 (405; 1057,5)	50 (31; 65) p=0,006	6,5 (6,1; 7,0) p=0,0004
ANOVA df=2, (n=43)		H=7,6; p=0,02	H=0,9; p=0,6	H=17,3; p=0,0002	H=23,1; p=0,00001

There were no neonatal children in this group. 7 out of the 10 children of group B2 at admission had increasing degradation of consciousness from sopor to coma and had a GCS score less than 10 points. All 10 of the children expressed cerebral, vegetative, and hypertension syndromes. As a secondary set of syndromes, 8 out of 10 children had focal pyramidal syndromes, and 5 out of the 10 had craniobasal syndromes.

to 3 years old. The presence of a light interval was more often observed in newborns and children in the first year of life with a duration of 1 to 8 days, which reflected the high compensatory capabilities of children of this age group.

Subdural hematomas with a CHVI greater than 4%, differed in volumes from 17.0 - 150.0 cm³, the dislocation of the median structures of the brain ranged from 0 - 20 mm, and there was variability in the clinical picture. A high degree of compensation was revealed, in children of a young age, to the increasing volume of SDH. Out of the 24 patients, 12 were admitted to the hospital in a compensated state. The loss of consciousness was established in one-third of the children, with most 1

With the increase in CHVI of subdural hematomas, the prevalence of cerebral and vegetative syndromes remained in all 24 children. While the prevalence of focal syndromes such as the focal pyramidal syndrome was present in 19 out of 24 children, and focal craniobasal syndrome was present in 14 out of 24 children. Along with focal hematomas with an increased CHVI, dislocation was present in 22 out of 24 children, hypertension in 17 out of 24 children, and hydrocephalic syndromes in 15 out of 24 children, the latter specifically in children under one. This made it possible to perform minimally invasive operations (Figure 4). The performed operational interventions are presented in (Table 5).

Table 5: Comparative characteristics of types of treatment of patients with subdural hematomas depending on the CHVI.

Type of treatment	Groups with SDH			Total
	Group B1 CHVI < 2%	Group B2 CHVI 2-4%	Group B3 CHVI > 4%	
Type of surgical intervention	n=6	n=6	n=20	n=32
PEED	2	4	13	19
Decompressive craniectomy	2	2	4	8
Puncture of hematoma	0	0	8	8
Conservative treatment	2	0	0	2
Total	6	6	25	37

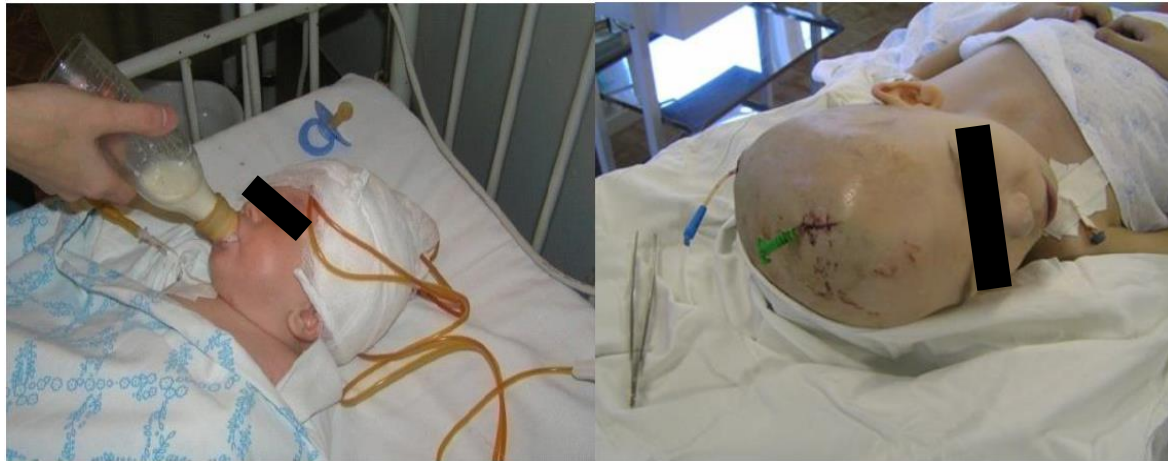

Figure 4: Minimally invasive interventions in children. Long-term external endocapsular drainage of hematomas.

IV Features of the Clinical Course of Multiple Hematomas in Young Children

Children with multiple hematomas were represented as Group C. The group was further divided into subgroups based on the CHVI of the hematomas, C1 (n=0), C2 (n=5), and C3 (n=33). No young children were identified with a CHVI of less than 2%. The severe condition of children with multiple hematomas reflected the severity of primary brain damage (multiple contusion foci, depressions), and fractures of the bones of the base of the skull.

Multiple hematomas with CHVI from 2 - 4% (C2) were characterized by a total volume of 15.0 - 30.0 cm³, and dislocations from 0 - 2 mm.

Children of subgroup C2, with a GCS score of less than 8 points, were characterized by their severe condition and deprivation of consciousness, ranging from being stunned to in a coma. All patients at the time of admission had a detailed clinical picture of brain injury with expressed focal syndromes, the severity of which depended on the value of the total CHVI, their localization, and mutual location. The absence of brain dislocation did not exclude the presence of multiple intracranial hematomas in young children. The group of children with multiple hematomas with a CHVI greater than 4% (C3) was characterized by a volume of hematomas ranging from 20.0 - 120.0 cm³, and an extremely severe TBI (Figure 5).

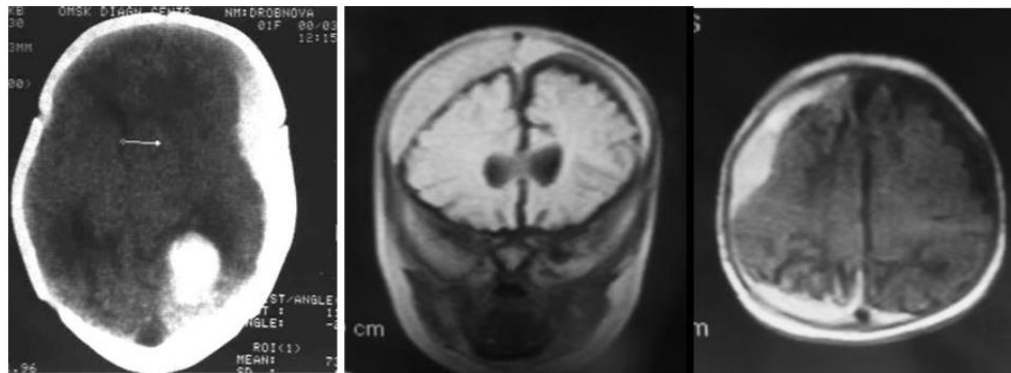


Figure 5: (L) CT of Group C patient, 18 days with multiple hematomas; (C) Coronal MRI of multiple hematomas; (R) Axial MRI of multiple hematomas. ME>4%.

Loss of consciousness was established in 17 out of 38 children, and a "light" interval in 11 of 38 children (all in children under one year). Most of the children (75%) at admission had a depraved consciousness, with some in a deep coma, and scored 4 - 5 points on the GCS (Table 6). The clinical picture of multiple hematomas with a severe mass effect, was characterized by the identical severity of cerebral, hypertensive, and focal pyramidal syndromes in all 33 children. Focal craniobasal syndrome was observed in 29 out of 38 children, dislocation syndrome in 22 out of 38 children, which was a common characteristic of bilateral localization of multiple hematomas, and hydrocephalus syndrome in 7 out of 38 children, all being under the age of one. These patients mainly underwent decompressive operations (Table 7).

Based on personal clinical studies and experience in the differentiated treatment of 71 children with traumatic ICH (Group IIIA), we determined the tactics and the scope of surgical treatment of traumatic ICH in young children, depending on the type of hematomas, the CHVI. Young children with membranous ICH, in compensated states, and CHVI with ME less than 2% received a conservative treatment, and the condition of the hematoma was monitored daily using neurosonography (NSG). 14 out of 71 children (20%) had good results. Therefore, the objective criteria for hematomas of "small" volume for young children was a CHVI less than 2%. In the presence of subgrondation of the calvaria, along with hematomas with a CHVI up to 2%, surgical

intervention was limited to repositioning the fractured bones and the simultaneous drainage or removal of the hematoma. With depressed penetrating fractures, neurosurgical treatment of the fracture was performed, and the hematoma removed. In the surgical treatment of

young children with traumatic ICH, the main task was to achieve radical removal of ICH while maintaining the minimally invasive nature of the intervention.

Table 6: Mass effect of multiple hematomas.

Group, (Amount)	CHVI	Dislocation M-echo, mm	Cranial volume, cm ³	Hematoma volume, cm ³	ME %
C1 (n=0)	Mild				
C2 (n=5)	Moderate	1 (0 – 1,5)	760 (640;890)	23 (18; 25)	2,95 (2,3; 3,28)
C3 (n=33)	Severe	3 (0; 5)	856 (570; 1060)	60 (48; 87) p=0,002	7,2 (6,3; 10,3) p=0,0003

Table 7: Comparative characteristics of the types of treatments for patients with multiple hematomas depending on the ME.

Type of treatment	Groups with multiple hematomas		Total
	Group C2 CHVI 2-4% n=3	Group C3 CHVI > 4% n=13	
Type of surgical intervention			n=16
Trephination	1	1	2
PEED	2	14	16
Decompressive craniectomy	0	3	3
Puncture of hematoma	0	4	4
Conservative treatment	0	0	0
Total	3	22	25

In traumatic ICH with a CHVI of 2 - 4%, preference was given to minimally invasive methods of ICH removal (puncture, trephination, PEED) (Figure 6). To remove subdural hematomas in young children, a method of long-term external endocapsular drainage was used. In children with subdural hematomas with ME greater than 4%, the preference remained for minimally invasive methods of removal such as PEED. In children who had ICH with a CHVI 2% and higher, who

developed dislocation syndrome and penetrating depressed fractures, preference was given to resection decompressive trepanation of the skull, taking into account individual skull sizes. Of the 82 operations performed, 54 (66%) were minimally invasive, and 15 (34%) were decompressive craniectomies. The diversity of ICH with the predominance of SDH and multiple hematomas caused the frequency of bilateral surgeries and multiple surgeries.

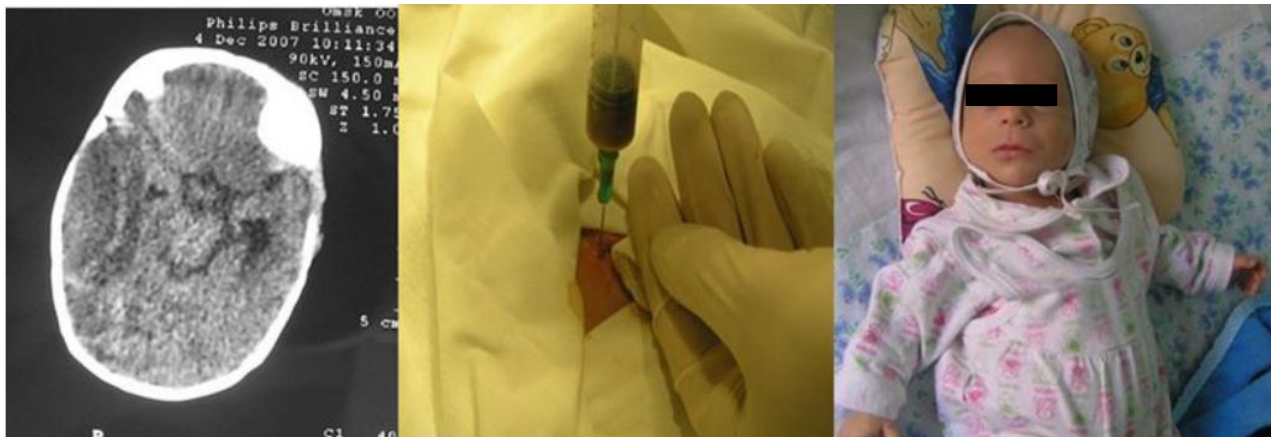

Figure 6: (L) MSCT of patient, 21 days with epidural hematoma; (C) hematoma puncture; (R) patient's appearance post-surgery.

Discussion

The result of treatment was carried out using the adaptation of the Lansky scale and the Glasgow outcome scale (GOS). The data obtained showed that in Group I, conservative treatment prevailed in 20% of children (14 out of 71), and surgical interventions in 76% (54 out of 71

operations) were minimally invasive; in Group II, 53% (p<0.05). Decompression surgeries were performed twice less frequently in Group I (10%) than in Group II (23%) (p<0.05). Repeated surgeries in Group II (37%) were associated with an illogical choice of the primary method of surgical intervention.

The results of the condition of children in the study groups assessed on the Lansky scale, in dynamics, showed that there were no significant differences in the condition of patients at admission; however, on the seventh and subsequent days, the degree of adaptation of children in Group I was significantly higher, by 19-30 points (2 times), than in children in Group II, which confirms the clinical effectiveness of the method, ($p < 0.05$).

Acknowledgement

The authors would like to thank the hospital administration represented by A.L. Sukharev, the Head of the Children's Clinical Hospital №3. As well as the staff of the Children's Clinical Hospital №3, and the staff of Children's Intensive Care Unit for their help in caring children. We would also like to show our gratitude to L.A. Sitko, M.D. Professor of Pediatric Surgery Department; V.K. Fedotov, M.D (posthumously); S.I. Lyamzin, Ph.D. (Medicine), the deputy chief doctor, and S.K. Kudrenko, Ph.D. (Medicine), the former deputy chief doctor; V.V. Mishkin, Ph.D. (Medicine), the Head of Neurosurgery Department; V.A. Bahta, Ph.D. (Medicine), neurosurgeon; R.P. Koval; A.S. Preobrazhensk; A.A. Martynenko; E.A. Petrusha; M.S. Kuznetsov, neurosurgeons; M.M., Katina, Ph.D. (Medicine), neurologist; A.V. Zyuzko, Ph.D. (Medicine), radiologist.

REFERENCES

1. Garg K, Sharma R, Gupta D, Sinha S, Satyarthee GD et al. (2017) Outcome Predictors in Pediatric Head Trauma: A Study of Clinicoradiological Factors. *J Pediatr Neurosci* 12: 149-153. [[Crossref](#)]
2. Wani AA, Sarmast AH, Ahangar M, Malik NK, Chhibber SS et al. (2017) Pediatric Head Injury: A Study of 403 Cases in a Tertiary Care Hospital in a Developing Country. *J Pediatr Neurosci* 12: 332-337. [[Crossref](#)]
3. Adirim TA, Wright JL, Lee E, Lomax TA, Chamberlain JM (1999) Injury surveillance in a pediatric emergency department. *Am J Emerg Med* 17: 499-503. [[Crossref](#)]
4. Astrand R, Undén J, Hesselgard K, Reinstrup P, Romner B (2010) Clinical factors associated with intracranial complications after pediatric traumatic head injury: An observational study of children submitted to a neurosurgical referral unit. *Pediatr Neurosurg* 46: 101-109. [[Crossref](#)]
5. Larkin VI, Larkin DV (2009) Craniocerebral disproportion in children. Omsk: Publishing house, OmSTU 256.
6. Raimondi AJ, Hirschauer J (1984) Head injury in the infant and toddler. Coma scoring and outcome scale. *Childs Brain* 11: 12-35. [[Crossref](#)]
7. Suresh HS, Praharaj SS, Indira Devi B, Shukla D, Sastry Kolluri VR (2003) Prognosis in children with head injury: An analysis of 340 patients. *Neurol India* 51: 168. [[Crossref](#)]